



Original Article

Clinical Course and Outcome of 12 Breast TB Cases

R Debi¹, B C Sarker², S Chowdhury³, Khan MMR⁴, P M Basak⁵, Tapash Ranjan Das⁶

Abstract

Breast TB is a very rare form of extrapulmonary TB. So, case reviews are also less common. 12 breast TB cases diagnosed and treated between June 2011- June 2014 in the private chamber were retrospectively reviewed. All cases were female, their mean age was 34.4 years. All were new cases and only one had pulmonary TB. Patients presented with hard, irregular breast lump (83.3%), swelling of the breast (25%), secretion from the involved breast (33.3%), breast pain (50%). Montaux test was negative in 83.3% patients and chest x-ray findings was positive only in one case. ESR was raised and FNAC showed granulomatous changes in all cases. All received Directly Observed Treatment Short Course regimen for a duration of 6 months. Segmental resection was not done. Small lump persisted in only 2 cases after treatment. From the above findings it can be said that breast TB should be considered as a differential diagnosis of breast neoplasia and it can be successfully treated by anti-TB drugs.

Key Words : TB- Tuberculosis FNAC-Fine needle aspiration cytology.

TAJ 2013; 26: 24-26

Introduction

Breast TB was first defined by Sir Astley Cooper in 1829 as a rare form of extra pulmonary TB.¹ Breast TB is a very rare disease and constitutes only 0.025-1.04% of breast diseases^{2,3}. It is more frequently encountered in developing countries in Africa and Asia.^{4,5} Presentation of breast TB is variable and may be confused with other disorders.^{6,7} FNAC is the most extensively used initial invasive method for diagnosis of breast TB.^{8,9} and the gold standard diagnostic tool for breast TB is often misdiagnosed as a pyogenic abscess or carcinoma of breast, both clinically as well as radiologically especially if well-defined clinical features are absent.¹⁰

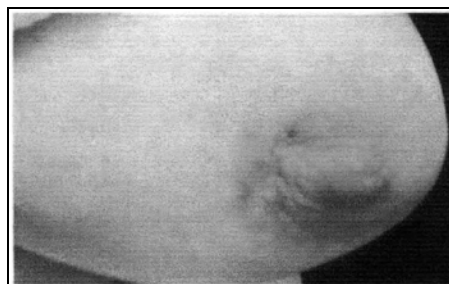

Figure- 2 : A large tender mass was felt in the inner half of the left breast, and a sinus tract was present near the nipple.

¹ Junior Consultant, Rajshahi medical college hospital, Bangladesh.

² Assistant Professor, Medicine, Rajshahi medical college, Bangladesh.

³ Associate Professor, Gynae, Rajshahi medical college, Bangladesh.

⁴ Associate Professor, Medicine, Rajshahi medical college, Bangladesh.

⁵ Assistant Professor, Medicine, Rajshahi medical college, Bangladesh.

⁶ Assistant Professor, Community Medicine, Sheikh Sayera Khatun medical college, Gopalganj.

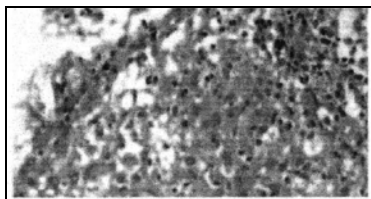


Figure- 3: Tissue biopsy demonstrating the formation of epithelioid granulomas with Langerhans giant cells and lymphohistocytic aggregates.

Table -1

Treatment time	Initial phase regimen	Continuation phase regimen
6 months	Isoniazid, rifampicin, pyrazinamide, ethambutol or streptomycin for 2 months	Isoniazid and rifampicin for 4 months
9 months	Isoniazid, rifampicin, pyrazinamide, ethambutol or streptomycin for 2 months	Isoniazid and rifampicin for 7 months

Results

All 12 cases were female, their mean age was 34.4 years. All were housewives, all were new cases and all were married and of reproductive age, none were pregnant at the time of diagnosis. Their postero-anterior lung radiographs were assessed as normal and had non respiratory symptoms. One had history of contact with TB patient.

Table- 2

Criteria	Number	Percentage
Education		
Illiterate	2	16.6%
Up to primary	3	25%
Secondary and above	7	58.3%
Involved part of the breast		
Left	10	83.3%
Right	2	16.7%
Bilateral	none	0%
Signs in the breast		
Hard irregular lump	10	83.3%
Swelling of the breast	3	25%
Secretion from the involved breast	4	33.3%
Breast pain	6	50%
Ipsilateral axillary lymph node involvement	4	33.3%
Investigations		

In the present study, we aimed to evaluate demographic data, diagnostic methods, therapeutic regimens and duration of therapy in 12 breast TB patients treated with DOTs regimen.

Methods: 12 patients were diagnosed with breast TB and the directly observed therapy (DOT) regimen was put into practice. Demographic, the patients own history, physical examination findings were recorded. Blood parameters, chest x-ray, sonography and FNAC was done.

Raised ESR	12	100%
Positive MT test	2	16.7%
Positive chest X-Ray	0	0%
Granulomatous change in FNAC	12	100%
Breast TB rates diagnosed		
2011	1	8.3%
2012	2	16.7%
2013	5	41.7%
2014	4	33.3%

Patients presented with swelling of the breast 25%, lump 83.3%, excretion from the involved breast 33.3%, pain 50%, ipsilateral axillary lymph node involvement in 33.3%, in left side 83.3%, all were from rural areas

TB diagnostic criteria for this study was based on biopsy and clinical response. Histopathological finding of the specimen included epithelioid cell granulomas with or without caseous necrosis. All completed DOTs therapy for 6 months with a full recovery and only a small lump persisted in 2 cases.

Discussion: Incidence of breast TB accounts for less than 0.1% of all breast lesions in western countries and 4% of all breast lesions in TB endemic countries¹¹. Although tuberculosis is a very common disease in endemic areas, isolated involvement of the breast is very rare⁹. TB of the breast is classified as primary and secondary;

primary when no other foci of TB are detectable. In our study, none had previous history of pulmonary TB. Differential diagnosis such as sarcoidosis, fungal infections, duct ectasia and coexisting malignancy should be ruled out¹³. Khan et al¹⁴ diagnosed 52 breast TB cases by FNAC and histopathological methods with a rate of 100%. We also diagnosed all patients histologically.

In breast TB the presenting signs and symptoms tend to be breast masses were the most frequent examination finding¹⁴ Like our study, previous study showed one third of breast TB patients have ipsilateral axillary lymph node involvement.^{13, 15}

In one study 16 out of 22 patients had left side involvement which supports our study. Therapeutic guidelines remark that anti-TB therapy given for 6 months is sufficient.^{15 17} In a different study¹⁸, the standard 6 month therapy was sufficient for all patients to recover. In our study group, all the patients had full recovery with persistent small mass in only 2 cases with DOTs regimen for 6 month.

Limitations: Due to retrospective nature we failed to investigate known risk factors for breast TB including multiparity, lactation, trauma, history of suppurative mastitis etc. Acknowledgements: We thank all of the patients who allowed us to use their medical records in this study.

References

- Cooper A. Part I. London, Longman, Rees, Orme: Brown and Green; 1829. Illustration of the Diseases of the Breast; p. 7.
- Sharma PK, Babel AL, Yadav SS. Tuberculosis of the breast (study of 7 cases) J Postgrad Med. 1991; 37:24-6. [PubMed]
- Bani-Hani KE, Yaghan RJ, Matalaka II, Mazahreh TS. Tuberculosis mastitis: a disease not to be forgotten. Int J Tuberc Lung Dis. 2005; 9:920-5. [PubMed]
- Gdksoy E, Duren M, Durgun V, Uygun N. Tuberculosis of the breast. Eur J Surg. 1995; 161:471-3. [PubMed]
- Al-Marri MR, Almosleh A, Almoslmani Y. Primary tuberculosis of the breast in Qatar: ten year experience and review of the literature. Eur J Surg. 2000; 166:687-90. [PubMed]
- Mehta G, Mittal A, Verma S: Breast tuberculosis-clinical spectrum and management.
- Indian J Surg* 2010, 72(6):433-437. PubMed Abstract | Publisher Full Text | PubMed Central Full Text
- Baharoon S: Tuberculosis of the breast.
- Ann Thorac Med* 2008, 3(3):110-114. PubMed Abstract | Publisher Full Text |
- PubMed. Central Full Text
- Martinez-Parra D, Nevado-Santos M, Melendez-Guerrero B, Garcia-Solano J, Hierro-Guilmain CC, Perez-Guillermo M: Utility of fine-needle aspiration in the diagnosis of granulomatous lesions of the breast.
- Diagn Cytopathol* 1997, 17(2):108-114. PubMed Abstract | Publisher Full Text
- Madhusudhan KS, Gamanagatti S: Primary breast tuberculosis masquerading as carcinoma.
- SingapMedJ* 2008, 49(1):e3-e5.
- Wani I, Lone AM, Malik R, Warn KA, Warn RA, Hussain I, Thakur N, Snabel V: Secondary tuberculosis of breast: case report.
- ISRN Surgery* 2011, 2011:529368. PubMed Abstract | PubMed Central Full Text
- Bhosale AA JA, Ashturkar AV, Pathak GS: Primary tuberculosis of breast: a case series.
- Ann Trop Med Public Health* 2012, 5(3):262-264. Publisher Full Text
- Mckeown KC, Wilkinson KW. Tuberculous diseases of breast. Br J Surg. 1952; 39:420. [PubMed]
- Baharoon S. Tuberculosis of the breast. Ann Thorac Med. 2008; 3:110-4. [PMC free article] [PubMed]
- Khanna R, Prasanna GV, Gupta P, Kumar M, Khanna S, Khanna AK. Mammary tuberculosis: report on 52 cases. Postgrad Med J. 2002;78:422-M [PMC free article] [PubMed]
- Jalali U, Rasul S, Khan A, Baig N, Khan A, Akhter R. Tuberculous mastitis. J Coll Physicians SurgPak. 2005; 15:234-7. [PubMed]
- Behnaz Khodabakhshi and Fatemeh Mehravar: Breast tuberculosis in Northeast Iran: review of 22 cases: BMC women's health 2014, 14-72.
- Elmrabet F, Ferhati D, Amenssag L, Kharbach A, Chaoui A. Breast tuberculosis. Med Trop (Mars) 2002; 62:77-80. [PubMed]
- Da Silva BB, Lopes-Costa PV, Pires CG, Pereira-Filho ID, Dos Santos AR. Tuberculosis of the breast: analysis of 20 cases and a literature review. Trans R Soc Trop Med Hyg. 2009; 103:559-63. [PubMed]

All correspondence to
Rakhi Debi
Junior Consultant
Rajshahi medical College Hospital
Bangladesh.