



## Original Article

# Histomorphological Study of Different Ovarian Lesions in a Tertiary Care Hospital

Anindita Sarkar,<sup>1</sup> S. M. Asafudullah,<sup>2</sup> Khadiza Khanam,<sup>3</sup> Arefa Sultana,<sup>4</sup> Nazifa Islam,<sup>5</sup> Samrose Sultana,<sup>6</sup> Sunandita Sarkar<sup>7</sup>

### Abstract

**Objective:** The present study is to ascertain the relative frequency, histologic types, and age distribution of both neoplastic and non-neoplastic ovarian lesions in the Rajshahi medical college hospitals and compare the results with similar studies in other regions of this country and abroad.

**Methods & Materials:** This cross-sectional study was conducted in the Department of Pathology, Rajshahi Medical College, over one year from January 2021 to December 2021. A total of 144 cases of ovarian lesions were included in this study. Inflammatory conditions and developmental anomalies were excluded.

**Result:** Out of 144 cases of ovarian masses studied, 104 (72%) were neoplastic. The common types were Surface epithelial tumors (70%), germ cell tumors (23%), and sex-cord stromal tumors (7%). The age range of ovarian tumors was 5 to 70 yrs, and the highest incidence was between 21-50 yrs. Most of the ovarian tumors were bilateral (85%).

**Conclusion:** Varying types of both non-neoplastic and neoplastic ovarian lesions were seen. Benign tumors were more common than malignant tumors in all age groups. Surface epithelial cell tumors, followed by germ cell tumors, were the most common tumor. Serous cystadenoma was the most common tumor. Tumour types varied in different age groups.

**Keywords:** Histopathology, Neoplastic, Non-neoplastic, Ovarian lesion.

TAJ 2023; 36: No-1: 17-22

### Introduction

Ovaries are a common site for both neoplastic and non-neoplastic lesions. They have extensive heterogeneity within and between histologic subtypes, and the spectrum ranges from harmless, simple cysts to aggressive malignant ones. Globally, ovaries are the third most common site of primary malignancy in the female genital tract after the cervix and endometrium. They are also the second most frequent cause of death from gynecological cancers after cervical cancer.

Ovarian tumors generally escape detection until they attain a large size.<sup>1</sup>

Ovarian tumors are common forms of neoplasia in women. Ovarian tumors account for about 30.0% of female genital cancers. Asian countries have a rate of 2- 6 new cases per 1,00,000 women per year. Ovarian carcinoma is the fourth most common female cancer and the fourth leading cause of death among cancer deaths in females.<sup>2</sup>

Ovarian lesions have diverse histopathologies reflecting the different cell origins of the lesions.<sup>3</sup>

<sup>1</sup> Assistant Professor (C.C), Department of Pathology, Rajshahi Medical College, Rajshahi, Bangladesh.

<sup>2</sup> Professor and Head, Department of Pathology, Rajshahi Medical College, Rajshahi, Bangladesh.

<sup>3</sup> Professor, Department of Pathology, Rajshahi Medical College, Rajshahi, Bangladesh.

<sup>4</sup> Associate Professor, Department of Pathology, Rajshahi Medical College, Rajshahi, Bangladesh.

<sup>5</sup> Assistant Professor (C.C), Department of Pathology, Rajshahi Medical College, Rajshahi, Bangladesh.

<sup>6</sup> Assistant Professor (C.C), Department of Pathology, Pabna Medical College, Pabna, Bangladesh.

<sup>7</sup> Registrar, Department of Gynaecology & Obstetrics, Rajshahi Medical College Hospital, Rajshahi, Bangladesh.

Approximately 80-90% of all pathological ovarian masses are benign and mostly occur in young women between 20 and 45 years, whereas borderline and malignant tumors are common in postmenopausal women. Ovarian tumors are divided into three major categories: epithelial, germ cell, and sex cord-stromal tumors, and mostly, physiological cysts are follicular and luteal cysts. The studies showed a large variation and diversity in prevalence, types of ovarian masses, and histological patterns of them.<sup>4</sup>

According to World Health Organization's histological classification, ovarian tumors are subdivided into five main categories according to the tissue of origin: surface-epithelial stromal tumors, sex-cord stromal tumors, germ cell tumors, malignant and not otherwise specified, and metastatic non-ovarian tumors from non-ovarian primary.<sup>5</sup>

Neoplastic disorders can arise from (1) Mullerian epithelium, (2) germ cells, or (3) sex-cord stromal cells. Ovarian neoplasms are usually detected at a late stage and are large because of their presentation with mild symptoms. An accurate and early diagnosis of malignant lesions will go a long way in the optimal management of these cases.<sup>6</sup>

Most ovarian lesions are presented with cyst formation, which can be physiological or pathological. Pathological cysts are mainly ovarian tumors which can be benign, borderline, or

malignant. A benign ovarian cyst may occur at any age, but it is mostly seen during reproductive age and constitutes about 90% of ovarian tumors. The nature of ovarian cystic lesions is difficult to determine by clinical examination and surgical exploration. As the management and prognosis mainly depend on the histological type and the tumor grade, it is mandatory to find out the origin and the type of tumor by doing a thorough histopathological examination.<sup>7</sup>

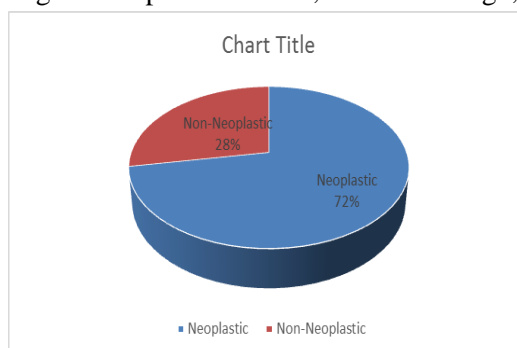
In this study, we have analyzed the histopathological types of ovarian tumors with frequency and age distribution.

### Materials and Methods

This cross-sectional study was conducted in the Department of Pathology, Rajshahi Medical College, over one year, from January 2021 to December 2021. A total of 144 cases of different ovarian lesions were included in the study. Inflammatory, gestational, and developmental disorders were excluded. Tumors were classified using the WHO classification (4th edition).<sup>8</sup> A purposive method of sampling was employed. The specimen of tissue was fixed with 10% formalin and stained with hematoxylin, and an eosin stain was examined. Histopathological diagnosis was correlated with the age of the patient and ovary involvement (unilateral or bilateral). Statistical analysis was performed using Microsoft Excel.

### Results

A total of 144 samples of ovarian lesions were received for histopathological evaluation at our Hospital, a tertiary care hospital in Rajshahi, Bangladesh. Of these, 104 cases (72%) were diagnosed as a neoplastic lesion, and the rests were non-neoplastic (Figure-1), 123 cases were unilateral (86%), and 21 cases were bilateral (14%) (Figure -III). Among the neoplastic lesions, 74 were benign, 2 cases were borderline, and 28 were malignant (Figure II).

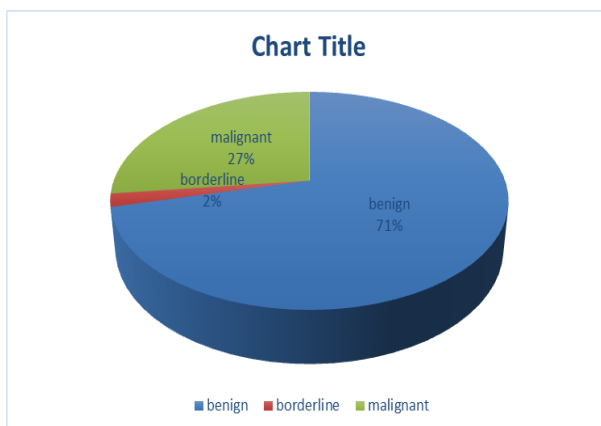
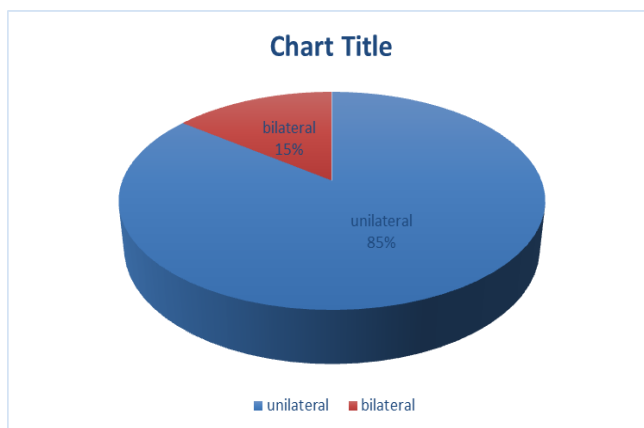


**Figure I: Frequency of ovarian lesions based on histological diagnosis (n=144)**

**Table I: Distribution of Non-Neoplastic Lesions (n = 40)**

Histological diagnosis	No of cases	Percentage (%)
Haemorrhagic Cyst	18	45
Luteal Cyst	10	25
Follicular Cyst	06	15
Simple Cyst	04	10
Endometriosis	02	05
Total	40	100

Among the 40 cases, the highest number was diagnosed as benign hemorrhagic cysts (18 cases, 45 %), followed by corpus luteal cysts (10 cases, 25%). The number of follicular and simple cysts was 6 cases (15%) and 4 cases (10%), respectively. Only 2 cases (5%) were diagnosed as endometriosis.

**Figure II: Frequency of ovarian tumor based on histological diagnosis (n=104)****Figure III: Frequency of ovarian lesions based on laterality (n=104)**

**Table II: Frequency of Ovarian neoplasm (n = 104)**

<b>Nature of tumors</b>	<b>Number of cases</b>	<b>Percentage (%)</b>
<b>I. Epithelial stromal tumors</b>		
<b>A. Serous tumors</b>		
1. Serous cystadenoma	34	32.69
1. Serous cystadenofibroma	03	2.88
3. Borderline serous tumor	02	1.92
4. Serous cystadenocarcinoma	17	16.34
<b>B. Mucinous tumors</b>		
1. Mucinous cystadenoma	14	13.46
3. Mucinous cystadenocarcinoma	01	0.96
<b>C. Brenner Tumours</b>		
1. Benign Brenner tumor	01	0.96
<b>II. Germ cell tumors</b>		
1. Mature cystic teratoma	16	15.38
2. Immature teratoma	01	0.96
3. Dysgerminoma	03	2.88
4. Endodermal Sinus tumor	03	2.88
5. Mixed Germ Cell tumor	01	0.96
<b>III. Sex cord-stromal tumors</b>		
1. Granulosa cell tumour	02	1.92
2. Fibroma	05	4.81
<b>IV. Metastatic Tumour</b>	01	0.96
<b>Total</b>	104	100

Among the 104 neoplastic ovarian lesions, 74 (71%) cases were benign, 2 cases (2%) were borderline, and 28 cases (27%) were malignant [Figure-2]. Among 74 benign ovarian neoplasms, the most commonly seen lesion was serous cystadenoma, followed by benign cystic teratoma and mucinous cystadenoma. Out of 28 malignant cases, a maximum of 17 cases were of serous cystadenocarcinoma, followed by 8 cases of germ cell tumors.

**Table III: Frequency of Ovarian neoplasm in different age groups (n = 104)**

Histopathological Variant	< 20 yrs	21 - 50 yrs	>50 yrs	Total
Surface epithelial tumors				
Benign	11		05	
Borderline	00	36	02	52
Malignant	01	00	03	02
		14		18
Germ cell tumors				
Benign				
Malignant	08	07	01	16
	03	03	02	08
Sex cord-stromal tumors				
Benign				
Malignant	02	02	01	05
	00	02	00	02
Metastatic tumor	00	01	00	01
Total	25	65	14	104

The age-wise distribution of the patients whose samples were received is given in Table 3. Patients aged 21-50 years constituted the majority of patients (65 out of 104; 62.5%).

### Discussion

Among the 144 cases studied, 104 (72%) were neoplastic, and 40 (28%) were non-neoplastic. The incidences of non-neoplastic lesions were higher in some Indian studies, i.e., 51.7% and 87.3% in studies conducted by Kanthikar et al.<sup>9</sup> and Pudasaini et al.<sup>5</sup>, respectively. Our finding is, however, consistent with the observation in a similar study by Shrestha et al.<sup>1</sup> in Nepal with 25.2% and some other studies of India,<sup>2</sup> i.e., 25% of non-neoplastic cases. (Figure I)

In this study, 74 cases (71%) were benign, 28 cases (27%) were malignant, and 2 cases (2%) were borderline tumors. This is almost similar to the data from studies conducted in India by Pilli et al.,<sup>10</sup> Gupta et al.<sup>11</sup>, and Swamy et al.<sup>2</sup> which showed approximately similar results of benign ovarian tumors at 75.2%, 72.9%, and 71.6%, respectively. However, this figure was only 59.2% in Ahmad et al.<sup>12</sup> study in Pakistan. (Figure-II)

Hemorrhagic cysts (45%) were the most typical non-neoplastic ovarian lesions in the present study. This observation contrasts with the studies of S Maharjan in which corpus luteum cysts were common, constituting 70%<sup>3</sup>. Okugawa et al.<sup>13</sup> observed endometriosis (71.52%) as the most common non-neoplastic ovarian lesion. (Table I)

Among histopathological patterns, the commonest category of the ovarian tumors encountered in our series was epithelial tumors, followed by germ cell tumors. The most common benign tumor was serous cystadenoma, followed by mature cystic teratoma. Serous tumors were found to be more common than mucinous; similar results were reported by Swamy et al.<sup>2</sup> (Table II)

In our study, the commonest type of ovarian tumor according to WHO classification was surface epithelial tumors (69.2%), which was comparable to Pudasaini et al.<sup>5</sup> Among the surface epithelial tumors, serous cyst adenoma was the commonest

one (65%), followed by mucinous cyst adenoma (26.9%). Our study's second most common tumor was a germ cell tumor (23.07%). Several other studies showed that the germ cell tumor was the most common one.<sup>1</sup> (Table II)

Serous cystadenocarcinoma was the most common type of malignant neoplasm. It was also found as the most common malignant neoplasm in studies conducted in India, Pakistan, and Saudi Arabia. However, in Nepal, mucinous cystadenocarcinoma was the most common malignant tumor.<sup>14</sup> (Table II)

Similar to the present study, another study showed that the ovarian tumor had a wide range of age distributions. In our study, the youngest patient was 5 yrs, and the oldest was 70 yrs, which was in concordance with Danish et al.<sup>15</sup> The age range in other studies done in Iran was 11-85 years.<sup>4</sup>

In our study, 85% of tumors were unilateral, and 15% were bilateral. The incidence of unilaterality in the S.S. et al. study (89.5%) was high than in our study.<sup>4</sup> Our study showed the peak incidence of ovarian tumors in the age group 21 to 50 years which was comparable with a study done by Ahmed et al., where the peak incidence of ovarian tumors was between 21 to 50 years.<sup>14</sup> (Table III)

## Conclusion

Ovarian tumor is a common type of gynecological neoplasm, accounting for 15-25% of all gynecological malignancies. Benign ovarian neoplasms were more common than malignant ones, and the benign serous tumor was the most common type of benign neoplasm. In contrast, serous cyst adenocarcinoma was the commonest type of malignant neoplasm. Our study's pattern and age distribution of ovarian tumors were quite similar to other studies, with some variation.

**Conflict of interest:** None declared.

## References

1. Shrestha O, Baral R, Shrestha S. Histomorphological Spectrum of Ovarian Masses in a Tertiary Centre of Eastern Nepal. *Nepal Journal of Obstetrics and Gynaecology*. 2021 Jun 7;16(1).
2. Swamy GG, Satyanarayana N. Clinicopathological analysis of ovarian tumors—A study on five years samples. *Nepal Med Coll J*. 2010 Dec 1;12(4):221-3.
3. Maharjan S. Clinicomorphological study of ovarian lesions. *Journal of Chitwan Medical College*. 2013;3(4):17-24.
4. Shadab S, Tadayon T. Histopathological diagnosis of ovarian mass. *Journal of Pathology of Nepal*. 2018 Apr 3;8(1):1261-4.
5. Pudasaini S, Lakhey M, Hirachand S, Akhter J, Thapa B. A study of ovarian cyst in a tertiary hospital of Kathmandu valley. *Nepal med coll j*. 2011 Mar 1;13(1):39-41.
6. Prakash A, Chinthakindi S, Duraiswami R, Indira V. Histopathological study of ovarian lesions in a tertiary care center in Hyderabad, India: a retrospective five-year study. *Int J Adv Med*. 2017 May;4(3):745.
7. Pradhan SB, Chalise S, Pradhan B, Maharjan S. A study of ovarian tumors at Kathmandu medical college teaching hospital. *Journal of Pathology of Nepal*. 2017 Sep 1;7(2):1188-91.
8. Rosai J. Female reproductive system-Ovary. In Rosai J, ed. *Rosai and Ackermann's Surgical Pathology*. Edinburgh: Mosby Elsevier, 2004:1553-1635.
9. Kanthikar SN, Dravid NV, Deore PN, Nikumbh DB, Suryawanshi KH. Clinico-Histopathological Analysis of Neoplastic and Non-Neoplastic Lesions of the Ovary: A 3-Year Prospective Study in Dhule, North Maharashtra, India. *J Clin Diagn Res JCDR*. 2014;8(8):FC04-7.
10. Pilli GS, Suneeta KP, Dhaded AV, Yenni VV. Ovarian tumors: a study of 282 cases. *J Indian Med Assoc*. 2002;100(7):420, 423-4, 447.
11. Gupta N, Bisht D, Agarwal AK, Sharma VK. Retrospective and prospective study of ovarian tumors and tumour-like lesions. *Indian J Pathol Microbiol* 2007;50:525-7
12. Ahmad Z, Kayani N, Hasan SH, Muzaffar S, Gill MS. Determination of Histological Pattern of Ovarian Neoplasm. *JPMA*. 2000; 50(12): 416-419.
13. Okugawa K, Hirakawa T, Fukushima K, Kamura T, Amada S, Nakano H. Relation between age, histological type and size of ovarian tumors. *Int J Gynecol Obstet*. 2001;74(1):45-50.
14. Ahmed M, Afroze N, Sabiha M. Morphological Pattern of Ovarian Tumour: Experience in a Tertiary Level Hospital. *Journal of Bangladesh College of Physicians and Surgeons*. 2018 Jan 29;36(1):5-10.
15. Danish F, Khanzada MS, Mirza T, Aziz S, Naz E, Khan MN. Histomorphological Spectrum of Ovarian Tumors with Immunohistochemical Analysis of Poorly or Undifferentiated Malignancies. *GJMS*. 2012;10:209-15.

All correspondence to  
**Dr. Anindita Sarkar**  
 Assistant Professor (C.C)  
 Department of Pathology  
 Rajshahi Medical College  
 Email: abantica.16@gmail.com