



Original Article

Role of Fiberoptic Bronchoscopy in the Diagnosis of Pulmonary Disease: Experience in a Tertiary Care Hospital

Md. Rezaul Islam,¹ Ahmad Zainuddin Sani,² Samir C. Majumdar³

Abstract

Introduction: Fiberoptic bronchoscopy is a very important tool in the modern era in the field of pulmonary medicine in arriving to a definite diagnosis. Since the introduction of the first flexible fiberoptic bronchoscope (FOB) has been a valuable tool in the diagnosis of pulmonary diseases.

Material & methods: This study was conducted in Rajshahi Medical College Hospital (RMCH), Rajshahi. It was undertaken to study the role of fiberoptic bronchoscopy (FOB) in diagnosis of pulmonary disease. The study period was between 1st June 2017 to 30th June 2019. A total number of 300 patients (48 females and 252 males) who underwent elective fiberoptic bronchoscopy were included in this study. Data was collected from hospital record regarding age, clinical presentation, diagnostic procedure and outcome.

Results: A total number of 300 patients had fiberoptic bronchoscopy during the study period. 252(84.00%) patients were male and 48(16.00%) were female. As per age distribution 8(2.67%) were of age group 20-32 years and majority 111(37.00%) of patients were in age group 60-72 years. Min age group was 20 and max 85 and the mean±SD age was (58.70±13.11). Occupation of the study participants most of them are farmer 134(44.67%). Bronchoscopy findings: most of the patients had malignant lesion 228(76.00) and a few had foreign body 6(2.00%), mean±SD (2.03±0.68). Majority of the patients had problems in their upper lobe 167(55.67%) and some of the patients had problems in lower lobe 22(7.33%), mean±SD (0.97±0.15). Regarding location, left principal bronchus were involved in 115(38.33%), upper lobe 95(31.67%), lower lobe 36(12.00%) and lingular lobe 36(12.00%), mean±SD (2.01±1.02). Trachea was found normal 261(87.00%) and growth 29(13.00%), mean±SD (1.13±0.33). Vocal cord found normal 246(82.00%) and palsy was found in 54(18.00%), mean±SD (1.18±0.38). Carina findings were normal 54(18.00%), blunt 230(76.67%) and sharp 13(4.33%), mean±SD (1.26±0.50).

Conclusion: FOB can be successfully employed for the diagnosis of lung diseases, including malignancies and granulomatous lesions. Routine bronchoscopy technique continues to have a good diagnostic yield in current clinical practice in various lung diseases.

Key Words: FOB (Fiberoptic Bronchoscopy), Pulmonary disease, Diagnosis.

TAJ 2020; 33: No-2: 46-55

Introduction

Fiberoptic bronchoscopy (FOB) is a very useful and safe procedure for diagnosis of various

respiratory diseases. The advent of flexible role of fiberoptic bronchoscopy in 1965 revolutionized the field of pulmonary medicine and proved itself

¹ Assistant Professor, Department of Respiratory Medicine, Rajshahi Medical College, Rajshahi.

² Assistant Professor, Department of Respiratory Medicine, Rajshahi Medical College, Rajshahi.

³ Professor, Department of Respiratory Medicine, Barind Medical College, Rajshahi.

as a safe and useful technique for diagnostic and therapeutic purposes. The fiberoptic bronchoscopy (FOB), has greatly enhanced the diagnosis and understanding of lung diseases and has evolved into the procedure of choice for diagnosis in pulmonary diseases.¹ In the last decade an increasing number of immunocompromised patients have come to medical attention because of pulmonary infiltrates of various etiologies. Solid organ transplant recipients form an important and an increasingly growing subgroup of immunocompromised patients.

Transplant patients may present at any time interval after the transplant with infections caused by bacteria, viruses, parasites or fungi. It is a worldwide accepted procedure both for the diagnosis and treatment of various pulmonary disorders. FOB can be performed under local anesthesia in various clinic/hospital settings providing maximal visualization of tracheobronchial tree², and if performed carefully, can be a thoroughly safe procedure.³ By fiberoptic bronchoscopy we not only can visualize the tracheobronchial tree but also take various samples and can remove foreign body. Some of the common indications of bronchoscopy are undiagnosed radiographic abnormalities, to confirm tuberculosis/malignancy, to locate the origin of hemoptysis and to check it, to assess the microbial cause of pneumonia and to remove foreign body.⁴ Some notified complications of bronchoscopy are cardiac arrhythmia, pneumothorax, bronchospasm and hypoxemia particularly in a patient of poor pulmonary reserve.⁵ The patients with hemodynamic instability are particularly more prone to complications.⁶ Bronchoscope has replaced the rigid bronchoscope in the diagnosis and management of inflammatory, infectious and malignant disease of the chest and also helps in the diagnosis and therapeutic approach of respiratory diseases.⁷ For early diagnosis different diagnostic modalities are available such as brushing, washing and fine needle aspiration.⁸ The diagnostic sensitivity of bronchial brushing was 50% according to a study and the diagnostic sensitivity of bronchial biopsy in cases of visible cancers was

84.2% in the same study.⁹ Another study has shown that at least five biopsies are needed to maximize the chance of obtaining a histological evidence of cancer.¹⁰ The role of conventional methods of diagnosing pneumonia in the immunocompromised host are limited. The serological methods for the diagnosis of viral pneumonias such as caused by CMV have low sensitivity and specificity in the immunocompromised host because of decreased antibody production, due to immunosuppression.¹¹ In order to evaluate the role of FOB for pulmonary infiltrates in solid organ recipients, the types and timing of the various infections after transplant should be considered. Pulmonary infections in organ transplant patients are mostly caused by bacterial pathogens. The finding of pulmonary infiltrates on chest x-ray films may be otherwise explained by pulmonary congestion, embolism or alveolar hemorrhage. It is most important to recognize pulmonary infections as they carry a great risk for morbidity and mortality in these patients. Therefore, the aim of this study is to assess the role of fiberoptic bronchoscopy (FOB) in diagnosis of pulmonary disease: experience in a tertiary care hospital.

Materials and methods

This study was conducted in Rajshahi Medical College Hospital (RMCH), Rajshahi. It was conducted between 1st June 2017 to 30th June 2019. A total number of 300 patients (48 females and 252 males) who underwent elective fiberoptic bronchoscopy were included. Patients with unresolved and undiagnosed opacity on chest radiography along with persistent symptoms were picked up for fiberoptic bronchoscopy. Data was collected from hospital record regarding age, clinical presentation, diagnostic procedure and outcome.

• Inclusion Criteria

- Patients with unresolved and undiagnosed opacity on chest radiography along with persistent symptoms were taken up for fiberoptic bronchoscopy.

- Removal of foreign body and respiratory secretions, brushing and biopsy, for arriving in diagnosis of neoplasm, undiagnosed infections, and other noninfectious causes.

- **Exclusion Criteria**

- Age min 20 and max 85.

Uncooperative patients, physically and mentally unfit, and patients not giving consent for the procedure.

Results

A total number of 300 patients had fiberoptic bronchoscopy during the study period. (Table I) Majority 252(84.00%) were male and 48(16.00%) were female. (Table II) As per age distribution 8(2.67%) were of age group 20-32 years and majority 111(37.00%) of patients were in age group 60-72 years. Min age group was 20 and max 85 and the mean±SD age was (58.70±13.11). (Table III) Occupation of the study participants most of them are farmer 134(44.67%). (Table IV) shows the CXR findings of the study participants there were two side right and left. In right the variables were collapse 68(42.23%), mass lesion 40 (24.58%), hilar shadow 17(10.55%), patchy opacity 12(7.45%) and fibrosis and bronchiectasis 24(14.90%), while in left the variables were collapse 48(35.53%), mass lesion 22 (15.82%), hilar shadow 25(17.99%), patchy opacity 14(10.07%) and fibrosis and bronchiectasis 30(21.28%), mean±SD (1.53±0.68). (Table V) shows the smoking status of the study participants majority 182(66.67%) were smoker and 118(39.33%) were non-smoker,

mean±SD(0.47±1.67), for smoker pack per year <10 pack 78(42.85%), 10-20 pack 66(36.26%) and >20 pack 38(20.87%), mean±SD(1.22±1.06). (Table VI) shows the most common symptom of bronchoscopy was cough in 294 patients (98.00%), the mean±SD(0.97±0.15), followed by sputum production 88(29.33%) were not productive and 212(70.67%) were productive, mean±SD(1.10±0.30), SOB were 144(48.00%) and 156(52.00%), mean±SD(1.47±0.50) wheezing were 111(37.00%) and 189(63.00%), mean±SD(1.63±0.49), chest pain were 127(43.00%), mean±SD(1.57±0.49), and 171(57.00%) and there was some others as well 22(7.33%), Mean±SD(0.07±0.26). (Table VII) Bronchoscopy findings: nature of lesion most of the patients had malignant lesion 228(76.00) and less of the patients had foreign body 6(2.00%), mean±SD (2.03±0.68). In location right majority of the patients had problems in their upper lobe 167(55.67%) and less of the patients had problems in lower lobe 22(7.33%), mean±SD (0.97±0.15). In location left principal bronchus were 115(38.33%), upper lobe 95(31.67%), lower lobe 36(12.00%) and lingular lobe were 36(12.00%), mean±SD (2.01±1.02). Trachea was found normal 261(87.00%) and growth 29(13.00%), mean±SD (1.13±0.33). Vocal cord found normal 246(82.00%) and palsy was 54(18.00%), mean±SD (1.18±0.38). carina findings were normal 54(18.00%), blunt 230(76.67%) and sharp 13(4.33%), mean±SD (1.26±0.50). (Table VIII) shows the histological type of the patient's majority of the patients were in squamous cell 95(31.66%), mean±SD (2.48±1.37).

Table I: Age distribution of the study participants. (n=300)

Variables	n	%	Mean±SD
20-32	8	2.67	
33-45	40	13.33	
46-59	64	21.33	58.70±13.11
60-72	111	37.00	
73-85	77	26.67	
Total	300	100	

Table II: Sex distribution of the study participants. (n=300)

Variables	n	%
Female	48	16.00%
Male	252	84.00%
Total	300	100

Figure I: Figure Shows the Sex Distribution of the study participants. (n=300)

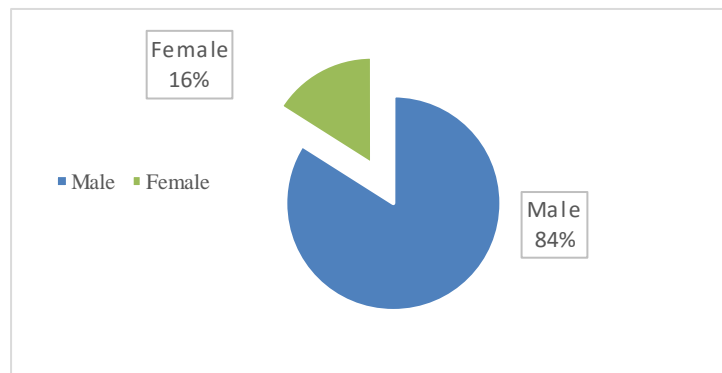


Table III: Occupation of the study participants. (n=300)

Variables	n	%
Farmer	134	44.67
House Wife	50	16.67
Retired	15	5.00
Businessman	26	8.67
Teacher	13	4.33
Ex-teacher	08	2.67
Government service	33	11.00
Ex- Government service holder	08	2.67
Advocate	04	1.33
Fisher Man	09	3.00
Total	300	100

Table IV: CXR findings of the study participants. (n=300)

Variables	Right (n=161)		Mean±SD
	n	%	
Collapse	68	42.23	1.53±0.68
Mass lesion	40	24.58	
Hilar Shadow	17	10.55	
Patchy Opacity	12	7.45	
Fibrosis and bronchiectasis	24	14.90	
Total	161	100	
	Left (n=139)		
Collapse	48	35.53	
Mass lesion	22	15.82	
Hilar Shadow	25	17.99	
Patchy Opacity	14	10.07	
Fibrosis and bronchiectasis	30	21.28	
Total	139	100	

Table V: Smoking Status of the study participants. (n=300)

Variables	n	%	Mean±SD
Non-smoker	118	39.33	0.47±1.67
Smoker	182	66.67	
	Pack Per Year (n=182)		
<10	78	42.85	1.22±1.06
10-20	66	36.26	
>20	38	20.87	
Total	182	100	

Table VI: Symptom of the study participants. (n=300)

Variables	Cough		Mean±SD
	n	%	
Yes	294	98.00	
No	06	2.00	
Total	300	100	0.97±0.15
	Sputum Production		
Non-productive	88	29.33	
Productive	212	70.67	1.10±0.30
Total	300	100	
	Hemoptysis		
Yes	183	61.00	
No	117	39.00	1.39±0.48
Total	300	100	
	SOB		
Yes	144	48.00	
No	156	52.00	1.47±0.50
Total	300	100	
	Wheezing		
Yes	111	37.00	
No	189	63.00	1.63±0.48
Total	300	100	
	Chest Pain		
Yes	127	43.00	
No	171	57.00	1.57±0.49
Total	300	100	
	Others		
others	22	7.33	0.07±0.26

Table VII: Bronchoscopy findings of the study participants. (n=300)

Nature of lesion (n=300)			
Variables	n	%	Mean±SD
Inflammatory	43	14.33	
Malignant lesion	228	76.00	
Foreign body	6	2.00	2.03±0.68
Others	23	7.67	
Total	300	100	
Location Right (n=300)			
Principal Bronchus	66	22.00	
Upper lobe	167	55.67	
Middle lobe	45	15.00	1.95±0.98
Lower lobe	22	7.33	
Total	300	100	
Location Left (n=300)			
Principal Bronchus	115	38.33	
Upper lobe	95	31.67	
Lower lobe	54	18.00	2.01±1.02
Lingular lobe	36	12.00	
Total	300	100	
Trachea (n=300)			
Normal	261	87.00	
Growth	39	13.00	1.13±0.33
Total	300	100	
Vocal Cord (n=300)			
Normal	246	82.00	
Palsy	54	18.00	1.18±0.38
Total	300	100	
Carina (n=300)			
Normal	54	18.00	
Blunt	230	76.67	
Sharp	13	4.33	1.26±0.50
Total	300	100	

Table VIII: Histological type of the study participants. (n=300)

Variables	n	%	Mean±SD
Adenocarcinoma	50	16.66	
Squamous cell	95	31.66	
Large cell	43	14.33	2.48±1.37
Small cell carcinoma	25	8.33	
Others	87	29.00	
Total	300	100	

Discussion

Of the total patients who had undergone bronchoscopy, majority 252(84.00%) were male and 48(16.00%) were female. The age group of maximum patients was above 80 years and mean age was 58.70 years. Bronchogenic carcinoma was found to have association with increasing age of the patients. In our study, diagnosis of pulmonary disease was commonest indication to perform bronchoscopy keeping in mind suspected malignancy in the patients which is correlated with the studies conducted by Garg B et al¹² and Jindal et al¹³. Endobronchial lesions are frequently encountered during FOB. Clinical profile of individual including name, age, sex, smoking history, symptoms, and location, friability of lesion tells about the likely possibility of diagnosis. But diagnosis is generally confirmed by histopathological examination. In this study, male preponderance in for diagnostic bronchoscopy was likely due to heterogeneous population of armed forces and also because of the fact that risk factors associated with respirational diseases like smoking, tobacco chewing are more common in males. Most of patients (37.00%) were of older than 60 years of age with people older than 72 years (42%) constituted largest group. This is likely because of the fact that most common diagnosis made after bronchoscopy was carcinoma lung and most of cases underwent FOB were suspected of malignancy and chances of carcinoma lung increases with age. Smoking was a risk factor in 66.67% of cases who underwent

FOB and 39.33% were nonsmokers. Smoking is associated with greater than 90% of carcinoma lung cases and also common risk factors for various lung diseases like airway diseases causing symptoms like cough, breathlessness, and dyspnea, which are the most common indications for FOB.^{14,15} In our study we found that 294(98%) patients had cough and only 2% didn't. Most common symptom of patient was cough which is similar to previous published studies.¹⁶ Chest pain and breathlessness on exertion were also common complaints of patients. In this study 127(43.00%) patients had chest pain. Right lung was involved in 52% of cases and upper lobe was involved in 50% of cases. Similar reports have appeared in literature.^{17,18,19,20} in this study we found that the study participants in both two sides. In right the variables were collapse 68(42.23%), mass lesion 40 (24.58%), hilar shadow 17(10.55%), patchy opacity 12(7.45%) and fibrosis and bronchiectasis 24(14.90%) Left lung was involved in 46% of cases, and bilateral lesions were present in 2% of cases. Right and left main bronchus was involved in 38% of cases followed by 6% each in middle and lower lobes. Most common finding detected during FOB was exophytic growth, which was detected in 46% of patients. Similar reports are available in literature.^{21,22} In this study, the left variables were collapse 48(35.53%), mass lesion 22 (15.82%), hilar shadow 25(17.99%), patchy opacity 14(10.07%) and fibrosis and bronchiectasis 30(21.28%). Whereas, Shrestha et al.²³ found squamous cell carcinoma (60.9%) was the most common histological pattern of bronchial

carcinoma, followed by small cell carcinoma (19.5%) and adenocarcinoma (8.0%). Tuladhar et al.²⁴ found the various bronchogenic malignancies in decreasing order of frequency were squamous cell carcinoma (51%), followed by small cell carcinoma (19%), adenocarcinoma (11%), non-small cell carcinoma (7%), large cell carcinoma (4%), carcinoma in situ (4%) and small round cell carcinoma (4%). Our study was mainly limited to diagnostic bronchoscopy due to lack of facility for therapeutic bronchoscopy that was the main limitation of our study. Our study findings correlated with most of the other studies done elsewhere, some differences may be due to small sample size in present study.

Conclusion

FOB can be successfully employed for the diagnosis of lung diseases, including malignancies and granulomatous lesions. Routine bronchoscopy technique continues to have a good diagnostic yield in current clinical practice in various lung diseases. Bronchoscopy is increasingly being utilized in diagnosis of a wide array of respiratory disorders. It is fairly safe and can be performed as an outpatient procedure. Our study suggests that, the fiberoptic bronchoscopy in the diagnosis of pulmonary disease and its techniques in the hands of experienced respiratory interventionists will improve the diagnostic outcomes of those patients with the least morbidity and mortality, employing better therapeutic strategies, and thus improving the overall management of those patients.

References

1. Foos L, Patuto N, Chhajer PN, Tamm M. Diagnostic yield of flexible bronchoscopy in current clinical practice. *Swiss Med Wkly*. 2006 Apr 3; 136(9-10):155-9. [2].
2. Suratt PM, Smiddy JF, Gruber B. Deaths and complications associated with fiberoptic bronchoscopy. *Chest*. 1976 Jun 1; 69(6):747-51.
3. Willcox PA, Benatar SR, Potgieter PD, Ferguson AD, Bateman ED. Fibre-optic bronchoscopy. Experience at Groote Schuur Hospital. *S Afr Med J*. 1981; 60(17):651-4.
4. Amir Suleman, Qazi Ikramullah, Farooq Ahmed, M Yousaf Khan. Indications and complications of bronchoscopy: an experience of 100 cases in a tertiary care hospital, *JPMI* 2008; 22:210-214.
5. Pachter R, Pue CA. Complications of fiberoptic bronchoscope at a University Hospital. *Chest*. 1995; 107: 430-2.
6. Kozak E, Brath L. Do screening coagulation tests predict bleeding in patients undergoing fiberoptic bronchoscope with biopsy. *Chest*. 1994; 106: 703-5.
7. Anthony Seaton, Douglas Seaton. *Crofton and Douglas's Respiratory diseases*; 5th ed. Pub. Blackwell Science, 2008:148-9.
8. Shagufta Tahir Mufti¹, Ghadeer A. Mokhtar. Diagnostic value of bronchial wash, bronchial brushing, fine needle aspiration cytology versus combined bronchial wash and bronchial brushing in the diagnosis of primary lung carcinomas at a tertiary care hospital. *Biomed Res*. 2015; 26(4):777-84.
9. Tuladhar A, Panth R, Joshi A R. Comparative analyses of cytohistologic techniques in diagnoses of lung lesions. *J Pathol Nepal*. 2011; 1:126-30.
10. Gellert AR, Rudd RM, Sinha GA, Geddes DM. Fiberoptic bronchoscopy: effect of multiple bronchial biopsies on diagnostic yield in bronchial carcinoma. *Thorax*. 1982; 37(9):684-7.
11. Frattini JE, Trulock EP. Respiratory infections in immunocompromised patients. *Immunol Allerg Clin N Am*. 1993; 13:193-204.
12. Garg B et al. *Indian J Chest Dis Allied Sci* 2013;55:145-148]
13. Jindal SK, Behera D, Dhand R, Kashyap S, Malik SK. Flexible fiberoptic bronchoscopy in clinical practice: a review of 100 procedures. *Indian J Chest Dis Allied Sci*. 1985; 27:153-8.
14. Alberg AJ, Samet JM. Epidemiology of lung cancer *chest* 2003; 123(1Suppl):21S-49S
15. U.S. Department of Health and Human Services. The health consequences of smoking: A report of the surgeon general. CDC publication no. 7829. Washington, DC: Public Health Service, Centers for Disease Control and Prevention 2004.
16. Prakash UBS, Offord KP, Stubbs SE. Bronchoscopy in North America: The ACCP survey. *Chest*. 1991; 100:1668-75.
17. Pavlovska I, Danilovski D, Orovchanec N. An epidemiologic study of some characteristics of lung cancer. *Folia Med*. 2004; 46:23-31.
18. Atıcı AG, Erkan L, Fındık S, Uzun O, Kandemir B. Clinical features of non-small cell lung cancer cases. *Tüberk Toraks*. 2004; 52:150-8.

19. Sevgi E, Akkurt İ, Özşahin SL, Ardic S, Altinors M, Daycan B et al. A retrospective analysis of 189 patients with lung cancer. Turk J Med Sci. 17:191-9.
20. Alamoudi OS. Lung cancer at a University Hospital in Saudi Arabia: A four-year prospective study of clinical, pathological, radiological, bronchoscopic, and biochemical parameters. Ann Thorac Med. 2010; 5:30-6.
21. Devkota KC, Pathak R, Khanaland A, Chokhani R. Fiber-optic bronchoscopy: Seven-year experience at Nepal Medical College Teaching Hospital. Nepal Med Coll J. 2010; 12:260-3.
22. Sahin F, Yildiz P. Radiological, Bronchoscopic and Histopathologic Characteristics of Patients with Primary Lung Cancer in Turkey (2006-2009). Asian Pac J Cancer Prev. 2011;12(8):1947-52.
23. Shrestha HG, Chokhani R, Dhakhwa R. Clinicopathological profile of Bronchogenic carcinoma. J Nepal Med Assoc. 2010; 49 (178): 100-3.

All correspondence to
Dr. Md. Rezaul Islam
Assistant Professor
Department of Respiratory Medicine
Rajshahi Medical College, Rajshahi
E-mail: rezaul1976@gmail.com