



## Case Report

# Hiatus Hernia in Paediatric Age Group, A Rare Finding- Two Case Reports

Nasrin Begum<sup>1</sup>, Md. Kabiruzzaman Shah<sup>2</sup>, Md. Nowshad Ali<sup>3</sup>

### Abstract

Hiatus hernia is a herniation of abdominal viscera into the thoracic cavity through the oesophageal hiatus. It is an acquired condition means it develops spontaneously with age even without predisposing factors or it develops after some trauma to body leading to injury at gastro-oesophageal junction.

Hiatus hernia is a rare condition in the pediatric age group, which may be asymptomatic or it may present with a variety of symptoms or complications.

We are reporting two case of hiatus hernia in paediatric age group, which were diagnosed using ultrasonography. Both patients had symptom related with the GIT disease.

TAJ 2010; 23(1): 75-79

### Introduction

Hiatus hernia is a herniation of abdominal viscera into the thoracic cavity through the oesophageal hiatus.<sup>1</sup> It is an acquired condition means it develops spontaneously with age even without predisposing factors or it develops after some trauma to body leading to injury at gastro-oesophageal junction.<sup>6</sup>

Hiatus hernia is a rare condition in the paediatric age group, which may be asymptomatic or it may present with a variety of symptoms or complications.<sup>2</sup>

We report two case of hiatus hernia in 8 yrs and 6 yrs old boy which were diagnosed using ultrasonography. Both patients had symptom related with the GIT disease.

### Case one

A 8 yrs old baby present with complaints of upper abdominal pain and hyperacidity. There was no

history of fever, cough, chest pain, haemoptysis or weight loss.

Chest radiography shows a soft tissue lesion in lower part of the lung field. Then patient was sending for USG of chest to detect the lesion.

UGS showed no pleural effusion. Heart is placed in the left side. A complex soft tissue lesion seen in left side, predominantly the lesion is echogenic in peripheral aspect and small fluid portion seen centrally containing echogenic debris. Then patient was examined in upright position and asked to drink water; dynamic USG image was captured which showed water within the left chest lesion. Trans-diaphragmatic oesophageal diameter is about 28 mm. *All features were suggesting hiatus hernia.*

The boy under went a non-contrast enhanced computed tomography of chest and upper

<sup>1</sup> Medical Officer, Centre for Nuclear Medicine & Ultrasound, Rajshahi.

<sup>2</sup> Assistant Professor, Centre for Nuclear Medicine & Ultrasound, Rajshahi.

<sup>3</sup> Assistant Professor, Department of Paed Surgery, Rajshahi Medical College, Rajshahi.

abdomen which confirmed the diagnosis. Then he treated by proton pump inhibitor and H<sub>2</sub> receptor antagonist; other symptomatic treatment was given.

At present, the patient is asymptomatic for hiatus hernia with no symptom of epigastric pain, heart burn, nausea and vomiting.

### Case two

A 6 yrs old boy presented with upper abdominal pain as well as chest pain in left side. He was undergoing chest X-ray showed a soft tissue lesion in left side of the chest. Then patient was sending for USG to see the character of the lesion. USG showed no pleural effusion or any consolidation or mass. Heart is placed in left side. There was a complex lesion seen in left side, fluid part noted centrally. During USG examination patient was advised to sit and USG done in supine as well as upright position then advised to drink water. Water was seen within the lesion and turbulence noted during the procedure. Trans-diaphragmatic diameter was 20 mm, *all features were suggesting hiatus hernia*. Then patient was undergone for a Ba-swallow study and CT scan.

The gastroesophageal junction is not depicted. The case was diagnosed as hiatus hernia. Endoscopy of upper GIT confirmed the diagnosis. Medical treatment was given to the patient and presently the boy is asymptomatic.

### Discussion

Although congenital and post traumatic diaphragmatic hernia was described as far back as the 16<sup>th</sup> century, hiatus hernia was not recognized as a significant clinical entity until the first half of the 20<sup>th</sup> century. The advent of Radiography was the 1<sup>st</sup> important step in the diagnosis and management for hiatus hernia.<sup>1</sup>

Akerlund et al,<sup>3</sup> proposed the term hiatus hernia in 1926. The incidence of hiatus hernia increases significantly with age and it occurs in 10% of adult popular.<sup>4</sup>

Children with this condition usually have it from birth (congenital). Some cases may have an autosomal dominant inheritance.<sup>5</sup>

A hernia may occur through a congenitally large esophageal hiatus; however, acquired hernias through the esophageal hiatus are common. approximately 99% of the hiatal hernias are sliding and the remaining 01 % are Para-esophageal.<sup>6</sup>

There are four types of hiatus hernia.

Type-1- There is upward displacement of gastroesophageal junction into the chest cavity.

Type II- The gastro-oesophageal junction remains at or below the level of diaphragm and the gastric fundus herniated.

Type III- Combination of Type- I & II.

Type IV- When hernial contents involve other abdominal structures like transverse colon, meso-colon or spleen.<sup>7</sup>

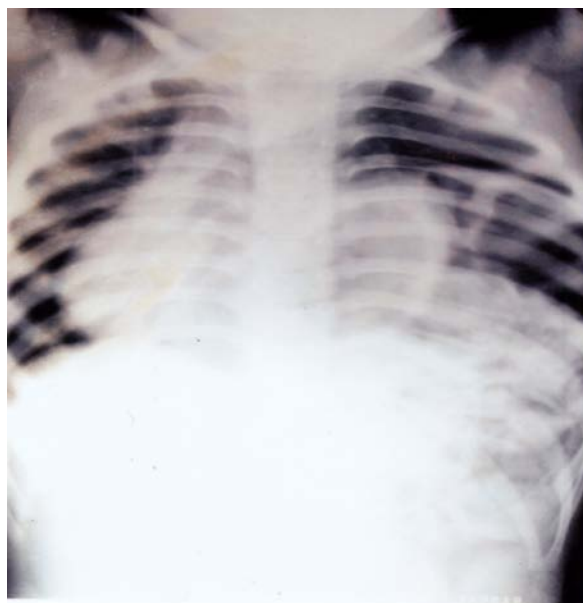


Fig I - A lesion in left chest ( Case- 1).

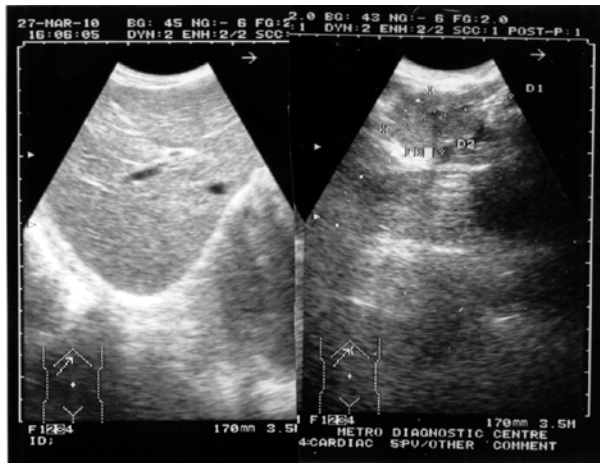The phrenicoesophageal membrane normally surrounds the lower esophagus and fixes it to the diaphragm, thereby preventing gastric herniation through the esophageal hiatus into the thorax. When the phrenicoesophageal membrane is deficient, an axial gastric herniation may developed in the thoracic cavity.<sup>10</sup>

Hiatus hernia may be asymptomatic and discovered incidentally on routine radiography or

CT scan's performed for untreated symptoms. When symptomatic patient present with epigastric pain, heart burn, nausea, vomiting and regurgitation.<sup>8</sup> Barium swallow study, upper GIT endoscopy and CT are routinely used to confirm the diagnosis of hiatus hernia.<sup>9</sup>

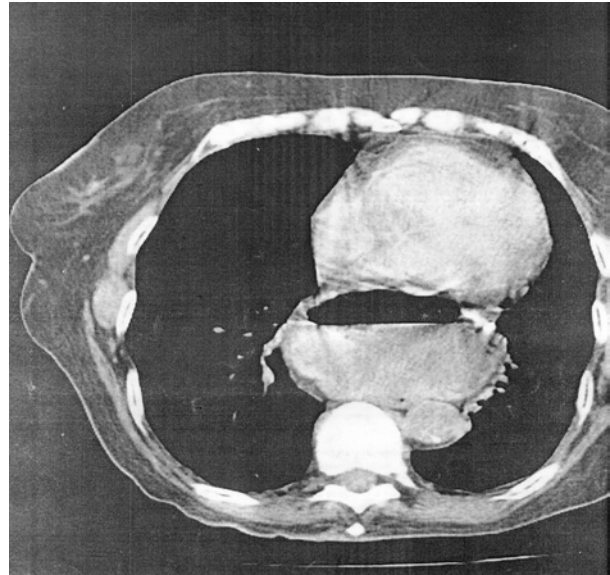
The hernia may be seen as a retrocardiac mass with or without an air-fluid level. The hernia is usually positioned to the left of the spine; however large hernia may extend beyond the cardiac confines and even mimic cardiomegaly.<sup>14</sup>

In our cases one patient gave the H/O epigastric pain and heart burn but others had no related symptom. Chest X-ray was done as a routine examination; illustrated suspicious lesion in left chest. USG of the chest were performed which revealed hiatus hernia. Endoscopy and CT scan were done to confirm the diagnosis.



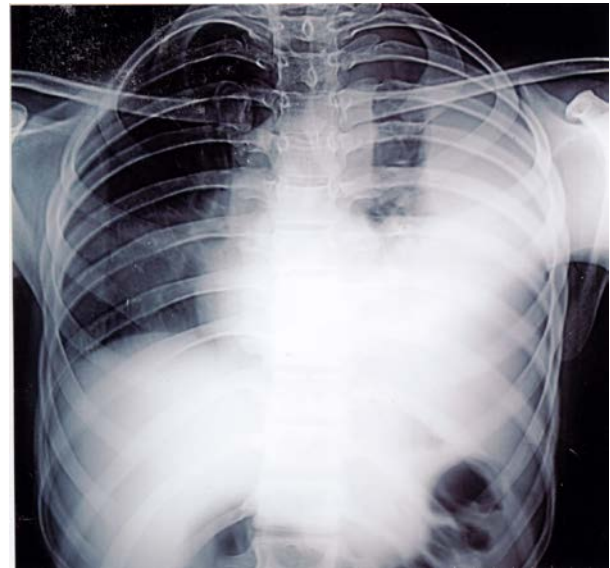
**Fig II** - A soft tissue lesion in left chest ( Fluid seen in the during water ingestion- herniation of part of the stomach).

Individuals without hiatus hernia the gastro-oesophageal junction can almost always be depicted on ultrasonography with a cross sectional diameter of 7- 10 mm at the diaphragmatic hiatus level. The gastro-oesophageal junction is not depicted in a hiatus hernia and the bowel diameter measured at the diaphragmatic hiatus is 16- 21 mm. Each of the aforementioned signs has a predictive value of 100%.<sup>10</sup>



**Fig- III** - CT scan : Hiatus hernia

Sign of the sliding hernia in infants and young children include the following; Intra-abdominal esophagus measuring less than 2 cm, rounding of the gastro-oesophageal angle and the presence of a beak at gastro-esophageal junction.<sup>12</sup>

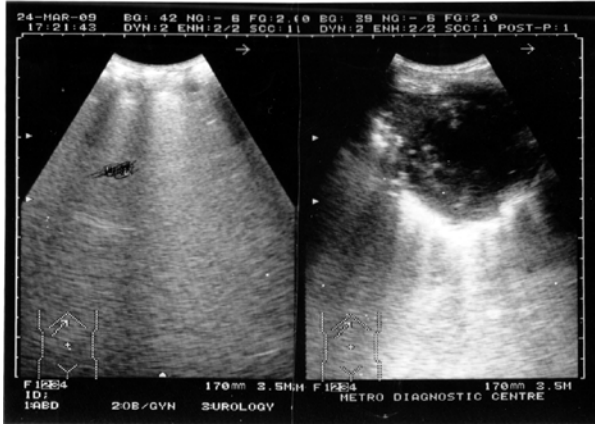


**Fig IV** : A lesion in left chest ( Case -2).

Ultrasonography is a non-invasive technique that may be useful in diagnosis of a hiatus hernia and oesophageal reflux. The use of ultrasonography is an attractive option in infants and young children in whom the images can help in differentiating esophageal causes of vomiting from duodenal

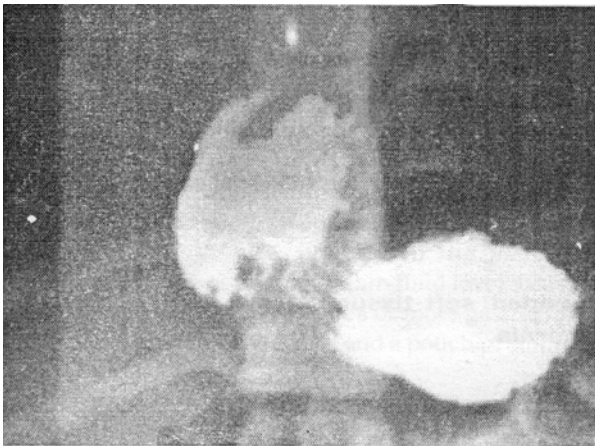cause. The predictive value of the criteria used in the evaluation of a sliding hiatus hernia in infants and young children is quite good.<sup>10</sup>

USG of the abdomen is an accurate and rapid screening method that can be used to differentiate the cause of persistent vomiting in infants.<sup>13</sup>



**Fig- V** - Lesion is filled with fluid and food particles (Part of stomach).

On sonogram fluid refluxing into the lumen of esophagus is as an anechoic column. With slight reflux the column is small, transient and easily missed in more severe reflux the column of fluid is long and may persists for sometime. Fluid often contains small echogenic air bubbles causes by turbulent flow.<sup>10</sup>



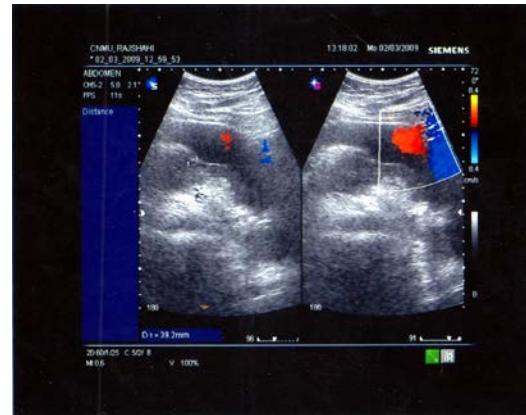
**Fig- VI** - Ba- meal study of the same patient (Sliding hernia of stomach).

A test feeding is usually given followed by ultrasonography. The examination is focused on the duodenum to document or exclude pyloric

stenosis. Once pyloric stenosis has been excluded attention is paid to the gastro-esophageal junction to detect hiatus hernia.<sup>13</sup>

In these cases no evidence of pyloric stenosis but esophageal junction was not depicted. The bowel diameters measured at the diaphragmatic hiatus were 18 mm and 20 mm. Rounding of both gastro-esophageal angle were seen.

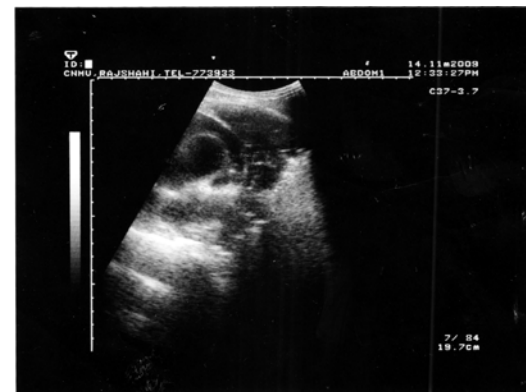One patient had anechoic esophageal column. Turbulent flow was seen in both cases during drinking.



**Fig- VII** - Colour Doppler study (No flow seen in the fluid are of the lesion).

Medical management include use of antacids, H<sub>2</sub> receptor antagonists and proton pump inhibitors (PPIs). PPIs afford the height level of symptomatic relief.<sup>11</sup>

Both the boy treated with H<sub>2</sub>- receptor antagonist and PPIs. On follow-up both the patient had no symptoms, they felt better.



**Fig - VIII** - herniated part of the stomach adjacent to apex of heart (Case -2).

## Conclusion

Giant hiatus hernia's can strangulate cause anemia or over bleeding and other symptoms such as chest pain or breathlessness after meal.<sup>12</sup>

Hiatus hernia though a common condition but not frequent in children. Incidence is increased with age. The purpose of this paper is to draw attention to the fact although rare, hiatus hernia should be considered in D/D of lung lesion/Para spinal opacity in posterior mediastinum.

## References

1. Stylopoulos N, Rattner DW. The history of hiatal hernia surgery: from Bowditch to laparoscopy. *Ann Surg* 2005; 241: 185-93.
2. Karpelowsky JS, Wieselthaler N, Rode H. Primary Para esophageal hernia in children, *J Pediatr Surg* 2006 ; 41: 1585-93.
3. Akerlund A, Onnell H, Key E. Hernia diaphragmatica hiatus oesophagei vom anastomischen und roentgenologischen gesichtspunki. *Acta Radiol* 1926; 6: 3-22.
4. Siu CW, Jim MH, HoHH, et al. Recurrent acute heart failure caused by sliding hiatus hernia *postgrad Med J* 2005; 81 : 268-9.
5. Carre IJ, Johnston BT, Thomas PS, Morrison PJ. Familial hiatal hernia in a large five generation family confirming true autosomal dominant inheritance, *Gut* 1999; 45: 649- 52
6. Kahrilas P J, Kim HC, Pandolfino JE. Approaches to the diagnosis and grading of hiatal hernia. *Best Pract Res Clin Gastroenterol.* 2008; 22 (4): 601-16.
7. [http:// www. whereincity.com/ medical/topic/ stomach- care/ articles/327 htm](http://www.whereincity.com/medical/topic/stomach-care/articles/327.htm) on 13/03/2010, PP 1,2 of 3.
8. Yazici M, Karaca I, Etensel B, Temir G, Gunsar C, Guclu C, Mutaf O. Para-esophageal hiatal hernia in children. *Dis Esophagus*, 2003; 16: 210-3.
9. Canon CL, Morgen DE, Einstein DM, et al. Surgical approach to gastro-esophageal reflux disease: What the radiologist needs to know. *Radiographics* 2005; 25: 1485- 99.
10. [http:// emedicine.medscape.com/article/369510- PP](http://emedicine.medscape.com/article/369510-PP) 18 & 19 of 39 on 20/03/2010. Ali N Khan, FRCS, FRCP, M ChandraMohon DMRD,FRCR & S MacDonald PhD. Hiatal hernia : Imaging-eMedicine Radiology. North Manchester G Hospital, NHS Trust. UK, Bradford Teaching Hospital, UK, <http://emedicine.medscape.com/update>: Oct 31, 2008.
11. Tutuian R, Casten DO. Gastro-esophageal reflux disease; natural history and long term medical and surgical out comes. *Cli Cornerstone* 2003; 5: 2-14.
12. Herek O, Yildran N. A Massive hiatal hernia that mimics a congenital diaphragmatic hernia. An unusual presentation of hiatal hernia in childhood: report of a case, *Surg Today* 2002; 32: 1072-4.
13. Halkiewicz F, Kasner J, Karczewaska K, Rusek-Zychma M. Ultrasound picture of gastroesophageal junction in children with reflux disease. *Med Sci Monit.* Jan-Feb 2000; 6(1): 96-9.
14. Qureshi W A. Hiatal Hernia. eMedicine. Available at <http://emedicine.medscape.com/article/178393-overview>.

All correspondence to:

**Nasrin Begum**

Medical Officer

Centre for Nuclear Medicine & Ultrasound, Rajshahi

Email: [drlaz24@yahoo.com](mailto:drlaz24@yahoo.com)