

## Study on Fixation Methods for Metacarpal Bone Fracture

Shaon Barua<sup>\*1</sup>, Md. Mizanur Rahaman Chowdhury<sup>2</sup>, Mamun Mustafa<sup>3</sup>, Syed Ariful Islam<sup>4</sup>,  
Rajarshi Nag<sup>5</sup>, Md Tayef Mahmud<sup>6</sup>

### Abstract

**Introduction with Objective:** The aim of the present study was to assess the fixation methods for metacarpal bone fracture. **Materials and Methods:** A prospective observational study was conducted from February 2019 to January 2020 among 29 metacarpal bone fracture patients attending at orthopedic surgery department, Chittagong Medical College Hospital, Chittagong after obtaining requisite consent from the patient. Data were collected through the assessment and X-ray report of patients in the orthopedic surgery Department. The collected data were entered into the computer and analyzed by using SPSS (version 20.1) to assess the fixation methods for metacarpal bone fracture. **Results:** Most of the study population (89.7%) was in 18-40 years of age group. The mean age of the patients was  $33.14 \pm 11.895$  years (range: 18-70 years). Service was the mostly occurring occupation among the patients (35%) and worker were 31%. In our study transverse fracture was 51.7% and oblique fracture was 41.4%. In case of method of fixation, maximum (65.5%) patient's fixations were done by mini plate, 31% were by K-wire and 3.4% were by both K-wire & lag screw. In case of number of metacarpal bone involvement, 1 bone was involved in maximum (75.9%), 2 bone were involved in 17.2% and 3 bone were involved in 6.9% patients. **Conclusion:** Closed or minimally invasive fixation with K-wire, mini plates and screws are safe methods and can be performed with minimal complications. Maximum (65.5%) patient's fixations were done by mini plate.

**Key words:** Fixation method, Metacarpal bone fracture.

Number of Tables:04; Number of Figure: 01; Number of References: 10; Number of Correspondences: 04.

#### \*1. Corresponding Author:

##### Dr. Shaon Barua

Assistant Registrar  
Department of Orthopedic and Traumatology  
Chittagong Medical College Hospital  
Chittagong, Bangladesh.  
01717357959

#### 2. Dr. Md. Mizanur Rahaman Chowdhury

Professor and Head  
Department of Orthopedic and Traumatology  
Chittagong Medical College Hospital  
Chittagong, Bangladesh.

#### 3. Dr. Mamun Mustafa

Assistant Registrar  
Department of Orthopedic and Traumatology  
Chittagong Medical College Hospital  
Chittagong, Bangladesh.

#### 4. Dr. Syed Ariful Islam

Medical Officer  
Department of Orthopedic and Traumatology  
Chittagong Medical College Hospital  
Chittagong, Bangladesh.

#### 5. Dr. Rajarshi Nag

Registrar  
Department of Orthopedic and Traumatology  
Chittagong Medical College Hospital  
Chittagong, Bangladesh.

#### 6. Dr. Md Tayef Mahmud

Assistant Registrar  
Hand and Microsurgery  
Chittagong Medical College Hospital  
Chittagong, Bangladesh.

### Introduction

Human hand is a specialized structure interacting with the environment and is especially sensitive to functional impairment<sup>1</sup>. Hand is a prehensile organ and is endowed with grasping, precision movements for skilled works and act as a chief tactile apparatus. The opposition of thumb to the index finger and other digits is highly evolved in mankind for grasping and finer movements. Thus human hand represents a 'revolution in evolution'. Nowhere in the body, are the forms and function so closely related to each other than in hand. Hence any skeletal injury in hand is likely to alter the function. Fractures of bones of the hand are among the commonest fractures in humans.

Fractures of the metacarpal bones of the hand constitutes approximately 10% of all fractures visits to the hospital following trauma by various means like assault, road traffic accidents, industrial accidents, agricultural accidents<sup>2,3</sup>. Metacarpal fractures account for 30-40% of all fractures in hand<sup>4</sup>. Though large number of metacarpal fractures can be treated conservatively i.e. close reduction and plaster of paris cast immobilization. But cast immobilization is not very effective in maintenance of reduction and requires prolong immobilization<sup>5</sup>. Numerous indications for operative treatment include mal-rotation, angulation, longitudinally shortening, multiple fractures and fractures with associated soft tissue injuries or bone loss.<sup>6</sup> various methods of surgical fixation include lag screw alone, plate & screws percutaneous Kirschner wires, external fixator, depending upon fracture type, site and configuration<sup>7</sup>.

**Materials & Methods:**

A prospective observational study was conducted from February 2019 to January 2020 among 29 metacarpal bone fracture patients attending at orthopedic surgery department, Chittagong Medical College Hospital, Chittagong after obtaining requisite consent from the patient. Data were collected through the assessment and X-ray report of patients in the orthopedic surgery Department. The collected data were entered into the computer and analyzed by using SPSS (version 20.1) to assess the fixation methods for metacarpal bone fracture. The study was approved by the institutional ethical committee. After receiving initial treatment, patients were sent to the radiology department for an immediate X-ray. Purposive sampling was used in this study.

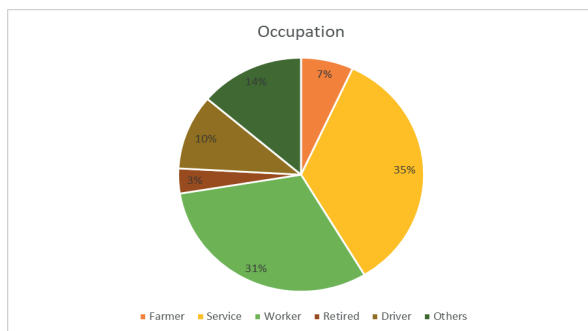
**Results:**

Most of the study population (89.7%) was in 18-40 years of age group. The mean age of the patients was 33.14 ± 11.895 years (range: 18-70 years) (Table I).

**Table 1: Distribution of the study patients (n=29)**

Age (years)	Number	percentage
18-40	26	89.7%
41-60	1	03.4%
> 60	2	06.9 %

Service was the mostly occurring occupation among the patients (35%) and worker were 31% (Figure I).



**Figure I: Occupation of the patients (n= 29)**

In our study transverse fracture was 51.7% and oblique

fracture was 41.4% (Table II).

**Table II: Fracture type of the study population (n=29)**

Fracture type	Number	percentage
Transverse	15	51.7%
Oblique	12	41.4%
Spiral	01	3.4%
Both transverse & oblique	01	3.4%

In case of method of fixation, maximum (65.5%) patient's fixations were done by mini plate, 31% were by K-wire and 3.4% were by both K-wire & lag screw (Table III).

**Table III: Fixation methods of metacarpal bone fracture (n=29)**

Fixation methods	Number	percentage
K-wire	09	31%
Mini plate	19	65.5%
Lag screw	0	0%
Both K-wire & Lag screw	01	3.4%

In case of number of metacarpal bone involvement, 1 bone was involved in maximum (75.9%), 2 bone were involved in 17.2% and 3 bone were involved in 6.9% patients (Table IV).

**Table IV: Number of metacarpal bone involvement in fracture (n=29)**

Number of bone involvement	Number	percentage
1	22	75.9%
2	05	17.2%
3	02	6.9%

**Discussion:**

In this present study, most of the study population (89.7%) was in 18-40 years of age group. The mean age of the patients was 33.14 ± 11.895 years (range: 18-70 years) (Table I). A recent study by Gupta et al. (2018) described the age distribution of the patients, all the affected patients were in the productive age group of 18-50 years<sup>8</sup>. Another recent study conducted by Reddy and Javali (2017) stated that mean age was 34 years with the range of 19-56 years<sup>9</sup>. Out of 29 patients, all of them were male, may be due to more outdoor activities of the males and hence making them more prone to trauma. Reddy and Javali (2017) found, out of the 15 patients, 12(80%) were male and 3(20%) were females. So men were predominant in all studies<sup>9</sup>. According to occupation, Service was the mostly occurring occupation among the patients (35%) and worker were 31%. A recent study done by Gupta et al. (2018) reported that, Factory laborers were observed to be the most affected group (72%) in their study because maximum patient attending their institute are industrial worker<sup>8</sup>. Regarding type of fracture, in our study transverse fracture

was 51.7% and oblique fracture was 41.4%. Venkatesh and Kerakkanavar (2017) found in their study, the fracture pattern was oblique in 12 patients, transverse in eight, spiral in six, and comminuted in four patients<sup>7</sup>. In the present study, out of 29 cases, in case of number of metacarpal bone involvement, 1 bone was involved in maximum (75.9%), 2 bone were involved in 17.2% and 3 bone were involved in 6.9% patients. A study by Mohanakrishnan (2014) revealed that single metacarpal involvement being the most common accounting for 70% of the cases<sup>10</sup>. This present study shows, in case of method of fixation, maximum (65.5%) patient's fixation were done by mini plate, 31% were by K-wire and 3.4% were by both K-wire & lag screw. Four different techniques of fracture fixation were used, depending upon the fracture type, site and configuration. In Gupta et al. 2018 study most of the patients were treated by Open reduction and internal fixation with plates and screws (47%) followed by fixation with screws and kirschner wire<sup>8</sup>.

**Conclusion:**

Surgical stabilization of metacarpal fractures of the hand seems to give good functional outcome. Closed or minimally invasive fixation with K-wire, mini plates and screws are safe methods and can be performed with minimal complications. Maximum (65.5%) patient's fixations were done by mini plate.

**Acknowledgements:**

The authors are grateful to the entire staff of the orthopedic surgery department, Chittagong Medical College Hospital, Chittagong for their cooperation and support during the study period.

**Conflict of Interests:** None.

**References:**

1. Diaz-Garcia, R. and Waljee, J. F. "Current management of metacarpal fractures". *Hand Clin.* 2013; 29: 507-518. <https://doi.org/10.1016/j.hcl.2013.09.004> PMID:24209950
2. Kamath, J. B., Harsvardhan, Naik, D. M., Bansal, A.

- "Current concepts in managing fractures of metacarpal and phalanges". *Indian J Plast Surg.* 2011; 44(2):203-211. <https://doi.org/10.1055/s-0039-1699505> <https://doi.org/10.4103/0970-0358.85341> PMID:22022030 PMCID:PMC3193632
3. Deshmukh, G., Rocha, S., Shyam, A., Sancheti, P. "Surgical and Functional outcome of metacarpal fracture". *J Medical thesis.* 2014; 2(1):7-10.
4. Dye, T. M. and Gellman, H. *Metacarpal fractures.* Medscape, 2018.
5. Kollitz, K. M., Hammaert, W. C., Vedder, N. B., Huang, J. I. "Metacarpal Fractures: treatment and complications." 2014; 9(1):16-23. <https://doi.org/10.1007/s11552-013-9562-1> PMID:24570632 PMCID:PMC3928373
6. Freeland, A. E., Orbay, J. L. "Extra-articular hand fractures in adults". *Clin Orthop Relat Res.* 2006; 445: 133-45. <https://doi.org/10.1097/01.blo.0000205888.04200.c5> PMID:16505726
7. Venkatesh, R. and Kerakkanavar, S. "Functional Outcome of closed metacarpal shaft fractures managed by low-profile miniplate osteosynthesis: A prospective study". *JOAS.* 2017; 5(2):63-67. [https://doi.org/10.4103/joas.joas\\_45\\_17](https://doi.org/10.4103/joas.joas_45_17)
8. Gupta, R., Kumar, K., Rakesh. A prospective study to analyse various methods of surgical fixation of metacarpal & phalangeal fractures. *IJOS.* 2018; 4(2): 658-663. <https://doi.org/10.22271/ortho.2018.v4.i2j.96>
9. Reddy, P. K. and Javali, V. "Metacarpal shaft fracture fixation with intramedullary k-wire: Surgical and Clinical outcomes." *Int J Orth Sciences.* 2017;3(2):222-225. <https://doi.org/10.22271/ortho.2017.v3.i2d.32>
10. Mohanakrishnan, V. "Functional Outcome of Closed Metacarpal Fractures Treated with Mini Fragment Plates and Screws - A Prospective Study. Thesis, Department of Orthopaedics, Madurai Medical College, Madurai." 2014.