

## Case Report

### Pulmonary Alveolar Microlithiasis(PAM)

Sarkar DN<sup>1</sup>, Hossain MI<sup>2</sup>, Haque MM<sup>3</sup>, Zahin AKM<sup>4</sup>, Miah MS<sup>5</sup>, Ohab MA<sup>6</sup>, Hossain A<sup>7</sup>, Beauty S<sup>8</sup>

#### Abstract

*PAM is a rare parenchymal Lung disease. Very few case report are available about PAM in Bangladesh. It is diagnosed incidentally during chest radiograph. It is a autosomal recessive disease and is associated with sporadic or familial mutation of SLC 34A2 gene. Many patients are asymptomatic and have either normal or restrictive pulmonary function. Some patients remain static and others progress into pulmonary dysfunction, respiratory failure and cor pulmonale. The disease is usually discovered up to 40 years and there is no definitive treatment of this disease. Chest radiograph, HRCT used lung biopsy (transbronchial or open) are the main investigations. This patient come with chest pain and dyspnoea on exertion and nonproductive cough and diagnosed as PAM incidentally during chest radiograph. On the basis of clinical features and laboratory finding, we diagnosed him a case of PAM a very rare condition. As there is no definitive treatment, we treat himsymptomatically.*

#### Case Report

A 25 years old businessman hailing from Haricharan, Pirgacha, Rangpur was admitted on Rangpur medical college Hospital on 17<sup>th</sup> September 2014 presented with chest pain for 5 to 3 years which is mild and not associated with exertion and is not radiated to another side and respiratory distress on exertion for 2 to 3 years which is gradually increasing. He has no recent history of respiratory tract infection and although he had a slight cough, sputum production was minimal. He has smoking history for 10 years and smoking 5 to 7 stick per day 3to 4 years back but had stopped smoking because of increasing dyspnoea. He has past history of pulmonary tuberculosis 12 to 13 years back. Then he Completed CAT-I anti-TB drugs. There is no history of consanguinity of marriage between his parents .General examination revealed patient was well looking having average body build according to his age, pulse-88 beat per minute, BP-120/80 mm of Hg, respiratory rate-18/min. He has no anaemia, jaundice, cyanosis or lymphadenopathy. All other Systemic examinations were revealed normal. Investigations reveals total count 8500/cmm, differential count-neutrophils 61%, lymphocytes 35%, monocytes 02%, eosinophils 02%, basophils 00%, heamoglobin 12.2g/dl, E.S.R 10mm at the end of 1st hour. (wintergreen method), random serum glucose 92mg/dl ,sputum for AFB- negative (2samples), mantoux test- negative, X-ray chest P/A view-shows suggestive of alveolar microlithiasis(figure I).

#### Corresponding Author:

1. Prof. Dr. Devendra Nath Sarkar, MBBS, MD, MCPS, FCCP, FRSM, FACP  
Professor, Department of Medicine  
Rangpur Medical College Hospital, Rangpur
2. Dr. Md. Ismail Hossain, MBBS  
OSD, DGHS (Deputed BSMMU)  
Dhaka, Bangladesh  
e-mail: drrussel27@gmail.com
3. Dr. Md. Mahmudul Haque, MBBS  
Asist. Register, Department of Medicine  
Rangpur Medical College Hospital, Rangpur
4. Dr. A K M Zahin, MBBS  
Asist. Register, Department of Medicine  
Rangpur Medical College, Hospital, Rangpur
5. Dr. Md. Shahin Miah, MBBS  
Register, Department of Medicine  
Rangpur Medical College Hospital, Rangpur
6. Dr. M A Ohab, MBBS, MD  
Asst. Professor, Department of Medicine  
Rangpur Medical College Hospital, Rangpur
7. Prof. Dr. Altaf Hossain, MBBS, MD, DMRD  
Professor, Department of Radiology  
Rangpur Medical College Hopital, Rangpur
8. Dr. Beauty Saha, MBBS, M.Phil  
Associate Professor, Department of Pharmacology

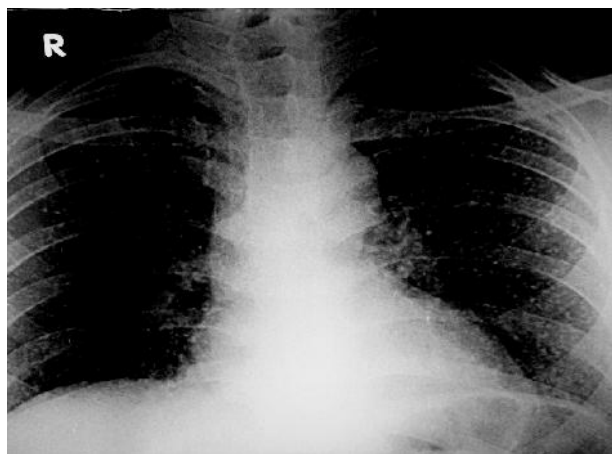


Figure I: Multiple millary motling like shadow all over lung field

ECG of All chest leads are within normal limit. Echocardiogram shows good LV systolic function. CT Scan of chest suggestive of alveolar microlithiasis (figure II). Forced expiratory volume in one second of 74% or 2.93L FEV1/FVC94%, PEFR=6.33 (68%)

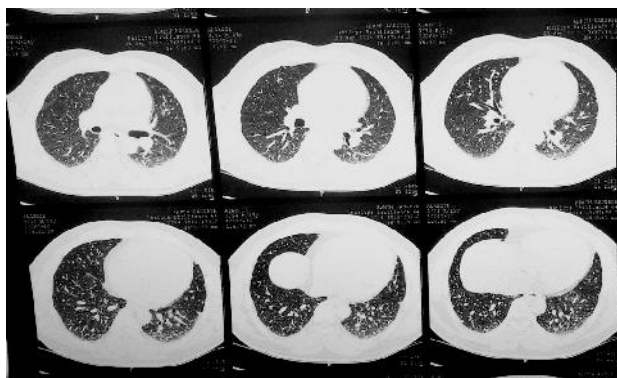


Figure II: Numerous hyperdense area all over lung field

### Discussion

PAM is a rare disease that presents chronic evaluation, poorly defined etiology and pathogenesis and is basically characterized by numerous calculi (denominated calciferites, calcospherites or microlites) within air spaces<sup>1-9</sup>. Patients may remain asymptomatic for many years and do usually become symptomatic between the third and fourth decades<sup>3,6,10</sup>. At clinical presentation Patients usually demonstrate a lung disorder with restrictive pattern<sup>3,5-7,12</sup>. Adult patients commonly show progressive deterioration of the pulmonary function and dead usually occur in mid-life because of respiratory failure associated with cor pulmonale<sup>7,11,12</sup> and there is no important predominance of gender<sup>2,4,14</sup>. The disease presents a high incidence of familiar occurrence (approximately one third of the cases) suggesting an autosomal recessive inheritance pattern<sup>2,5,8,10</sup>. Most reported cases of pulmonary alveolar microlithiasis have occurred in turkey, Japan and Italy, However the disease is not region specific, it may be seen any where in the world<sup>21,22</sup>. Although the aetiology of PAM remain unclear, mutations of SLC 34A2 gene, which encodes a type to sodium dependent phosphate co-transporter (Napi-11b) are considered to be the cause of the disease<sup>14</sup> SLC34A2 is primarily expressed in the lung and here only in alveolar type 2 cells<sup>14,15</sup>. These cells are responsible for production of surfactant. Loss of function of the gene due to mutations may lead to a decreased cell uptake of phosphate, which in turn may lead to formation of intra-alveolar microlithiasis as a result of phosphate chelating calcium in the extracellular fluid<sup>14,16</sup>. Although the SLC 34A2 gene is involved in phosphate homeostasis in several organs including the lung<sup>16,17</sup>, blood levels of calcium and phosphate are usually normal in Pam<sup>13,18,19,20</sup>. PAM is often diagnosed early in the clinical course of disease, although the result of the initial

laboratory work up are often unremarkable, with no identifiable underlying disorder of calcium metabolism<sup>23</sup>. However, even with early recognition of the disease, the lack of treatment option results in a poor long term prognosis<sup>22,23</sup>. Although patients with PAM often experience a protracted disease course, they may be asymptomatic for years before respiratory insufficiency become manifest<sup>21,22</sup>, typically as seen in our case, patients present with progressive dyspnoea, a restrictive pattern of lung disease and decreased diffusion capacity<sup>21,22,23</sup>. Respiratory insufficiency eventually progresses to pulmonary fibrosis, end stage lung disease and chronic pulmonary heart disease. Extra pulmonary involvement is uncommon<sup>22</sup>. Death is often due to a combination of pulmonary dysfunction and subsequent cor pulmonale<sup>22,23</sup>. On radiographs, PAM is characterized by diffuse fine calcific micro nodules that involve both lung in a pattern that is classically described as sand storm-like<sup>24,25,26,38</sup>.

Increased calcific densities are often more pronounced in the lower lung zones, a fact that has been attributed to the larger surface area and greater thickness of the lower part of the lungs<sup>27</sup>. High-resolution CT with thin section acquisitions and high spatial frequency, reconstruction algorithms is preferred for the evaluation of pulmonary alveolar microlithiasis because it allows detection of minimal structural changes of the lung parenchyma that are not optimally evaluated with radiography or with other CT techniques. The characteristic findings of extensive innumerable microlithiasis involving both lungs is noted with a predisposition for the posterior segments of the lower lobes and anterior segments of the upper lobes<sup>26-31</sup>. Additionally, the medial aspect of the lung appears to be more heavily involved than the lateral aspects<sup>26</sup>. 2r. microliths can also be seen along the bronchovascular and sub pleural interstitium, resulting in a thickened, micro nodular appearance of these structures<sup>26</sup>. Calcifications of the pleura also have been reported<sup>27</sup>. No definite treatment is available. Home oxygen therapy is necessary for the patients with respiratory insufficiency. Systemic corticosteroid and bronchoalveolar lavage have been shown to be ineffective. In general, No therapy has proved beneficial including whole lung lavage<sup>32,33</sup>. Lung transplantation has been performed in a few patients. Some patients have undergone bilateral sequential lung transplantation or unilateral lung transplantation<sup>34,35,36</sup>. Disodium etidronate, which is known to inhibit the microcrystal growth of hydroxyapatite has been used in the dose of 10 mg/kg per day orally for as long as on year with considerable regression of the calcific densities<sup>37</sup>.

In conclusion, PAM is diagnosed incidentally during chest radiograph. Most cases are asymptomatic for many years. But it may progress to cor pulmonale of any other deteriorating evaluation. For this, patient need follow up examination for long time.

## References

1. G. Barbolil, G. Rossi and A. Bisetti. Pulmonary alveolar microlithiasis. *New England Journal of Medicine*. 2002;347(1):69-70.
2. E. Marchiori, C. M. Gongalves, D. L. Escuissato, K.-I.-S. S. Teixeira, R Rodrigues, M. M. Barreto, et al. Pulmonary alveolar microlithiasis: high-resolution computed tomography findings in 10 patients. *Jonral Brasileiro de Pneumologia*. 2002;33(5):552-557.
3. H. Hoshino, H. Kob4 and H. Koba. Pulmonary alveolar microlithiasis: high-resolution CT and MR li16ings. *Journal of Computer Assisted Tomography*. 1998;22(2):245-248.
4. P. Cluzel, P. Grenier, P. Bernadac, F. Laurent, and J. D. Picar. Pulmonary alveolar microlithiasis: CT.findings. *Journal of Computer Assisted Tomography*. 1991;15(6):9384942.
5. M. A. Kom, H. Schurawitzki, W. Klepetko, and O. C. Burgh-uber. Pulmonary alveolar microlithiasis:findings on high-resolution CT. *American Journal of Roentgenology*. 1992;158(5): 981-982.
6. T. H. Helbiclq C. Wojnarovsky, P. Wunderbaldinger, G. Heinz-Peer, I. Eichler, and C. J. Herol.Pulmonary alveolar microtthiasis in children: radiographic and high-resolution g1 fiadings,AmericanJournal of Roentgenolog.1997;168(1):63-65.
7. L. Gasparetto, P. Tazoniero, D.L.Escuissato, E. Marchiori, R L. Frare Silv4 andD. Sakamoto,Pulmonary alveolar microlithiasis presenting with crazy-paving pattern on high resolution CT: *British Journal of Radiology*. 2004;17(923):974-976.
8. G. Castellana" M. Gentile, R Castellana P. Fiorente, and V. Lamorgese, Pulmonary alveolar microlithiasis: clinical features, evolution of the phenotype, and review of the literature. *American Journal of Medical Genetics*.2002;1(2):220-224.
9. S. Jankovic, N. pavlov, and N. Pavlov, Pulmonary alveolar microlithiasis in childhood: clinical and radiological follow-up:*Pediatric Pulmonology*.2002;34(5):384-387.
10. S. Mariotta A. Ricci, M. Papale, F. De Clementi, B. sposato, L. Guidi, and F' Mannino, Pulmonary alveolar microlithiasis: report oo szo cases published in the literature,'n sarcoidosis vasculitis and Difhrse Lung Diseases .2004;21(3):173-181.
11. T. Tachibana, K. Hagiwara, and T. Johkoh. Pulmonary alveolar microlithiasis: review and managemen: current opinion in *Pulmonary Medicine*. 2009;15(5):486-490.
12. M. N. Samanq p. n waisterg; M. canzian, s. v. campos, P. M. Pego-Fernandes, and F' B' Jatene'Lrmg transplantation for pulmonary alveolar microlithiasis: a case report .2010;65(2):233-236.
13. J Chan ED, Morales DV, welsh cH, et al. Calcium deposition with or without bone formation in the Tuns Am J Respir Crit Cue Med 2002; 165(1): 1654-1669.
14. Corut A, Senyrgt A, Ugur sA, et al. Mutaions in SLC34A2 cause pulmonary alveolar microlithiasis and r possibly associated with testicular microlithiasis- Am J Ham Genet. 2006;79: 650- 656.
15. Huqun, Izumi S, Miyazawa H,et al. Mutations in the SLC34A2 gene are associated with pulmonary alveolar microlithisis. *Am J Respir Crit Care Med*. 2007;175:263-268.
16. Feild JA, Zhang L, Brun KA, et al. Cloning and functional charecterization of a sodium dipendent phosphate transporter expressed in human lung and small intestine. *Biochem Biophys Res Commun*. 1999;258:578-582.
17. Murer H, Forster I, Biber J. The sodium phosphate cotransporter family SLC34. *Pflugers Arch*. 2004;44:763-767.
18. Prakash IJB. Pulmonry alveolar microlithiasis. *semin Respir crit care Med*. 2002; 23:103-113.
19. Moran CA, Hochholzer L, Hasleton PS, et al. Pulmonary alveolar microlithiasis. A clinicopathologic and chemicalanalysis of seven cases. *Arch Pathol Lab Med*. 1997;121: 607-611.
20. Coetzee T. Palmonary alveolar microlithiasis with involvement of the sympathetic neruous system and gonads.'*Thorax*. 1970;25:637-642.
21. Mariotta s, Ricci A, Papale M et al. Pulmonary alveolar microlithiasis report on 576 cases published in the literature. *Sarcoidosis vasc Diffuse Lung Dis*. 2004;21(3):173-181.
22. Tachibana T, Hagiwara K Johkoh T. Puhonary alveolar microlithiasis: review and management' *Curr Opin Pulm-Med*. 2009;15(5):486-490.
23. Castellana G, Gentil M; Castellana R,Fiorente P.Lamor V. Pulmonary alveolar microlithiasis, "clinical features, evolution of the phenotype, and review of the literature ' *Am J Med*. 2002;25(3):250-267.
24. Ucan ES, Keyf AI, aydilek R, et al. Pulmonary alveolar microlithiasis: review of Turkish reports. *Thorax* 1993;48(2):171-173.
25. Melamed JW, Sostman HD, Ravin CE. Interstitial thickening in pulmonary alveolar microlithiasis: an underappreciated finding. *J Thorac Imaging*. 1994;9(2):126-128.
26. Helbich TH , Wojnarovsky C, Wunderbaldinger P, Heinz-Peer G, Eichler I, Herold CJ. Pulmonary alveolar microlithiasis in children: radiographic and high-resolution CT findings. *AJR Am J Roentgenal*. 1997;168(1):63-65.

27. Gasparetto EL, Tazoniero P, E-cuissato DL, Marchiori E, Frare e Silva RL, Sakamoto D. Pulmonary alveolar microlithiasis presenting with crazy-paving pattern on high resolution CT. *Br J Radiol.* 2004;77(923):974-976.
28. Cluzel P, Grenier P, Bernadac P, Laurent F, Picard JD. Pulmonary alveolar microlithiasis: CT findings. *J Comput Assist Tomogr.* 1991;15(6):938-942.
29. Chalmers AG, Wyatt J, Robinson PJ. Computed tomographic and pathological findings in pulmonary alveolar microlithiasis. *Br J Radiol.* 1986;59(70):408-411.
30. Korn MA, Schurawitzki H, Klepetko W, Burghuber OC. Pulmonary alveolar microlithiasis: findings on high-resolution CT. *AJR Am J Roentgenol.* 1992;158(5):981-982.
31. Deniz O, Ors F, Tozkoparan E, et al. High resolution computed tomographic features of pulmonary alveolar microlithiasis. *Eur J Radiol.* 2005;55(3):452-460.
32. Mariotta S, Guidi L, Papale M, Ricci A, Biseui A. Pulmonary alveolar microlithiasis: Review of Italian reports. *Eur J Epidemiol.* 1997;13:587-590.
33. Mascie-Taylor BH, Wardman AG, Madden CA, Page RL. A case of alveolar microlithiasis: Observation over 22 years and recovery of material by lavage, *Thorax.* 1985;40:952-53.
34. Palombini BC, Da Silva Porto N, Wailau CU, Camargo JJ. Bronchopulmonary lavage in alveolar microlithiasis. 1981;8(2):242-243.
35. Stamatis G, Zerkowski HR, Doetsch N, Greschuchna D, Konietzko N, Reidemeister JC. Sequential bilateral lung transplantation for pulmonary alveolar microlithiasis. *Ann Thorac Surg.* 1993;56:972-975.
36. Edefuman JD, Bavaria J, Kaiser LR, Litzky LA, Patevsky HI, Kotloff RM. Bilateral sequential lung transplantation for pulmonary alveolar microlithiasis. 1997;112:1140-1144.
37. Jackson KB, Modry DL, Halenar J, L'abbe J, Winton TL, Lien DC. Single lung transplantation for pulmonary alveolar microlithiasis. *J Heart Lung Transplant.* 2001;20:226.
38. Sosman MC, Dodd GD, Jones WD, Pilmore GU. The familial occurrence of pulmonary alveolar microlithiasis. *Am J Roentgenol Radium Ther Nucl Med.* 1957;77(6):947-1012.