

## Original Article



# Accuracy of Multi-Detector Computed Tomography In the Diagnoses of Adnexal Masses

Sayedra Nurjahan Begum<sup>1</sup>, Most Razina Jubaida<sup>2</sup>, Nusrat Zahan<sup>3</sup>, Rubaiya Alam<sup>4</sup>

### Abstract

**Background:** Ovarian cancer is the 5<sup>th</sup> common cause of death in women. patients older than 30 years are high malignant potential group. The lifetime risk of dying from invasive ovarian cancer is about 1 in 95. Modern imaging techniques have demonstrated significant accuracy in the diagnosis and staging of adnexal masses that help the clinician in surgical and post-surgical treatment planning.

**Objective:** To determine the accuracy of multidetector computed tomography (MDCT) in diagnoses of benign and malignant adnexal masses, compare it with histopathological diagnoses and find out the sensitivity, specificity, positive predictive value, negative predictive value of MDCT in diagnoses of benign and malignant adnexal masses.

**Materials and Methods:** This cross-sectional observational study was carried out between January 2013 to December 2014 with 45 patients referred for an MDCT scan of the pelvic organ with a suspicion of adnexal mass in Dhaka Medical College, Dhaka. All the patients were evaluated by detailed history and clinical examination. CT scan of the pelvic organ was performed in all cases and the report was checked by the radiologists of DMCH. Operated patients were followed up after surgery up to histopathological diagnosis and correlated with CT scan findings.

**Results:** CT diagnosis for evaluation of benign adnexal mass, sensitivity was 90.0%, specificity 92.0%, accuracy 91.1%, PPV was 90.0% and NPV 92.0%. In the case of malignant mass, sensitivity is 92.0%, specificity 90.0%, accuracy 91.1%, PPV 92.0% and NPV 90.0%.

**Conclusion:** MDCT is a valuable modality in the diagnosis of benign and malignant adnexal masses.

**Keywords:** Adnexal mass, MDCT, Histopathology.

**Date of received:** 16.10.2022

**Date of acceptance:** 15.05.2023

**DOI:** <https://doi.org/10.3329/kyamcj.v14i02.66351>

*KYAMC Journal. 2023; 14(02): 74-78.*

### Introduction

The differential diagnosis for adnexal masses is broad, creating a diagnostic challenge.<sup>1</sup> Women of reproductive age are more likely to experience a benign process since menstruation women's ovaries develop physiologic cysts. However, the likelihood of a malignant neoplastic etiology is increased in prepubertal girls and postmenopausal women who have an adnexal mass.<sup>2</sup> The prevalence of adnexal masses in the general population is 0.17%-5.9% in asymptomatic women and 7.1%-12% in symptomatic women worldwide.<sup>3</sup> Ovarian cancer is the 5th common cause of death in women. 80% of ovarian masses in females under nine are malignant and typically consist of germ cell tumors.<sup>4</sup> 50% of adnexal neoplasms in

adolescence are mature cystic teratomas, also called dermoid cysts. 25% of females with Y-chromosome-containing gonads will develop a malignant tumor, most frequently a dysgerminoma. Up to 50% of people who arrive with a painful mass may also have endometriosis. After surgically removing adnexal masses from women of reproductive age, only 10% of masses are malignant; though in patients younger than 30 years many are of low malignant potential among them 33% are mature cystic teratomas, 25% are endometriomas and rest are serous or mucinous cystadenomas or functional cysts.<sup>5</sup> The lifetime risk of dying from invasive ovarian cancer is about one in 95.<sup>6</sup> If diagnosed at stage I (ovary confined), there is a greater than 90% survival rate at 5 years. At the time of diagnosis, the majority of patients (65–70% of cases) are found to have stage III

1. Consultant Radiologist, Ibn Sina Diagnostic and Consultation Centre, Badda, Dhaka, Bangladesh.

2. Assistant Professor, Department of Radiology and Imaging, Khwaja Yunus Ali Medical College and Hospital, Enayetpur, Sirajganj, Bangladesh.

3. Junior Consultant, Department of Radiology and Imaging, United Hospital, Dhaka, Bangladesh.

4. Specialist, Department of Radiology and Imaging, Square Hospital Ltd, Dhaka, Bangladesh.

**Corresponding author:** Sayeda Nurjahan Begum, Consultant Radiologist, Ibn Sina Diagnostic and Consultation Centre, Badda, Dhaka, Bangladesh. Cell Phone: +8801717034442, E-mail: njahanbd@yahoo.com

(upper abdominal or regional lymph node metastases) or stage IV (extra-abdominal or hematogenous metastases) disease with a 5-year survival rate of 30–73%.<sup>7</sup> Precise characterization of an adnexal lesion is important as it dictates further management; hence, the role of radiology is very important. Ultrasound is the first line modality to evaluate adnexal pathologies; however, most of the time it is unable to differentiate between benign, and malignant lesions and extent of disease in malignant cases. When conventional ultrasound reveals complex morphology other diagnostic tools such as color Doppler, functional tumor vessel properties, serum CA 125 levels, nuclear magnetic resonance imaging and in some cases laparoscopy correlation need.<sup>8</sup> Multidetector Computed Tomography is an excellent noninvasive modality to differentiate adnexal masses from benign and malignant causes. Multidetector CT with multiplanar reformation allows improved visualization of the normal anatomy, anatomic variants, as well as disease extension from female pelvis. Thin sections can be obtained over a large volume of tissue with improvement of sensitivity of CT in detecting peritoneal carcinomatosis. The acquisition of thin sections may allow detection of subcentimeter implants.<sup>9</sup> Multidetector computed tomography also allows comprehensive evaluation of primary tumour and the site of peritoneal metastasis, lymphadenopathy and the presence of ascites. Local data regarding ovarian mass evaluation by MDCT are scarce.<sup>10</sup> Therefore, the objective of this study was to evaluate the diagnostic accuracy of MDCT in our local population to differentiate between benign and malignant adnexal masses and to compare the findings with histopathologic results.

## Materials and Methods

This cross-sectional observational study was carried out between January, 2013 to December, 2014 with 45 patients referred for MDCT scan of pelvic organ with suspicion of adnexal mass. The study protocol was approved by the ethical review committee Dhaka Medical College, Dhaka. Informed consent was obtained from each participant or guardian. All the patients were evaluated by detail history and clinical examination with special emphasis on clinical features. Subsequently CT scan of pelvic organ was performed in all cases and report checked by the investigator and competent radiologists of the Department of radiology and imaging DMCH. Those patients who were operated on continuously followed up after the surgery up to histopathological diagnosis. The histopathological reports were collected and correlated with CT scan findings. All this information were collected in pre-designed structured data collection sheets. Inclusion criteria was Ultrasonographically suspected cases of adnexal masses. Exclusion criteria were- pregnant women, patient who did not give consent in the study procedure,

patients who were unfit for surgery or who unwilling for surgery, and patients whom histopathological reports could not be collected. Scanning technique: All MDCT studies performed using a 64-multislices MDCT system (Scenario 64 slice MDCT, Hitachi Japan). Image scanning parameters was as follows: 120 -130Kev, 150-200 mAs, Image slices of 10-mm-thickness were obtained followed by reconstruction in sagittal and coronal plane. MDCT scans of the abdomen and pelvis were taken, capturing the cranio-caudal region from the diaphragm to the symphysis pubis. The triple phase will be used in a consistent technique for all scans. The upper abdomen pre-contrast scan, arterial phase, and portal phase all came back 60 seconds after the arterial phase. The contrast medium (50 ml Iopamidol, 370 mg iodine/100mL) was administered. All patients will fixed during MDCT examination to prevent motion. The Statistical Package for Social Sciences version 16.0 for Windows (SPSS Inc., Chicago, Illinois, USA) was used to conduct the statistical analyses. Categorical variables were expressed as frequencies and percentages, whereas continuous variables were expressed as mean and standard deviation. In tables, figures, and diagrams, the results were displayed. Sensitivity, specificity, accuracy, positive predictive value, and negative predictive value of CT in the diagnosis of malignant and benign adnexal masses were calculated for the validity of the study outcome.

## Results

It was observed that almost one-third (31.1%) of patients belonged to age 21-30 years. The mean age was found to be 38.7±13.9 years, with a range from 18 to 65 years.

**Table I:** Distribution of the study population according to clinical presentation (n=45)

Clinical presentation	Number of patients	Percentage
Abdominal discomfort or pain	38	84.4
Decreased appetite or weight loss	24	53.3
Abnormal vaginal bleeding	22	48.9
Abdominal palpable mass	6	13.3

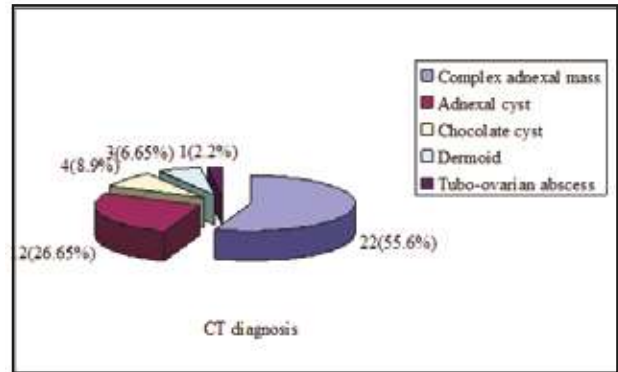
### Multiple responses

Table I shows the clinical presentation of the study population, it was observed that the majority (84.4%) of patients had abdominal discomfort or pain followed by 24(53.3%) had decreased appetite or weight loss, 22(48.9%) had abnormal vaginal bleeding and 6(13.3%) had abdominal palpable mass.

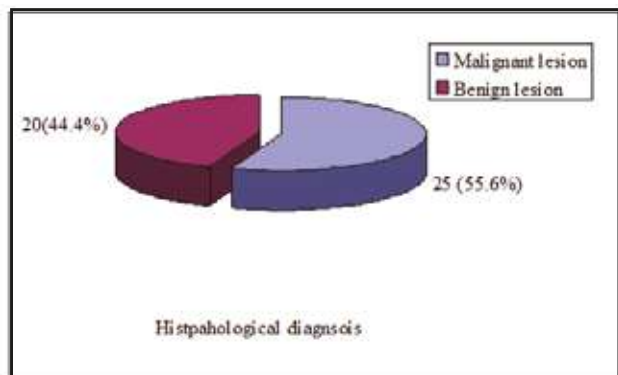
**Table II:** Distribution of the study population according to CT scan finding (n=45)

CT scan finding	Number of patients	Percentage
Site of tumor		
Ovary	23	51.1
Adnexa	22	48.9
Location		
Unilateral	27	60.0
Bilateral	18	40.0
Characterization		
Solid	4	8.9
Cystic		
With septation	15	33.3
Without septation	5	11.1
Mixed	21	46.7
Density of the lesion		
Isodense	3	6.7
Hypodense	20	44.4
Mixed density	22	48.9
Wall thickness		
Thick -walled	24	53.3
Thin -walled	21	46.7
Outline		
Smooth	15	33.3
Irregular	30	66.7
Contrast enhancement		
Enhancing	21	46.7
Non - enhancing	24	53.3
Other findings		
Ascites	20	44.4
Pleural effusion	16	35.6
Lymph node involvement	6	13.3
Omental thickening	6	13.3
Peritoneal seeding	6	13.3
Distant metastasis	3	6.7

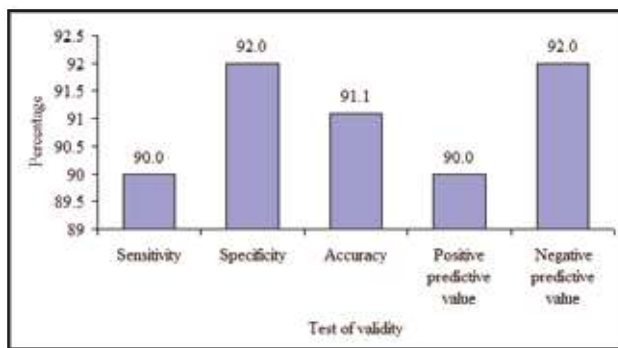
Table II shows CT scan findings of the study population, it was observed that more than half (51.1%) patients had site of ovary, unilateral location 27(60.0%), mixed characterization 21(46.7%), mixed density lesion 22(48.9%) and irregular margin 30(66.7%). Twenty one (46.7%) patients had enhancing and 24(53.3%) had non- enhancing. Majority (44.4%) patients had ascites in other findings.



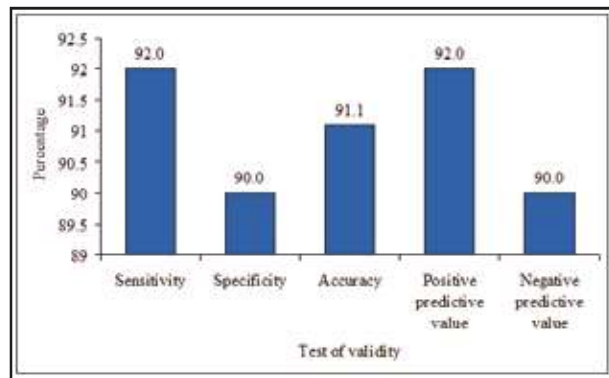
**Figure 1:** Pie chart showing CT diagnosis of the patients



**Figure 2:** Pie chart showing histopathological diagnosis of the patients



**Figure 3:** Bar diagram showing sensitivity, specificity, accuracy, positive and negative predictive values of the MDCT scan in the diagnosis of benign adnexal mass.



**Figure 4:** Bar diagram showing sensitivity, specificity, accuracy, positive and negative predictive values of the MDCT scan in the diagnosis of malignant adnexal mass.

## Discussion

In this present study, it was observed that almost one third (31.1%) of patients having adnexal mass were in 3<sup>rd</sup> decade, 17.8% in 4<sup>th</sup> decade, 17.8% in 5<sup>th</sup> decade, 20.0% in 6<sup>th</sup> decade, 6.65% in 7<sup>th</sup> decade and the mean age was  $38.7 \pm 13.9$  years varied from 18 to 65 years. Similarly, Jung et al. showed the mean age was  $41.1 \pm 13.4$  years, varied from 10 to 72 years.<sup>11</sup> On the other hand, Mubarak et al. and Gatreh-Samani et al. observed the mean age of the patients was  $50 \pm 17$  years and  $48.63 \pm 13.93$  years, respectively which may be due to geographical and racial influences may have significant impacts on adnexal mass.<sup>12,13</sup> In this current study, it was observed that the majority (84.4%) of patients had abdominal distention or pain followed by 53.3% had the decreased appetite or weight loss, 48.9% had abnormal vaginal bleeding and 13.3% had abdominal palpable mass. According to Goff et al.<sup>14</sup> combination of bloating, increased abdominal size and urinary symptoms was found in 43.0% of those with adnexal mass. Regarding the CT scan finding, it was observed in this series that site of tumor more than half (51.1%) of patients had in the ovary and 48.9% in Adnexa. Regarding the location, it was observed that unilateral and bilateral locations were found 60.0% and 40.0%, respectively. Jung et al.<sup>11</sup> observed 62.5% had unilateral and 37.5% had bilateral, malignant tumors, which closely resembled with the present study.

About the characterization, it was observed in this study that mixed characterization was found in 46.7% followed by cystic with septation 33.3%, cystic without septation 11.1% and Solid 8.9% of the patients having adnexal mass. Zhang et al.<sup>15</sup> obtained that the features most predictive of malignancy were heterogeneity for a solid lesion, multilocularity (>3 locules), irregular and thickened cystic septations or walls and the presence of internal vegetations for a cystic lesion. Imaging character of the lesion it was observed in this series that mixed 48.9%, hypo dense 44.4%, Iso dense 6.7% and Hyper dense was not found in these patients. It was observed in this study that the lesion had an irregular margin in 66.7%, thick-walled in 53.3%, thin-walled 46.7% and smooth margin in 33.3% of the patients. Contrast enhancement it was observed in this present study enhancing and non-enhancing were found 46.7% and 53.3%, respectively. Other findings evaluated by CT scan it was observed in this present study that ascites (44.4%) was more common, followed by pleural effusion 35.6%, lymph node involvement 13.3%, omental thickening 13.3%, peritoneal seeding 13.3% and distant metastasis 6.7% of the patients.

Irregular lesion contour and ancillary findings, including ascites, peritoneal implants, lymphadenopathy, and pleural effusion, were predictive of malignancy in both solid and cystic lesions observed by Zhang et al.<sup>15</sup> In this present study it was observed that the majority (55.6%) patients had complex adnexal mass, 26.65% had adnexal cyst, 8.9% had a chocolate cyst, 6.65% had dermoid and 2.2% had a tubo-ovarian abscess.

Regarding the Histopathological diagnoses, it was observed in this current study that 55.6% had malignant lesions, out of which 28.9% had serous cyst adenocarcinoma 22.2% had mucinous cyst adenocarcinoma and 4.4% had clear cell adenocarcinoma, Benign lesion observed 26.7%, chocolate cyst 8.9%, dermoid 6.7% and tubo-ovarian abscess 2.2%. Jung et al.<sup>11</sup> found the most common malignant tumor was endometrioid adenocarcinoma (9/45 malignant tumors; 20%) and the most common benign tumor was teratoma (43/133 benign tumors; 32.3%). Mubarak et al.<sup>12</sup> reported that malignant lesions included papillary carcinoma 18.0%, malignant mullerian tumor 12.0%, adenocarcinomas 32.0% and endometrioid carcinomas 14.0%. Benign lesions were simple ovarian cyst 2.0%, corpus luteal cyst 2.0%, benign cystadenoma 4.0%, dermoid 2.0%, teratomas 2.0% and endometriomas 12.0%. Histopathological diagnoses were as follows: serous cystadenoma: 84.0%; mucinous cystadenoma: 6.0%; cystadenofibroma: 6.0%; para ovarian cyst: 2.0%; and ovarian cancer: 2.0% observed by Castillo et al. The most common pathologic diagnoses observed by Modesitt et al.<sup>16</sup> found serous cystadenoma 52.0%, serous cystadenofibroma 12.0%, and mucinous cystadenoma 8.0%. There were no cases of ovarian carcinoma or ovarian tumors of low malignant potential. Hricak et al.<sup>2</sup> observed in malignant cases, serous cyst adenocarcinoma was found 40.6%, mucinous cyst adenocarcinoma 12.5%, clear cell adenocarcinoma 5.2% and in benign cases tubo-ovarian abscess was found 1.1% cases. The above-mentioned findings regarding the histopathological diagnoses are comparable with the current study.

The validity of CT diagnosis of malignant adnexal mass sensitivity was 92.0% (95% CI 84.1% - 99.1%), specificity 90.0% (95% CI 81.2% - 98.8%), accuracy 91.1% (95% CI 84.1% - 99.1%), positive predictive value was 92.0% (95% CI 84.1% - 99.1%) and negative predictive value 90.0% (95% CI 81.2% to 98.8%). Jung et al. (2014) result demonstrated that CT alone has a sensitivity varied from 92 - 95%, and a specificity varied from 74.0% - 80.0% for the diagnosis of malignant adnexal mass. Gatreh-Samani et al. (2011) reported that MDCT diagnosed 26.3%, 73.7% masses to be benign and malignant, respectively. MDCT sensitivity 92.8%, specificity 88.0%, positive predictive value 95.5%, negative predictive value 81.4% and accuracy 91.5% in evaluation of adnexal mass. Mubarak et al. (2011) found overall, MDCT was found to have 97.3% sensitivity, 91.6% specificity and 96% accuracy in the differentiation of benign and malignant ovarian masses, while PPV 97.3% and NPV 91.6%.

The validity of CT diagnoses in evaluation of benign adnexal mass sensitivity was 90.0% (95% CI 81.2% - 98.8%), specificity 92.0% (95% CI 84.1% - 99.1%), accuracy 91.1% (95% CI 82.8% - 99.4%), positive predictive value was 90.0% (95% CI 81.2% - 98.8%) and negative predictive value 92.0% (95% CI 84.1% to 99.1%). A meta-analysis conducted by Kinkel et al. (2005) described that CT showed sensitivity, specificity about 81%, 87% respectively. Similarly, Liu<sup>17</sup> reported a sensitivity of 87% and specificity 100% for differentiating benign from malignant ovarian cancers. Tsili et al.<sup>18</sup> also



described MDCT can categorize adnexal masses into benign and malignant in up to 93%, 89% of the cases. Mubarak et al. (2011) reported a sensitivity, and specificity about 97% ,91%, respectively, which all are comparable with the current study.

## Conclusion

This study was undertaken to determine the diagnostic accuracy of Multidetector Computed Tomography (MDCT) in the evaluation of adnexal mass, which is more common in the 3rd and above decade. Abdominal discomfort or pain, decreased appetite or weight loss and abnormal vaginal bleeding were more common clinical presentations of adnexal mass. Multidetector Computed Tomography was highly sensitive in the diagnosis of adnexal mass, which is well correlated with histopathology. So, it can be concluded that Multidetector Computed Tomography is a useful modality in the diagnosis of benign and malignant adnexal masses.

## Acknowledgement

With utmost regards, heartiest gratitude, and indebtedness to my guide, Professor and head of the department, Dr. M. Mahbubur Rahman, co-guide Assistant Professor Dr. Nazmum Nahar, my teachers and colleagues of the Radiology & Imaging Department, Dhaka Medical College, Dhaka, for their close supervision, constant courage and scholarly support from the project proposal till the completion of the study.

Lastly, I am grateful to all my patients, and their relatives for providing me with the required information and wish them better life.

## References

1. ACOG Practice Bulletin, Management of adnexal mass, Obstet Gynecol. 2007; 110, 1, 201-214.
2. Hricak H, Chen M & Coakey, Complex adnexal masses: detection and characterization with MR imaging-multivariate analysis, FV 2000; Radiology 214, 01, 39-46.
3. Myers BL, Havrilesky LJ, Cline KE, Terplan M, Kulasingham SL, Gray RN & McCrory, Management of Adnexal Mass, Evid Rep Technol Assess (Full Rep). DC. 2006; 130, 1-145.
4. Zalel Y, Piurac B, Elchalald U, Czernobilskiy B, Antebid S & Dgani, Diagnosis and management of malignant germ cell ovarian tumors in young females, International Journal of Gynecology & Obstetrics R. 1996; 55, 1-10.
5. Kinkel K, Lu Y, Mehdizade A, Pelte MF, Hricak. Indeterminate ovarian mass at US: incremental value of second imaging test for characterization--meta-analysis and Bayesian analysis. H 2005; Radiology. 236, 1, 85-94.
6. Cancer facts and figures. American Cancer Society Website. <http://www.ajronline.org/doi/full/10.2214/ajr.17.2009>. Accessed July 17, 2009
7. Horner MJ, Ries LAG, Krapcho M, et al. 2009, 'SEER Cancer Statistics Review, 1975-2006. National Cancer Institute', Bethesda, MD, [http://seer.cancer.gov/csr/1975\\_2006/](http://seer.cancer.gov/csr/1975_2006/), based on November 2008 SEER data submission, posted to the SEER web site, 2009
8. Perez-Lopez FR, Chedraui P & Troyano-Luque JM. Peri- and post-menopausal incidental adnexal masses and the risk of sporadic ovarian malignancy: new insights and clinical management. Gynecological Endocrinology, 2010; 26, 631-643.
9. Forstner R, Hricak H & White S. CT and MRI of ovarian cancer, Abdom Imaging 1995, 20, 2-8.
10. El-Badrawy A, Omran E, Khater A, Awad M & Helal. A 64 Multidetector CT with multiplanar reformation in evaluation of bilateral ovarian masses', The Egyptian Journal of Radiology and Nuclear Medicine 2012; 43, 285-291.
11. Jung SI, Park HS, Kim YJ & Jeon HJ. Multidetector Computed Tomography for the Assessment of Adnexal Mass: Is Unenhanced CT Scan Necessary', Korean J Radiol 2014; 15, 01, 72-79.
12. Mubarak F, Alam MS, Akhtar W, Hafeez S & Nizamuddin N. Role of multidetector computed tomography (MDCT) in patients with ovarian masses, International Journal of Women's Health, 2011; 03,123-126.
13. Gatreh-Samani F, Tarzamani MK, Sahebmadarek EO, Dastranj A and Frough A. Accuracy of 64-multidetector computed tomography in diagnosis of adnexal tumors, J Ovarian Re, 2011; 4, p. 15.
14. Goff BA, Mandel LS, Melancon CH & Muntz HG. Frequency of symptoms of ovarian cancer in women presenting to primary care clinics, JAMA. 2004; 291, 22, 2705-2712.
15. Zhang J, Mironov S, Hricak H, Ishill NM, Moskowitz CS, Soslow RA & Chi DS. Characterization of adnexal masses using feature analysis at contrast-enhanced helical computed tomography, J Comput Assist Tomogr, 2008; 32, 04, 533-540.
16. Modesitt SC, Pavlik EJ, Ueland FR, DePriest PD, Kryscio RJ and van Nagell JR. Risk of Malignancy in Unilocular Ovarian Cystic Tumors Less Than 10 Centimeters in Diameter, Obstet Gynecol 2003; 102, 594-599.
17. Liu Y. Benign ovarian and endometrial uptake on FDG PET-CT: patterns and pitfalls, Ann Nucl Med. 2009; 23, 107-112.
18. Tsili AC, Tsampoulas C & Charisiadi A. Adnexal masses: accuracy of detection and differentiation with multidetector computed tomography, Gynecol Oncol. 2008; 110, 22-31.