

## Tubulovillous Adenoma of Duodenum: A Case Report

Ahmed T<sup>1</sup>, Islam M<sup>2</sup>, Hassan MR<sup>3</sup>, Alam MS<sup>4</sup>

**Conflict of Interest:** None

**Received:** 02.12.2019

**Accepted:** 17.02.2020

[www.banglajol.info/index.php/JSSMC](http://www.banglajol.info/index.php/JSSMC)

### Key Words:

Tubulovillous Adenoma,  
Duodenum.

### Abstract:

*Tumors arising from the upper GIT are usually of epithelial origin and are mostly benign. Even when they do occur, they are usually considered as premalignant lesions with a risk of transformation to malignant ones. Tubulo-villous adenomas represent lesions that are histologically intermediate between tubular and villous polyps. These account for the majority of colonic polyps. We present a case of benign adenomas arising from the duodenum, an extremely rare diagnosis with an average annual incidence rate of 9.9 per million people. Among these uncommon tumors, Duodenal tumors are even rarer with average incidence rate of 0.4% only. Histopathological examination mostly shows villous type. Tubulo-villous histology is extremely rare with an incidence of less than 1% of all duodenal tumors. However, these tumors are being diagnosed with increasing frequency due to more widespread use of endoscopy.*

[J Shaheed Suhrawardy Med Coll 2020; 12(1): 58-60

DOI: <https://doi.org/10.3329/jssmc.v12i1.51621>

### Introduction:

Duodenum is lined by columnar epithelium. Small intestinal primary tumors are quite rare with an incidence equal to one-tenth of the similar tumors of the colon. <sup>1</sup> Less than 1% of all duodenal neoplasms comprise tubulovillous adenomas. <sup>2</sup> Approximately 88% of all the tubulovillous adenomas are found in the second part of the duodenum, while the rest 12% are found in the first and third part of the duodenum with equal distribution in both. <sup>3</sup> These tumors arise either sporadically or as a part of certain genetic syndromes such as Gardner's syndrome, familial adenomatous polyposis (FAP). <sup>4,5</sup> These tumors tend to cause bleeding or intestinal obstructions commonly at the duodenum and ampulla of Vater. They are usually found incidentally during upper gastrointestinal endoscopy, familial adenomatous polyposis surveillance, and evaluation of symptomatic ductal obstruction. Tumors of the ampullary region have a tendency to malignant

transformation with approximately 15% to 25% of the lesions develop into malignant neoplasms. <sup>6</sup> This rate is even higher once the tumor size exceeds two centimeters (cm). It is, therefore, important to act vigilantly when dealing with these tumors and perform a biopsy with resection and watchful follow-up of these lesions. <sup>7</sup> We report a unique case of a 40-year-old female who presented with epigastric pain and anorexia due to tubulovillous adenomas of the duodenum.

### Case Summary:

A 40 year old normotensive, non-diabetic female patient was presented to surgery department of Shaheed Suhrawardy Medical college Hospital with the complains pain in upper abdomen for 1 year which was burning in nature, with no radiation in abdomen, no relation with food intake. She also complains for anorexia for 1 year. There was no history of hematemesis or melena. On general survey and abdominal examination, no abnormalities were found. Other systemic examination reveals no abnormality.

Her blood reports including complete blood count, Liver function and renal function test were completely normal. Ultrasound study of whole abdomen revealed no abnormal finding, whether CT scan of whole abdomen showed fairly large enhancing mass (4.7×4.6×2.3 cm) lesion at the third part of duodenum with extension into second part of duodenum suggesting neoplastic origin. Endoscopy showed a big polypoid mass at the second part of

1. Dr. Tanvir Ahmed, Registrar, Surgery, Shaheed Suhrawardy Medical College Hospital, Dhaka.

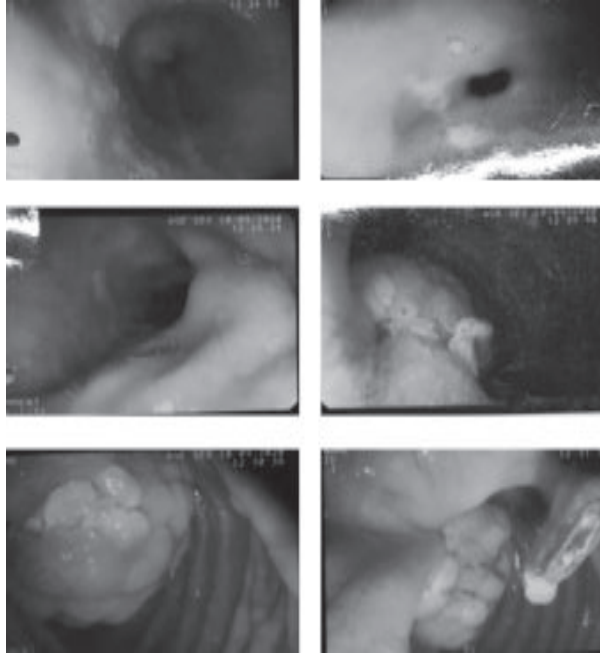
2. Dr. Mansurul Islam, Assistant, Surgery, Shaheed Suhrawardy Medical College Hospital, Dhaka.

3. Dr. Mohammad Rashedul Hassan, Medical Officer, Surgery, Shaheed Suhrawardy Medical College Hospital, Dhaka.

4. Mohammed Shah Alam, Honorary Medical Officer, Shaheed Suhrawardy Medical College Hospital, Dhaka.

**Address of Correspondence :** Dr. Tanvir Ahmed, Registrar, Surgery, Shaheed Suhrawardy Medical College Hospital, Sher-e-Bangla Nagar, Dhaka-1207, Bangladesh. Mobile: +88 01672586600, Email: [dr.tanvir41@gmail.com](mailto:dr.tanvir41@gmail.com)

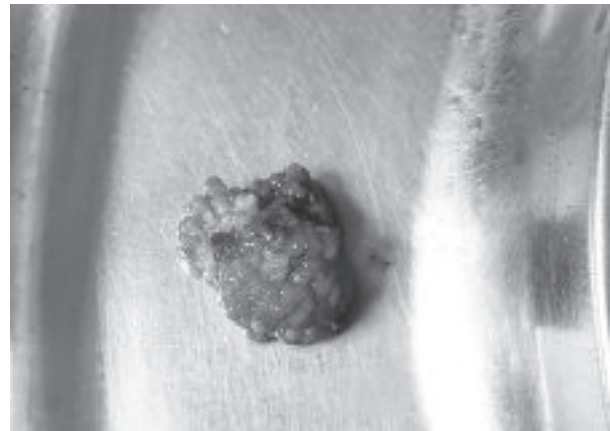
duodenum and biopsy revealed Villous adenoma with low grade dysplasia.(Fig-1)Colonoscopy was done to exclude any polyps in colon,FAP and Gardner's syndrome as duodenal tubulovillous adenoma is commonly associated with these diseases.Then laparotomy followed by duodenotomy and excision of duodenal mass followed by gastrojejunostomy was done (Fig-2) and specimen sent for histopathology which reveals Tubulo-villous adenoma with low grade dysplasia.(Fig-3)No postoperative complications were observed and the patient was discharged on the eleventh postoperative day.



**Fig 1:** Endoscopy findings: Tubulo-Villous adenoma in the second part of duodenum



**Fig. 2:** Peroperative view of duodenal Tubulo-Villous adenoma



**Fig .-3:** Final specimen of duodenal Tubulo-Villous adenoma

### Discussion

The small intestine is the longest part of the gastrointestinal tract, accounting for 75% of its length and 90% of the mucosal surface.<sup>8</sup> Of all the gastrointestinal malignancies, benign tumors are approximately 3% to 6%, while malignant tumors are 1% to 3%.<sup>7</sup> Small bowel tumors include carcinoids, adenocarcinomas, lymphomas, sarcomas, gastrointestinal stromal tumors as well as a variety of benign polyps.<sup>8</sup> Over forty different histological subtypes of malignant tumors have been identified but the four most common include adenocarcinoma, neuroendocrine tumors, sarcomas and lymphomas.<sup>9</sup> Benign lesions include polyps such as found in familial adenomatous polyposis (multiple small bowel polyps), Peutz-Jeghers syndrome (benign hamartomatous polyps) and Gardner's syndrome. Adenomas are considered to be the common tumors of colon. Endoscopic studies on the duodenal lesions show that the incidence of duodenal adenoma in all patients referred to diagnostic endoscopy is 0.4%.<sup>7,9</sup> They are unusual finding in the small intestine especially in the upper part of the small intestine e.g. duodenum. Villous tumor of the duodenum (VTD) was first described by Perry in 1893 and he called it duodenal papilloma.<sup>10</sup> These lesions are quite uncommon as Ring EJet al. reported only 73 cases.<sup>11</sup>

Tubulo-villous tumors of the duodenum account for less than 1% of all duodenal neoplasms.<sup>12</sup> There are various pathological terms used for various stages of the tumor i.e. villous adenoma, villous papilloma, papillary adenoma, tubulovillous adenoma, and villo-glandular polyp.

Tubulovillous adenomas may include small, sessile, or polypoid lesions. They are discovered incidentally on

endoscopy. Duodenal villous and tubulovillous tumors are often clinically silent.<sup>13</sup> Though they are mostly asymptomatic, sometimes they may present with the signs and symptoms of jaundice (obstructive jaundice), abdominal pain, melena, hematochezia, fever, malaise or weight loss. Physical examination may reveal hard epigastric areas on palpation. Imaging can reveal an ulcerated tumor, dilatation or extensive involvement of the common bile duct and/or pancreatic duct. These tumors can also present with some serious complications such as pancreatitis, duodenal obstruction or intussusceptions.<sup>14,15</sup> The diagnostic test of choice is endoscopy with biopsy of the mass, usually around the ampulla of Vater. Tubulovillous adenomas show a combination of tubular and villous architecture (villous component greater than 25%) and are usually intramural with intraepithelial tumor cells.

The treatment technique is usually decided on the basis of size, extent, and location of the tumor as well as its histopathology. These tumors are usually treated surgically using different techniques including polypectomy, duodenotomy, duodenal segment resection, and submucosal excision or duodenopancreatectomy.<sup>16</sup> Recurrence of benign villous tumors after local excision is common and may be malignant. Among patients with adenomas of the duodenum who had a local excision on endoscopic surveillance, recurrence rates were 32% at five years and 43% at 10 years; around one-fourth of the recurrences were adenocarcinomas.<sup>17</sup> Sakorafas GH et al. in a study comparing outcomes of Whipple's procedure done on patients with periampullary cancers over two different time periods reported a recent decline in operative morbidity and mortality.<sup>18</sup> Pancreaticoduodenectomy is the treatment of choice for malignant villous tumors of the duodenum, however, there is evidence of an adenoma-carcinoma-sequence and villous adenoma. Komorowska et al. reported adenocarcinoma to be associated in 50% cases of villous adenoma.<sup>19</sup> Therefore, pancreaticoduodenectomy can be performed in selected patients of benign villous tumors with low-grade dysplasia. Mandatory postoperative endoscopic surveillance is required if local excision is performed.

### Conclusion:

Tubulovillous adenomas of the duodenum are very rare with an incidence of 0.4% of all the small intestinal lesions. Traditionally small bowel tumors are difficult to diagnose. But its reported incidence is on rise due to the wide spread availability and use of the upper gastrointestinal endoscopy mainly and other imaging like CT scan of abdomen.

### References:

1. Jin SG, Chen ZY, Yan LN, Zeng Y, Huang W, Xu N. A rare case of periampullary carcinoma with ectopic ending of Vater's ampulla. *World J Gastroenterol* 2009; 15(37): 4729-4731.
2. Yan JQ, Peng CH, Yang WP, Ding JZ, Zhou GW, Ma D, Li HW. Surgical management of benign duodenal tumours. *ANZ J Surg* 2010; 80 (7-8): 526-530.
3. Ramesh J, Council L, Wilcox CM. Recurrent pancreatitis caused by pancreatic ductal villous adenoma treated with endoscopic snare polypectomy. *Endoscopy* 2013; 45: 23-24.
4. Sugita R, Furuta A, Ito K, Fujita N, Ichinohasama R, Takahashi S. Periampullary Tumors: High-Spatial-Resolution MR Imaging and Histopathologic Findings in Ampullary Region Specimens. *Radiology* 2004; 231:767-774.
5. Izgur V, Dass C, Solomides CC. Best cases from AFIP: Villous duodenal adenoma. *AFIP archives. Radiographics* 2010; 30:295-299.
6. Pham DT, Hura SA, Willmann JK, Nino-Murcia M, Brooke Jeffrey Jr R. Evaluation of Periampullary Pathology With CT Volumetric Oblique Coronal Reformations. *AJR* 2009; 193: 202-208.
7. Pourmand K, Itzkowitz SH. Small bowel neoplasms and polyps. *Curr Gastroenterol Rep.* 2016; 18:23-25.
8. Aslan S, Çetin B, Markoç F, Çetin A. A duodenal villous adenoma associated with in situ carcinoma: a case report. *Turk J Cancer* 2001;31:162-167.
9. McFarlane Me. Villous tumor of the duodenum: report of a case and review of the literature. *J Hepatobiliary Pancreat Surg.* 2001;8(1):107-9.
10. Chappuis CW, Divincenti FC, Cohn I Jr. Villous tumors of duodenum. *Ann Surg* 1989; 209:593-598.
11. Ring EJ, Ferrucci JT Jr, Eaton SB Jr, Clements JL. Villous adenomas of the duodenum. *Radiology* 1972; 104:45-48.
12. Chini P, Draganov PV. Diagnosis and management of ampullary adenoma: The expanding role of endoscopy. *World J Gastrointest Endosc* 2011 December 16; 3(12): 241-247.[ Links ]
13. Patel R, Varadarajulu S, Wilcox CM. Endoscopic ampullectomy: techniques and outcomes. *J Clin Gastroenterol.* 2012;46(1): 8-15.
14. Azih LC, Broussard BL, Phadnis MA, Heslin MJ, Eloubeidi MA, Varadarajulu S, Arnoletti JP. Endoscopic ultrasound evaluation in the surgical treatment of duodenal and peri-ampullary adenomas. *World J Gastroenterol.* 2013; 19(4): 511-515.
15. Farah MC, Jafri SZ, Schwab RE, Mezwa DG, Francis IR, Noujaim S, Kim C. Duodenal neoplasm: role of CT. *Radiology* 1987;162:839-843.[ Links ]
16. Kazerooni EA, Quint LE, Francis IR. Duodenal neoplasm: predictive value of CT for determining malignancy and tumor respectability. *AJR Am J Roentgenol* 1992;159:303-309.[ Links ]
17. Sakorafas GH, Friess H, Dervenis CG. Villous tumors of the duodenum: biologic characters and clinical implications.. *Scand J Gastroenterol.* 2000;35:337-344.
18. Villous tumors of the duodenum: a clinicopathologic study. Komorowska RA, Cohen EB. *Cancer.* 1981;47:1377-1386.