



## Original Article

# Laparoscopic management of perforated appendicitis-a study of 90 cases

Md. Manir Hossain Khan<sup>1</sup>, Jobaida Sultana<sup>2</sup>, Tazin Ahsan<sup>3</sup>, S.M. Abu Ahsan<sup>4</sup>

### Abstract:

**Introduction:** Acute appendicitis is the most common general surgical emergency in the world. It may cause potential risk for patients due to its life threatening complications like burst (perforation). The perforated appendicitis often leads to serious infectious complication like abdominal sepsis, pelvic abscess & etc. There are concerns of using laparoscopic appendectomy to perforated appendicitis. Now a days laparoscopic management of perforated appendicitis is the standard surgical option in many countries. Laparoscopic procedure has tremendous advantages over the open procedure regarding its diagnosis, exclusion of additional pathology, surgical treatment, wound infection (port infection), hospital stay & overall patient's satisfaction. The aim of this prospective study was to evaluate the role and application of laparoscopy in the management of complicated appendicitis (perforation).

**Methods:** It is a prospective study conducting during January 2011 to May 2019 in BSMMU and some private hospitals of Dhaka, Bangladesh. It includes 90 patients in whom laparoscopic appendectomy & peritoneal lavage was performed. Three ports technique were used. Sometimes 4<sup>th</sup> port is required. 10 mm port is telescopic port. The other one is 3/5 mm port and another one is 5/10 mm port. Energy source is unipolar diathermy. Intracorporeal knotting, endoloop and haemoclip are used for haemostasis & ligating appendicular stump.

**Results:** Age distribution of the study is 3-90 years, mean 17 years. Male is predominant. Duration varies 10-120 minutes, mean 70 minutes. Hospital stay varies 30-120 minutes, mean 70 minutes. Hospital stay varies from 48-96 hours, mean 64 hours. There were 8 complications- single (5, 5.55%) or multiple (3, 3.33%) port infections, paralytic ileus (2, 2.22%) and diarrhea (1, 1.11%), port TB was identified (3, 3.33%) cases among the port infection. Conversion was 1 (1.11%) for controlling haemorrhage of burst appendicitis. All complications are managed conservatively.

**Conclusion:** Total management of perforated appendicitis by laparoscopy is excellent. So it is achievable, feasible & can be done by expert hand in any center. Now it is considered as standard procedure.

**Keywords:** Perforation (burst), Laparoscopic Appendectomy

1. Associate Professor, Department of Surgery, Bangabandhu Sheikh Mujib Medical University (BSMMU)
2. Associate Professor, Department of Gynaecology and Obstetrics, Shahid Suhrawardy Medical College Hospital (ShSMC)
3. Honorary Medical Officer, Department of Surgery, Bangabandhu Sheikh Mujib Medical University (BSMMU)
4. Associate Professor, Department of Surgery, Ad-din Sakina Medical College, Jessore

**Correspondence to:** Dr. Md. Manir Hossain Khan, Associate Professor, Department of Surgery, Room no- 915, Block- C, Bangabandhu Sheikh Mujib Medical University (BSMMU), Shahbagh, Dhaka-1000, Number : +8801715024896, e-mail – dmanirhk@gmail.com

**Received:** 10-06-2019

**Accepted:** 30-06-2019

### Introduction:

The role of vermiform appendix in human physiology is yet to be ascertained completely. This blind-tube shaped muscular organ is known is familiar to the surgeons since the dawn of medical science primarily for its tendency to get inflamed. Labeled as the most common cause of acute abdomen. Acute appendicitis may lead to life threatening complications. In many parts of the world appendectomy is the most commonly performed urgent abdominal surgery<sup>1</sup>. The young surgical trainees, most often, have their baptism

in the world of major surgery by performing appendectomy.

Having mucosal, submucosal and serosal layers, the vermiform appendix is a blind muscular tube connected to the caecum. The average length is between 7.5-10cm and the lumen is irregular, surrounded by multiple longitudinal folds of mucous membrane with columnar cell intestinal mucosa of colonic type. The position of the base of the appendix is constant, at the meeting point of the three taenia coli of the caecum, but the position of the tip is variable. Its arterial supply is derived from appendicular artery, a branch of ileo-colic artery. It is an end artery. The Kulchitsky cells at the crypts of appendix may give rise to carcinoid tumours<sup>2</sup>.

Acute appendicitis is the most common general surgical emergency in the world and its operation like laparoscopy is also the most common emergency operation. It may cause potential risks for patients due to its life threaten complications like burst (perforation), abscess. The perforated appendicitis often leads to serious infectious complication like abdominal sepsis, pelvic abscess & etc. There are concerns of using laparoscopic appendectomy to perforated appendicitis. Now a days laparoscopic management of perforated appendicitis is the standard surgical option in many countries. Laparoscopic procedure has tremendous advantages over the open procedure regarding its diagnosis, exclusion of additional pathology, acute abdomen of female patient, surgical treatment, wound infection (port infection), hospital stay & overall patient's satisfaction. The aim of this study was to evaluate the role and application of laparoscopy in the management of complications of acute appendicitis (perforation).

Historically known as perityphlitis since the late 1500s, Reginald Fitz first drew the attention of the surgeons towards appendicitis as a clinical entity in 1886. Charles McBurney was the pioneer in describing the clinical signs and symptoms of acute appendicitis<sup>3</sup>. Pointing sign and Rovsing's sign<sup>4</sup> were also elicited to aid the clinical diagnosis. The Alvarado (MANTRELS)<sup>5</sup> scoring system was used where score of 7 or more strongly suggested acute appendicitis and 5-6 was considered equivocal<sup>6</sup>.

Surgery is the standard method of management of appendicitis<sup>7</sup>. Though there are many studies advocating the option of conservative treatment in the uncomplicated cases, surgery is a must if any complication arises. Conservative treatment comprises

rest to the bowel and antibiotics, mostly intravenous. Metronidazole and 3<sup>rd</sup> generation cephalosporins are the preferred ones<sup>8</sup>. In elderly patients, after the conservative treatment, the presence of malignancy must be excluded. The clinical condition of the patient must be taken into consideration before performing the surgery. If the condition of the patient permits, they are usually prepared by a short period of intensive pre-operative preparation by intravenous fluids to ensure adequate urine output, and appropriate antibiotics<sup>9</sup>.

Laparoscopy as a diagnostic tool is highly valuable in differentiating the various clinical conditions that mimic appendicitis<sup>10</sup>. Like other laparoscopic surgeries, the placement of the ports vary depending on the choice and experience of the surgeon and previous abdominal scars. Three ports technique were applied. 10 mm port is telescopic port. The other one is 3/5 mm port and another one is 5/10 mm port. Pneumoperitoneum was created with help of carbon dioxide gas which is physiologically suitable and advantageous over oxygen or atmospheric air<sup>11</sup>. An infra-umbilical port is used to establish pneumoperitoneum by carbon dioxide and to insert the camera, while the other ports were made in the suprapubic region and left-iliac fossa under direct vision. The surgeon stands on the left of the patient. To improve exposure, the patient is kept in Trendelenburg position with elevation of the right side of the operating table. The taenia coli are used to identify the base of the appendix<sup>12,13</sup> and held with forceps. After the meso-appendix is displayed, it is dissected using dissecting forceps or hook or scissors and the appendicular artery gets exposed, which is then either clipped or coagulated. Sometimes, the caecum needs mobilization (by dividing the peritoneal attachments) to gain adequate exposure of the appendix. After the appendix is free of its mesentery, it is ligated at the base with absorbable suture and then removed through one of the operating ports<sup>1,14</sup>.

#### Methods:

It is a prospective study conducted during January 2011 to May 2019 in BSMMU and some private hospitals of Dhaka, Bangladesh. It includes 90 patients in whom laparoscopic appendectomy & peritoneal lavage was performed. Three ports technique were used. Sometimes 4<sup>th</sup> port is required. 10 mm port is telescopic port. The other one is 3/5 mm port and another one is 5/10 mm port. Energy source is unipolar diathermy. Intracorporeal knotting, endloop and

haemoclip are used for haemostosis & ligating appendicular stump.

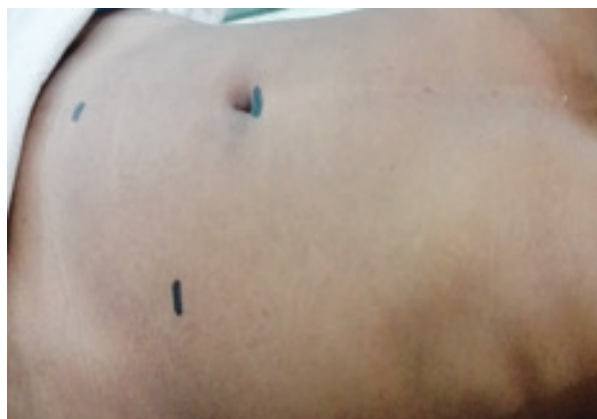Diagnosis was made based mostly on clinical examinations along with the help of some routine laboratory, imaging and radiological investigations. Periumbilical colic, pain shifting to the right iliac fossa, nausea, anorexia, rising body temperature were among the commonest symptoms. Among the clinical signs commonly encountered were pyrexia, localized tenderness in the right iliac fossa, muscle guarding and rebound tenderness. Pointing sign, McBurney's sign, Rovsing's sign, rebound tenderness (Release sign), Psoas sign and Obturator sign were also elicited to aid the clinical diagnosis. Among the laboratory, imaging and radiological investigations complete blood count (showing neutrophilic leucocytosis), urine routine and microscopic examination (to exclude UTI), ultrasound of the whole abdomen (to exclude other abdominal pathology and to see the condition of the appendix), pregnancy test and  $\beta$ -hCG (for females of reproductive age) and CT scan of the abdomen (some selected cases) were performed. The Alvarado (MANTRELS) scoring system/ modified Alvarado (MANTRELS) scoring system was used where score of 7 or more strongly suggested acute appendicitis and 5-6 was considered equivocal. Patients were included if they had - a) The Alvarado score of 7 or more b) Clinical signs and symptoms strongly suggestive of acute appendicitis or, its complications. c) Clinical diagnosis inconclusive but investigations suggestive. After selecting the patients, the diagnosis was again confirmed clinically and further supported by lab and radiological investigations if necessary (to reduce the risk of negative appendicectomy). The patients were prepared for laparoscopic surgery under general anesthesia.

After meticulous counseling, informed written consent was taken from the patients or, the parents in case of minors. Under general anesthesia patients were placed in supine position. Three sites were marked for the insertion of the port – at the supraumbilicus (10mm port for induction of pneumoperitoneum and introduction of telescope), in the lower midline above the pubic symphysis avoiding the bladder (5 mm port) and, in the left iliac fossa avoiding the inferior epigastric artery. Pneumoperitoneum was created with help of carbon dioxide gas which is physiologically suitable and advantageous over oxygen or atmospheric air. To gain better view of the right iliac fossa, the patient was rotated to the left side with some head-down tilt.

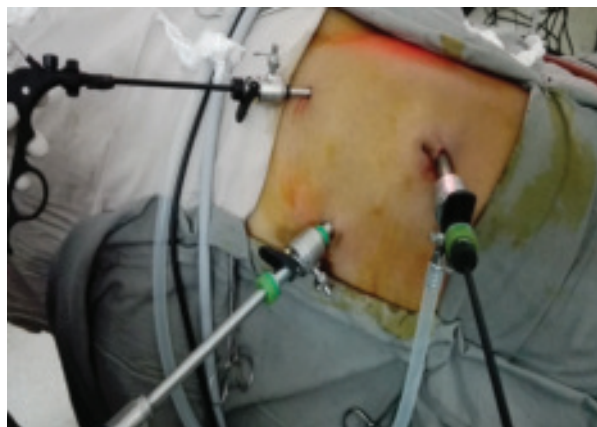
The abdominal cavity was inspected to find out any other abnormality or any collections. After toileting of

peritoneal cavity like pelvic cavity, subphrenic spaces, subhepatic spaces, paracolic gutter, subcolic and supracolic spaces then give the attention to appendix. The appendix was separated from its mesentery with the help of diathermy dissection if possible. The vessels close to the appendix were controlled by diathermy. Appendicular artery is controlled by diathermy. Appendix was fully mobilized before it was attempted to be removed. The base of the appendix was sutured by tying intra-corporeal knots using absorbable suture (Vicryl 2/0) and the appendix transected. Initially haemoclip is applied for stump control of few cases. Energy source is unipolar diathermy. Intracorporeal knotting, endoloop and haemoclip are used for haemostosis & ligating appendicular stump. It was taken out by the 10mm port. Multiple drains keep in situ if necessary.

The patients were kept nil by mouth for the next 24-48 hours depending on the condition and was discharged on the 3<sup>rd</sup> – 5<sup>th</sup> post-operative day. They were followed up after 4 weeks and 8 weeks. Long term outcome was assessed by telephone survey.

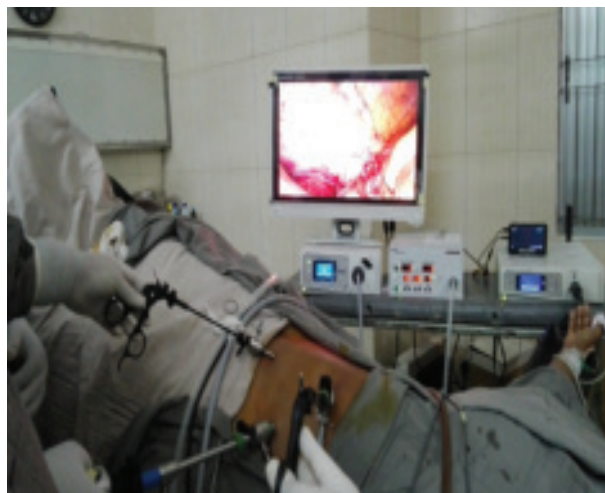

**Figure 1.** Ports marking

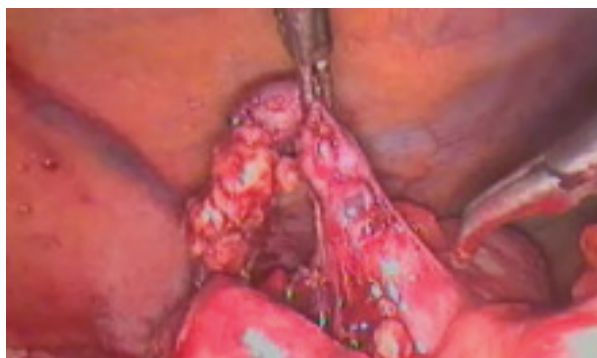

**Figure 2.** Ports placement

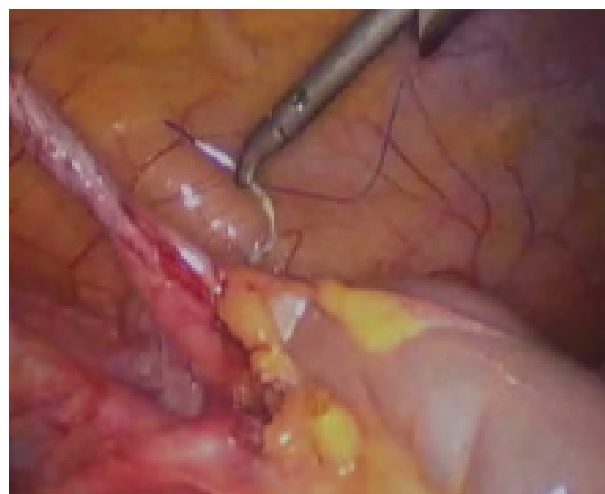



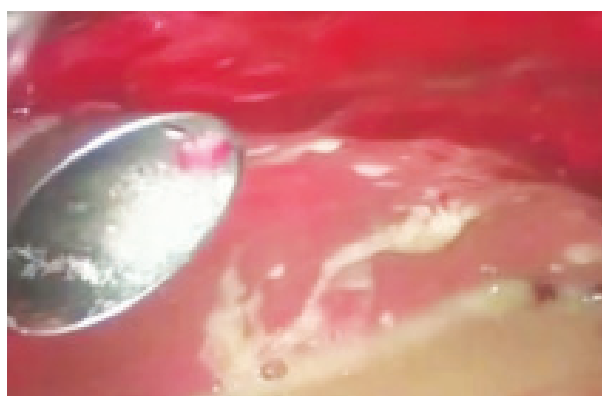**Figure 3.** Ports placement & working replacement



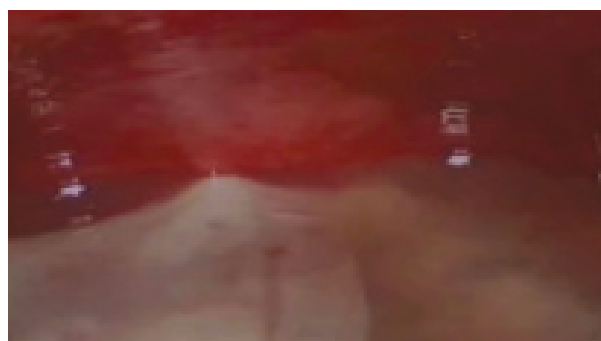
**Figure 6.** Dissection of gangrenous appendicitis



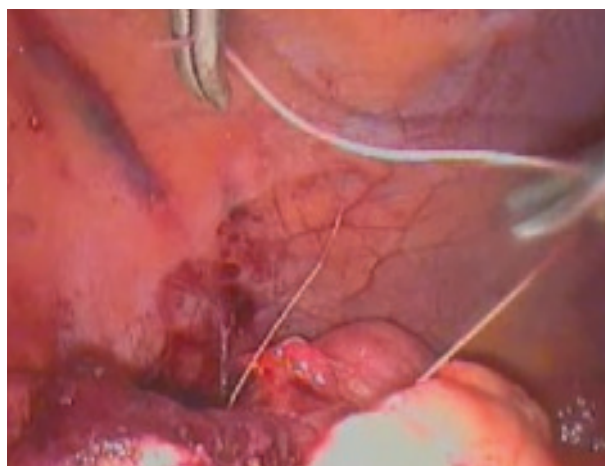
**Figure 4.** Stump control with atraumatic suture



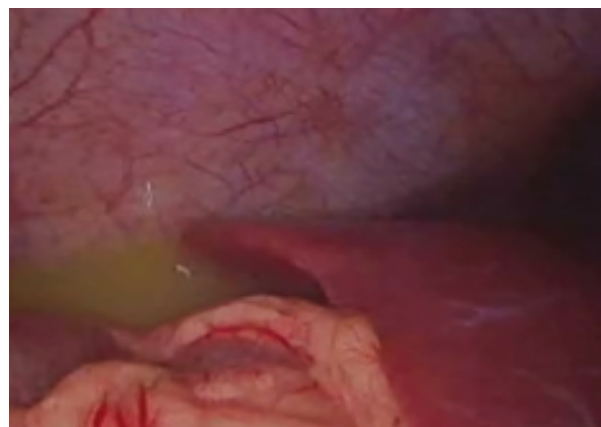**Figure 7.** Burst appendicitis with severe sepsis



**Figure 8.** Burst appendicitis with loculated collection



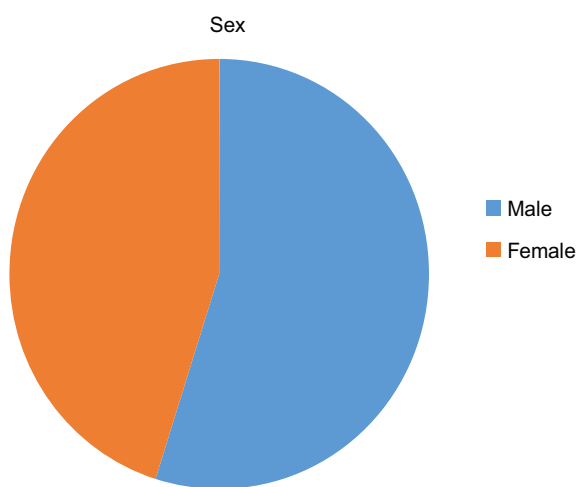
**Figure 5.** Stump control with traumatic suture



**Figure 9.** Burst appendicitis with subhepatic collection

**Results:**

This study includes 90 patients in whom laparoscopic appendectomy & peritoneal lavage was performed. Age distribution of the study is 3-90 years, mean 17 years. Male is predominant, 46. Duration varies 30-120 minutes, mean 70 minutes. Hospital stay varies from 48-96 hours, mean 64 hours. There were 8 complications- single (5, 5.55%) or multiple (3, 3.33%) port infections, paralytic ileus (2, 2.22%) and diarrhea (1, 1.11%), port TB was identified (3, 3.33%) cases among the port infection. Conversion was 1 (1.11%) for controlling haemorrhage of burst appendicitis. All complications are managed conservatively.



**Figure 10.** Sex distribution

**Table-2.** Mode of presentation

Mode of presentation	Number of patient	%
Classical	64	71.11
Atypical	20	22.22
Recurrent/Chronic	6	6.66

**Table-3.** Complications

Complications	Number of patient	%
Single port infection	5	5.55
Multiple port infection	3	3.33
Paralytic ileus	2	2.22
Port TB	3	3.33
Diarrhea	1	1.11
Conversion	1	1.11

**Discussion :**

The diagnosis of appendicitis tests the clinical judgment of the surgeon<sup>9,13,15</sup>. It is almost entirely clinical. Lab investigation and radiological reports are useful for exclusion of other diagnoses. Once inflamed the vermiform appendix is best removed surgically without undue delay, which might be life-threatening for the patient.

Modern radiographic techniques have come a long way since their first discovery and play a vital role in diagnosis of diseases. But the diagnosis of appendicitis is still largely clinical<sup>1,5,6,8,16</sup>. The art of surgical diagnosis comes into play<sup>17,18</sup>. The keen observation skills and experience of the surgeon is more accurate and effective than the lab and radiological reports<sup>19,20</sup>.

Which method of surgery to be undertaken – remains an unsolved issue<sup>21</sup>. In an endeavor to seek answer to this question- whether laparoscopic appendectomy can become the preferred option and infact the gold standard over the conventional open appendectomy<sup>22,23</sup>, We performed this study. Three port technique was used (10mm port in the supraumbilicus for the camera, two 5mm ports in the left iliac fossa and supra-pubic as the working ports). Carbon dioxide was used to create pneumoperitoneum<sup>24</sup>. 90 patients diagnosed with perforated appendicitis and had undergone laparoscopic appendectomy with peritoneal lavage were evaluated on several issues and the results published.

Procedure related outcomes were inspiring<sup>25</sup>. Duration varies 30-120 minutes, mean 70 minutes, suggesting that it is not a time consuming procedure. In a study by Biondi,<sup>26,27</sup> et al the duration was 54±14.4 minutes, while in the study of Katkhouda<sup>28</sup> et al 2005 it was 80minutes (average), in the study of Costa-Navarro<sup>29</sup> et al 2013 it was 25 minutes (average) and 52.2 minutes( average) for Minutolo<sup>30</sup> et al 2014.

In a study conducted by Biondi<sup>31</sup> et al 2016, the duration for hospital stay was 2.7±2.5 days, in case of Costa-Navarro<sup>32</sup> et al 2013 it was 2.6 days(average) and in our study, the average duration of hospital stay was 64 hours, where the shortest was 48 hours and the longest being 94 hours.

There were 8 complications- single (5, 5.55%) or multiple (3, 3.33%) port infections, paralytic ileus (2, 2.22%) and diarrhea (1, 1.11%), port TB was identified

(3, 3.33%) cases among the port infection. Conversion was 1 ( 1.11%) for controlling haemorrhage of burst appendicitis. There was no mortality. If we compare the results with similar studies we see that rate of wound infection was 1.4% in case of Biondi<sup>33</sup> et al 2016, 17% in the study of Katkhouda<sup>34</sup> et al 2005, 5% in the study of Costa-Navarro<sup>35</sup> et al 2013 and 2.9% in the study of Minutolo<sup>36</sup> et al 2014.

Now a days laparoscopic appendectomy(LA) is the gold standard surgical option in many countries. LA has advantages over the open appendicectomy regarding its diagnosis, exclusion of additional pathology, surgical treatment, wound infection (port infection) and hospital stay<sup>28-31,37</sup>.

In Bangladesh, the use of laparoscopy is not widespread. Hospitals in the big cities are the frequent users. In the smaller cities and rural areas, there is almost no provision of laparoscopic surgery. Financial constraints and lack of expertise are the main reasons behind this discrepancy<sup>38</sup>. The learning curve of basic laparoscopic skills is not very steep. But due to the lack of teaching centers, the widespread has not been satisfactory. The cost-affectivity of laparoscopic procedures is a big issue in a country like Bangladesh. Appendicectomy is a widely performed operation in the hospitals of Bangladesh<sup>27,28</sup>, both in the private and public sector. It is a big opportunity for the surgeons who have the access to laparoscopic setup to apply their knowledge and heighten their skills by performing laparoscopic appendicectomy and eventually gaining enough skills to manage the complications of appendicitis well. Despite all the constraints, the results of the study have been inspiring and is an indicator that laparoscopic appendicectomy may perhaps become the treatment modality of choice for acute appendicitis and its complications.<sup>27,39</sup>

Conclusion: Total management of perforated appendicitis by laparoscopy has been proved to be satisfactory and the results are comparable with other studies on similar topics. It is achievable, feasible & can be done by expert, as well as beginner surgeons if properly trained up. Similar studies may be undertaken in various institutions including those where facilities are limited and in the specialized institutions and the results may be compared to come to consensus. Now it is considered as standard procedure.

### Conflict of interest :

There is no potential conflict of interest with respect to the study, authorship and/or publication of this paper.

### References :

1. Williams, Norman S., et al. *Bailey & Love's Short Practice of Surgery*. 27th ed., vol. 2 2, CRC Press, 2017.
2. Burnand, K. and Browse, N. (2015). Browse's introduction to the symptoms & signs of surgical disease. 5th ed. Boca Raton, FL: CRC Press, Taylor & Francis Group, pp.481-533.
3. Kirk, R., Novell, R., Baker, D. and Goddard, N. (2013). *Kirk's general surgical operations*. 6th ed. Edinburgh: Churchill Livingstone, Elsevier, pp.93-101.
4. Moran, B., Hollingshead, J. and Farquharson, M. (n.d.). *Farquharson's textbook of operative general surgery*. 10th ed. Boca Raton: CRC Press
5. Cuschieri, A. and Hanna, G. (2015). *Essential surgical practice*. 5th ed. Boca Raton: CRC Press.
6. Brunicaudi, F. (2015). *Schwartz's Principles of Surgery*. 10th ed. New York: McGraw-Hill.
7. Zinner, M and Ashley, S (2013). *Maingot's Abdominal Operations, 12<sup>th</sup> Edition*. 12<sup>th</sup> ed. New York: McGraw-Hill Medical.
8. Lumley, J., D'Cruz, A., Hoballah, J. and Scott-Conner, C. (2016). *Hamilton Bailey's Demonstration of Physical Signs in Clinical Surgery*. 19th ed. Boca Raton: CRC Press
9. Hughes T.M., Luu M.B. (2015) Acute Appendicitis. In: Saclarides T., Myers J., Millikan K. (eds) Common Surgical Diseases. Springer, New York, NY
10. Kollár, D., McCartan, D.P., Bourke, M. et al. *World J Surg* (2015) 39: 112. <https://doi.org/10.1007/s00268-014-2822-6>
11. Ng, S., Fleming, F.J., O'Connor, M. et al. *Ir J Med Sci* (2008) 177: 415. <https://doi.org/10.1007/s11845-008-0207-2>
12. Wiwanitkit, V. *Langenbecks Arch Surg* (2011) 396: 867. <https://doi.org/10.1007/s00423-010-0670-x>
13. Paulson EK, Kalady MF, Pappas TN: Clinical practice. Suspected appendicitis. *N Engl J Med*. 2003, 348: 236-242. 10.1056/NEJMcp013351.

14. Reilly BM, Evans AT: Translating clinical research into clinical practice: impact of using prediction rules to make decisions. *Ann Intern Med.* 2006, 144: 201-209.
15. Howell JM, Eddy OL, Lukens TW, Thiessen ME, Weingart SD, Decker WW: Clinical policy: critical issues in the evaluation and management of emergency department patients with suspected appendicitis. *Ann Emerg Med.* 2010, 55: 71-116. 10.1016/j.annemergmed.2009.10.004.
16. Humes, D. (2006). Acute appendicitis. *BMJ*, 333(7567), pp.530-534.
17. Souza IM, Nunes DA, Massuqueto CM, Veiga MA, Tamada H. *International Journal of Surgery Case Reports.* 2017 Oct 4; 41: 5-8
18. Gockel I, Jäger F, Shah S, Steinmetz C, Junginger T. *Chirurg.* 2007 Sep; 78(9):840-2.
19. Yildiz M, Karakayali AS, Ozer S, Ozer H, Demir A, Kaptanoglu B. *World J Gastroenterol.* 2007 Jul 14; 13(26):3631-3.
20. Cheng Y, Zhou S, Zhou R, Lu J, Wu S, Xiong X, Ye H, Lin Y, Wu T, Cheng N. *Cochrane Database Syst Rev.* 2015 Feb 7; (2):CD010168. Epub 2015 Feb 7.
21. Singal R, Gupta S, Mittal A, Gupta S, Singh M, Dalal AK, Goyal S, Singh B. *Acta Med Indones.* 2012 Jan; 44(1):53-6.
22. Beerle C, Gelpke H, Breitenstein S, Staerkle RF. *J Med Case Rep.* 2016 Dec 1; 10(1):331. Epub 2016 Dec 1.
23. Hsieh CH, Wang YC, Yang HR, Chung PK, Jeng LB, Chen RJ. *World J Gastroenterol.* 2006 Jan 21; 12(3):496-9.
24. Otowa Y, Sumi Y, Kanaji S, Kanemitsu K, Yamashita K, Imanishi T, Nakamura T, Suzuki S, Tanaka K, Kakeji Y. *World J Gastroenterol.* 2014 Jul 7; 20(25):8317-9.
25. ISLAM, Md Khairul et al. Diagnostic role of Ultrasonography in acute appendicitis. *Journal of Armed Forces Medical College, Bangladesh, [S.I.], v. 10, n. 1, p. 45-49, apr. 2015. ISSN 1992-5743.*
26. MALHOTRA, Mohinder Kumar et al. Is diagnostic accuracy of Alvarado scoring feasible in acute surgery for management of acute appendicitis?. *Bangladesh Journal of Medical Science, [S.I.], v. 15, n. 2, p. 166-171, aug. 2016. ISSN 2076-0299.*
27. Hannan, M. (2014). Laparoscopic Appendectomy in Children: Experience in a Single Centre in Chittagong, Bangladesh. *Minimally Invasive Surgery*, 2014, pp.1-4.
28. Hannan MJ, Hoque MM. Laparoscopic submucosal appendectomy for difficult and adherent cases: a novel technique to minimize complications. *Journal of Laparoendoscopic & Advanced Surgical Techniques.* 2012;22(10):1017–1020.
29. Moazzez A, Mason RJ, Katkhouda N. Laparoscopic appendectomy: new concepts. *World Journal of Surgery.* 2011;35(7): 1515–1518.
30. Ingraham AM, Cohen ME, Bilimoria KY, Pritts TA, Ko CY, Esposito TJ. Comparison of outcomes after laparoscopic versus open appendectomy for acute appendicitis at 222 ACS NSQIP hospitals. *Surgery.* 2010;148(4):625–637.
31. Chung RS, Rowland DY, Li P, Diaz J. A meta-analysis of randomized controlled trials of laparoscopic versus conventional appendectomy. *American Journal of Surgery.* 1999;177(3):250–256.
32. Rahman, M.M., Khalil, M., Rahman, H., Mannan, S., Sultana, S.Z. and Ahmed, S., 2006. Anatomical Positions of Vermiform Appendix in Bangladeshi People. *Journal of Bangladesh Society of Physiologist, [S.I.], v. 1, p. 5-9, Feb. 2008. ISSN 1995-1213.*
33. Rahman, M.M., Khalil, M., Khalil, M., Hussain, A., Rahman, H.R., Mannan, S., Sultana, S.Z. and Ahamed, M.S., 2007. Length of human vermiform appendix in Bangladeshi people. *Journal of Bangladesh Society of Physiologist*, 2, pp.13-16.
34. Bakar, S.M.A., Shamim, M., Alam, G.M. and Sarwar, M., 2013. Negative correlation between age of subjects and length of the appendix in Bangladeshi males. *Archives of medical science: AMS*, 9(1), p.55.
35. Biondi, A., Stefano, C. D., Ferrara, F., Bellia, A., Vacante, M., & Piazza, L. (2016). Laparoscopic

- versus open appendectomy: a retrospective cohort study assessing outcomes and cost-effectiveness. *World Journal of Emergency Surgery*, 11(1). doi:10.1186/s13017-016-0102-5
36. Katkhouda N, Mason RJ, Towfigh S, Gevorgyan A, Essani R. Laparoscopic versus open appendectomy: a prospective randomized double-blind study. *Annals of surgery*. 2005 Sep;242(3):439.
  37. Wang CC, Tu CC, Wang PC, Lin HC, Wei PL. Outcome comparison between laparoscopic and open appendectomy: evidence from a nationwide population-based study. *PLoS One*. 2013 Jul 12;8(7):e68662.
  38. Minutolo V, Licciardello A, Di Stefano B, Arena M, Arena G, Antonacci V. Outcomes and cost analysis of laparoscopic versus open appendectomy for treatment of acute appendicitis: 4-years experience in a district hospital. *BMC surgery*. 2014 Dec;14(1):14.
  39. Costa-Navarro D, Jiménez-Fuertes M, Illán-Riquelme A. Laparoscopic appendectomy: quality care and cost-effectiveness for today's economy. *World Journal of Emergency Surgery*. 2013 Dec;8(1):45.