

Role of Fine Needle Aspiration Cytology (FNAC) in the Differential Diagnosis of Neck Swelling: A Hospital Based Study

Md. Hasan Hafijur Rahman,¹ Shamsuddin Ahmed,² Md. Abdur Razzak,³ Jarin Tasnim Stella,⁴ Shamsun Nahar,⁵ Lovely Adhikary⁶

1. Assistant Professor
Department of ENT and Head-Neck Surgery
Ad-din Sakina Women's Medical College
Dhaka
2. Assistant Professor
Department of General Surgery
Ad-din Momin Medical College
Dhaka
3. Junior Consultant
Department of ENT and Head-Neck
Surgery
Rangpur Medical College
4. Lecturer
Department of Forensic Medicine
Ad-din Women's Medical College
Dhaka
5. Assistant Professor
Department of Surgery
Ad-din Momin Medical College
Dhaka
6. Assistant Professor
Department of Pathology
Ad-din Sakina Women's Medical College
Jashore

Correspondence to:

Md. Hasan Hafijur Rahman
Assistant Professor
Department of ENT and Head-Neck Surgery
Ad-din Sakina Women's Medical College
Dhaka
Email: hafij.kmc.123@gmail.com



Submission Date : 02 Feb 2026
Accepted Date : 03 March 2026
Published Date : 30 March 2026
DOI: <https://doi.org/10.3329/jrjpmc.v11i1.90061>

Abstract

Background:

Both neck swellings are usually due to lymph nodes, thyroid, paralympathic, or soft tissue swellings that can vary from inflammatory to malignancies, which are manifestations of head and neck malignancies in adults. FNAC, USG-guided FNAC, and ultrasonography are the major diagnostic modalities in hematologic swellings of lymph nodes that are accurate to the extent of 82–96% sensitivity and in nonthyroid swellings of the neck that are accurate for their sensitivity of 93% and specificity of 72%. This study aims to investigate the cytological distribution of FNAC in 61 cases.

Objective:

To assess the diagnostic efficacy, accuracy, and cytological findings of Fine Needle Aspiration Cytology (FNAC) in case of neck swellings and correlation of cytological results with demographic details and site-wise distribution for appropriate patient care.

Methods:

This retrospective study included 61 patients with head and neck swellings from the Department of ENT, Ad-Din Sakina Hospital, between December 2024 and March 2025; FNAC was performed in all cases under strict aseptic conditions using a 23-gauge needle and 10-ml syringe, with aspirated material stained by MGG, H&E, and Papanicolaou methods, Z-N staining applied for suspected tuberculous or purulent cases, and repeat FNAC conducted when initial samples were inadequate.

Results:

Among 61 FNAC-evaluated neck swellings, thyroid lesions were most common (42.6%), followed by neck and parotid swellings (13.1% each), with female predominance (~66%) and peak incidence in middle age (45–59 years; 26.2%); cytology showed mainly benign and inflammatory lesions predominantly nodular goiter and lymphadenitis (14.8% each) with fewer malignant cases, highlighting FNAC's effectiveness in characterizing the anatomical and cytological spectrum.

Conclusion:

Neck swellings predominantly involve the thyroid gland with female and mid-life predominance, are largely benign with inflammatory and benign neoplastic lesions forming the majority despite a notable malignant proportion, and FNAC proves to be a precise, minimally invasive, and indispensable primary diagnostic tool enabling reliable benign–malignant differentiation and optimal clinical management.

Keywords: FNAC, Neck swellings, Cytological diagnosis

Citation: Rahman MHH, Ahmed S, Razzak MA, Stella JT, Nahar S, Adhikary L. Role of Fine Needle Aspiration Cytology (FNAC) in the Differential Diagnosis of Neck Swelling: A Hospital Based Study. *J Rang Med Col.* 2026 Mar; 11(1):208-212. doi:<https://doi.org/10.3329/jrjpmc.v11i1.90061>

Introduction:

A swelling in the neck is a very common presentation in a patient's case and can pose a challenge to the physician in terms of differential diagnoses attributed to the complex anatomy in

the neck with its high concentration of lymph nodes, thyroid, salivary glands, blood vessels, nerves, and developmental abnormalities that can develop into swellings.¹ The differential diagnoses in this swelling can range from infectious to

inflammatory diseases to tumors. These swellings can also develop from “lymph nodes, thyroid, salivary glands, or soft tissues.”² In an adult case, this swelling has been described as a leading symptom to an important underlying disease. It can often present as a cancer of the head and neck when this swelling occurs in an adult’s case, especially when the tumor’s origin is unknown.³ Fine Needle Aspiration Cytology (FNAC) has developed as the mainstay and initial investigative modality for the assessment of neck swellings.⁴ It is a short procedure, performed on an outpatient basis, where cell material is aspirated through a fine-caliber needle, analyzed cytologically, and has gained widespread acceptance because of its ease, rapid turnover time, cost effectiveness, as well as excellent diagnostic yield.⁵ The main use of FNAC lies in discriminating between infectious and/or inflammatory swellings and malignancy, as well as benign versus malignant lesions, which impacts significantly on patient management.⁶ FNAC is an essential component in the diagnostic work-up for neck swellings. Ultrasonography has become the preferred imaging tool for guiding FNAC because it can assist in localization and evaluation of lesions, hence increasing the yield of FNAC.⁷ FNAC can be used to evaluate a vast range of pathologies in neck swellings, the most common being thyroid swellings, pathologies in the lymph nodes, and salivary gland pathologies.⁸ FNAC has played a crucial role in diagnosing certain pathologies such as inflammatory thyroid diseases, congenital swellings in the neck, salivary gland tumors, and metastatic diseases in the lymph nodes.⁹ FNAC is quite helpful in assessing swellings in the neck region. Regarding lymph node swellings, the accuracy of FNAC is between 82% and 96%, and that makes it the test of choice in this context.¹⁰ Regarding non-thyroid swellings in the neck region, the sensitivity of FNAC is 93%, with a specificity of 72%, and that makes it an excellent test in a variety of situations.⁶ It is quite helpful in separating cases with inflammation and those with malignancies, and that is quite useful in giving the right treatment to the right patient at the right time. FNAC is not restricted to swellings in the lymph nodes. It can be quite helpful in cases related to the thyroid gland or the salivary glands.¹¹ It can be quite helpful in cases of pleomorphic adenomas in the parotid gland.¹² It can be quite helpful in children also with

swellings in the neck.¹³ It is better than surgery in cases where it may not be necessary. Of course, in some cases, there can be a problem of “false negatives” or “false positives,” mostly when the sample obtained isn’t of good quality.¹⁴ Although this is why one still needs to check the results of the FNAC along with personal observations. In some cases, if one can’t determine, then again, one can either do the “FNAC again” or an “excision biopsy.” Although in most ways, “FNAC helps in making most of the plans of treatment based on patients.” If something appears benign, then most patients don’t need surgery. And if something appears malignant, then it helps doctors in planning treatment.¹⁵ Within this scenario, the current study also retrospectively examined the cytological findings of 61 successive cases of neck swellings diagnosed through FNAC. The objective of the study is to examine the diagnostic scope and distribution of neck swellings, correlate the findings of cytological diagnosis with the demographics and location of patients, and highlight their replaceable role of FNAC in the diagnosis and management of neck swellings. By doing so, the efficacy of FNAC as a rapid, accurate, and successful approach to decrease morbidity related to excisional biopsies is also demonstrated.⁴

Methods:

This retrospective study carried out in the Department of ENT in Ad-Din Sakina Hospital on 61 patients who presented with swellings in the head and neck region during December 2024 and March 2025. Fine needle aspiration cytology was carried out on each of the patients after maintaining complete asepsis using a 23-gauge needle fixed to a 10 ml syringe. Informed consent was obtained in all cases before performing FNAC. Aspirated samples were spread on glass slides and stained for cytopathological examinations using May Grunwald Giemsa (MGG), Hematoxylin and Eosin (H&E), and Papanicolaou (Pap). Ziehl Neelsen stain for acid-fast bacilli (AFB) was further performed on samples in cases preliminarily suspected to be due to tuberculosis and in samples which yielded an aspirate consistent with purulent and/or caseous material.

Results:

The swelling distribution in 61 cases shows that 42.6% were in the thyroid, 13.1% in neck and

parotid areas, and 9.8% and 8.2% in submandibular and cervical lymph nodes, respectively. Other locations were rare (Table-I).

Table-I: Distribution of swellings among the participants (N=61)

Diagnosis	no. (%)	Cumulative %
Thyroid	26(42.6)	42.6
Neck	8(13.1)	55.7
Parotid	8(13.1)	68.9
NeckLN	1(1.6)	70.5
SubmandibularLN	6(9.8)	80.3
Cervical LN	5(8.2)	88.5
Inguinal LN	1(1.6)	90.2
TMJ	1(1.6)	91.8
Post-Ear	1(1.6)	93.4
Submental LN	1(1.6)	95.1
Submandibular LN	1(1.6)	96.7
Post-auric LN	1(1.6)	98.4
Neck+ Thyroid	1(1.6)	100.0
Total	61(100)	

Figure-1 showed that neck swellings are over twice as common in females. This suggests that females are more likely to seek hospital treatment than males.

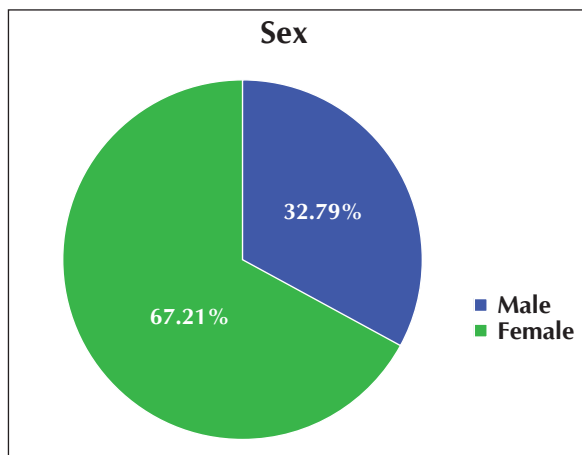


Figure-1: Sex distribution of patients with neck swellings (N=61)

Table-II showed the distribution of cytological diagnoses among study subjects. Nodular goiter or lymphadenitis was the most common diagnosis (9,14.8%), followed by thyroiditis (6, 9.8%).

Colloid goiter, TB lymphadenitis, Pleomorphic adenoma, and Lipoma each had 3 cases (4.9%). Malignant lesions like metastatic carcinoma and Squamous cell carcinoma had 2 cases each (3.3%). Other conditions accounted for single cases. The study indicates that benign, inflammatory conditions are more common than malignant ones.

Table-II: Distribution of cytological diagnosis among the participants (N=61)

Diagnosis	no. (%)	Cumulative %
Nodular goiter	9(14.8)	14.8
Colloid goiter	3(4.9)	19.7
Thyroiditis	6(9.8)	29.5
Lymphadenitis	9(14.8)	44.3
Metastatic CA	2(3.3)	47.5
SCC	2(3.3)	50.8
TB Lymphadenitis	3(4.9)	55.7
Follicular Lesion	2(3.3)	59.0
Follicular Neoplasm	1(1.6)	60.7
PleomorphicAdenoma	3(4.9)	65.6
Sialadenitis	2(3.3)	68.9
Lipoma	3(4.9)	73.8
Hodgkin Lymphoma	2(3.3)	77.0
NHL	1(1.6)	78.7
Warthin Tumor	1(1.6)	80.3
Adenoid Cystic CA	1(1.6)	82.0
Adenomatousgoiter	1(1.6)	83.6
Colloid Cyst	1(1.6)	85.2
Infected cyst	1(1.6)	86.9
Thyroglossal cyst	1(1.6)	88.5
Branchial cyst	1(1.6)	90.2
Dermoid Cyst	1(1.6)	91.8
Abscess	1(1.6)	93.4
Hematoma	1(1.6)	95.1
TB abscess	1(1.6)	96.7
Suspicious Thyroid	1(1.6)	98.4
Sialadenitis +Lymphadenitis	1(1.6)	100
Total	100	

Discussion:

This study involving 61 patients has resulted in important findings in relation to neck swellings that underwent FNAC investigation. Most frequent

localization was associated with thyroid gland, representing 42.6%. Other locations were non-specific neck swellings and parotid gland swellings, both representing 13.1%. Similar findings are also reflected in literature reporting on FNAC as an important tool for evaluation of head and neck lesions.⁸ Frequent identification of involvement of lymph nodes in the submandibular and cervical areas, their classification as reactive, inflammatory, and neoplastic types, is also similar to what has been stated in previous studies. In general, FNAC test has proved to provide diagnostic yield ranging from 82 to 96% in the case of lymph nodes swellings, and therefore considered a gold standard in this respect.¹⁰ It should also be highlighted that in relation to non-thyroidal masses, FNAC is highly valuable from a diagnostic perspective.⁶ In addition, high frequency of females in this study who represented approximately two-thirds of total population was similar to observations reported in other studies where increased prevalence of thyroid diseases and benign goiter or thyroiditis has been shown among women.^{14,15} It can also be highlighted in relation to greater tendency of health seeking behavior observed among females in relation to neck swellings. Most frequently affected age group in this study was adults between 45 and 59 years old, whereas second most frequent age group was adults aged 30 to 44. Pediatric age group represented 19.7% of study population, which is consistent with other studies reporting on efficacy of FNAC in all age groups, even in pediatric patients.^{11,13} It can also be mentioned here that neck swellings are not limited only to adult patients only. From a cytological point of view, most frequent swellings were benign swellings such as nodular goiter, colloid goiter, thyroiditis, and lymphadenitis. This finding was in line with other studies indicating usefulness of FNAC as a technique for distinguishing malignant swellings from benign ones. Thus, FNAC could prevent unnecessary surgery in patients with benign conditions.^{9,15}

Malignant swellings including metastatic carcinoma and squamous cell carcinoma were found in approximately 15 to 20 percent of cases in this study, which is in line with previous studies confirming importance of preoperative diagnosis of malignancies through FNAC test.^{2,4}

It has been shown here that a number of swellings, which included both common swellings such as

colloid goiter and rare swellings such as Warthin tumors and branchial cysts, were encountered in the current study. It proves usefulness of FNAC test for diagnosing thyroid swellings, lymph node swellings, and salivary gland lesions.^{8,12} It has been reported that FNAC has high efficacy in diagnosing pleomorphic adenomas of salivary glands.¹²

Despite limitations of small sample size in this study without appropriate histopathological confirmation, findings of the current study are in line with those reported in other studies, proving usefulness of FNAC in relation to neck swellings.^{5,9}

Conclusion:

The paper characterizes the presentation of neck swellings in a clinical community, reaffirming the thyroid gland as the commonest location, with a definitive female predilection and a strong tendency for these presentations in mid-life. The cytological spectrum is overwhelmingly benign; inflammatory conditions and benign neoplasms account for the predominant number of cases, although the fact that a significant proportion has been identified to be malignant serves to emphasize just how important it is to evaluate them. FNAC turns out to be a crucial, precise, and minimally invasive primary diagnostic agent in the management algorithm of neck masses. Its capacity to distinguish reliably between benign and malignant lesions makes it greatly helpful in the effective management of the situation and, in effect, the optimization of outcomes. It is imperative to encourage the utilization of FNAC in the management of the clinical situation in question.

References:

1. Amedee RG, Dhurandhar NR. Fine-needle aspiration biopsy. *Laryngoscope*. 2001 Sep; 111(9):1551-7. doi: 10.1097/00005537-200109000-00011.
2. Fulciniti F, Califano L, Zupi A, Vetrani A. Accuracy of fine needle aspiration biopsy in head and neck tumors. *J Oral Maxillofac Surg*. 1997 Oct;55(10):1094-7. doi: 10.1016/s0278-2391(97)90288-3.
3. Smallman LA, Young JA, Oates J, Proops DW, Johnson AP. Fine needle aspiration cytology in the management ENT of patients. *J Laryngol Otol*. 1988 Oct;102(10):909-13. doi: 10.1017/s0022215100106796..
4. Florentine BD, Staymates B, Rabadi M, Barstis J, Black A; Cancer Committee of the Henry

- Mayo Newhall Memorial Hospital. The reliability of fine-needle aspiration biopsy as the initial diagnostic procedure for palpable masses: a 4-year experience of 730 patients from a community hospital-based outpatient aspiration biopsy clinic. *Cancer*. 2006 Jul 15;107(2):406-16. doi: 10.1002/cncr.21976.
5. Ahmad T, Naeem M, Ahmad S, Samad A, Nasir A. Fine needle aspiration cytology (FNAC) and neck swellings in the surgical outpatient. *J Ayub Med Coll Abbottabad*. 2008 Jul-Sep;20(3):30-2.
 6. Ishar T, Gupta RK, Khajuria A. Role of FNAC in diagnosis of non-thyroidal head and neck lesions. *JK Science*. 2012;14(1):9.
 7. Khetrpal S, Jetley S, Jairajpuri Z, Rana S, Kohli S. FNAC of head & neck lesions and its utility in clinical diagnosis: a study of 290 cases. *Natl J Med Res*. 2015 Mar 31;5(01):33-8. Available from: <https://njmr.in/index.php/file/article/view/339>
 8. Layfield LJ, Glasgow BJ, Cramer H. *Cytopathology of the Head and Neck*. ASCP Press, American Society of Clinical Pathologists. 2007.
 9. Pawde Y, Kathale S. Fine needle aspiration cytology as a diagnostic tool in head and neck lesions. *Journal of Evolution of Medical and Dental Sciences*. 2014;3(45):8.
 10. Swamy GG, Singh A, Ahuja JM, Satyanarayana N. Accuracy of fine needle aspiration cytology in the diagnosis of palpable head and neck masses in a tertiary health care center. *Journal of College of Medical Sciences–Nepal*. 2012 Aug;6(4):19–25. doi:10.3126/jcmsn.v6i4.6721
 11. Ramadan HH, Wax MK, Boyd CB. Fine-needle aspiration of head and neck masses in children. *Am J Otolaryngol*. 1997 Nov-Dec;18(6):400-4. doi: 10.1016/s0196-0709(97)90061-2.
 12. Balakrishnan K, Castling B, McMahon J, Imrie J, Feeley KM, Parker AJ, et al. Fine needle aspiration cytology in the management of a parotid mass: a two centre retrospective study. *Surgeon*. 2005 Apr;3(2):67-72. doi: 10.1016/s1479-666x(05)80064-2.
 13. Costas A, Castro P, Martini-Granizo R, Monje F, Marrayn C, Amigo A. Fine needle aspiration biopsy (FNAB) for lesions of the salivary glands. *Br J Oral Maxillofac Surg*. 2000 Oct;38(5):539-42. doi: 10.1054/bjom.2000.0465.
 14. Amrikachi M, Ramzy I, Rubinfeld S, Wheeler TM. Accuracy of fine-needle aspiration of thyroid. *Arch Pathol Lab Med*. 2001 Apr; 125(4):484-8. doi: 10.5858/2001-125-0484-AOFNAO.
 15. Ullah S, Mumtaz N, Khan A. Role of Fine Needle Aspiration Cytology (FNAC) in the Diagnosis of Thyroid Swellings. *J Postgrad Med Inst*. 2011 Sep. 28;18(2). <https://www.jpmi.org.pk/index.php/jpmi/article/view/874>