



## Case Report

# Broad webbed penis with hypospadias: A rare combination

Islam M N , Chowdhury P

### Abstract

Webbed penis is rare condition and may be congenital or acquired in aetiology. Treatments are indicated for reasons such as cosmetic concerns, erection pain or associated with other anomalies. We report a case of 22 years boy having broad webbed penis with penoscrotal

hypospadias with severe chordee and small penis. Deformity was corrected by excision of abnormal dartos tissue attached to penis and skin between two folds for urethroplasty.

**Keywords:** Webbed penis, hypospadias

1. Md. Nazrul Islam  
Associate Professor  
Department of Paediatric Surgery  
Bangladesh Medical University-BMU
2. Pravin Chaudhary  
Consultant  
Paediatric Surgery  
Bangladesh Medical University-BMU

### Case report

A 22 years old boy presented with micturition from under surface of penis since birth with normal urine flow and small penis. On examination we found urethral opening at penoscrotal region, meatus adequate, severe chordee, small penis, glans conical, dorsal hooding present, urethral plate adequate and both testes are present in scrotum. There was two skin folds extending from both lateral sides of prepuce to scrotum, obscuring penoscrotal angle, urethral meatus was buried in skin fold. His youngest brother also has same problem. Ultrasonography of whole abdomen and serum testosterone level are normal. Orthoplasty was done by excision abnormal scrotal dartos bands attached to the penile shaft. Urethroplasty was done in two layers. Inner layer by skin lying between two folds as flap on 10 Fr. feeding tube and outer layer by preputial skin. Urethral catheter was removed on 10th POD. No post-operative fistula developed.

### Introduction

Webbed penis is concealed penis where scrotal skin extends too high on the ventrum of penis forming a web or fold between the penis and scrotum. It obscures penoscrotal angle. This is typically caused by aberrant dartos bands that bind the penile skin to the scrotum's surface. This

causes the obliteration of ventral penoscrotal angle and results in short penis appearance [1]. Hypospadias is one of the most common congenital defects of male external genitalia but combination of hypospadias with webbed penis is rare condition.

### Discussion

Webbed penis is caused by abnormal dartos bands anchoring to the ventral penile shaft with obliteration of the penoscrotal angle which occurs because of partial failure of the posterior migration of the labioscrotal folds with faulty penoscrotal fusion [2]. Because of obscured penoscrotal angle, a webbed penis may appear small despite the normal size of penile phallus. So, a webbed penis is one type of concealed penis or inconspicuous

### Correspondence to: Md. Nazrul Islam

Associate Professor, Department of Pediatric Surgery  
Bangabandhu Sheikh Mujib Medical University, Dhaka  
Bangladesh. Email: niakash@gmail.com

penis. According to the classification system proposed by Maizels et al., inconspicuous penis includes the buried penis, webbed penis, trapped penis, and micropenis. Webbed penis is usually asymptomatic. Due to the obscured penoscrotal angle by the web, the penis appears small and concealed [3,4].

Webbed penis is classified into primary and secondary; primary is further subdivided into simple and compound. Compound webbed penis is divided into Type 1 (Web with prepenile scrotum), Type 2 (web with penile curvature) and Type 3 (Broad web) [5]. A secondary webbed penis is defined as a postcircumcised penis in obese children or a concealed penis [3]. This anomaly infrequently exists with other anomalies, such as penile torsion, penile curvature, or hypospadias. Many authors have proposed surgical correction of this anomaly using Heineke-Mikulicz scrotoplasty, V-Y, double V, and Z-plasty. However, of these techniques, there is no available single technique suitable for correction of different grades of congenital webbed penis [6,7]. The ultimate goal of treating a webbed penis is to separate the penis from the scrotum, removing the web entirely and increasing the ventral penile skin length [3]. Our report is unique because broad webbed penis is associated with penoscrotal hypospadias. Modified Byars' flap techniques were performed where prepuce was used as flap to form neourethra without incising dorsal preputial skin vertically into two halves [8].

### Conclusion

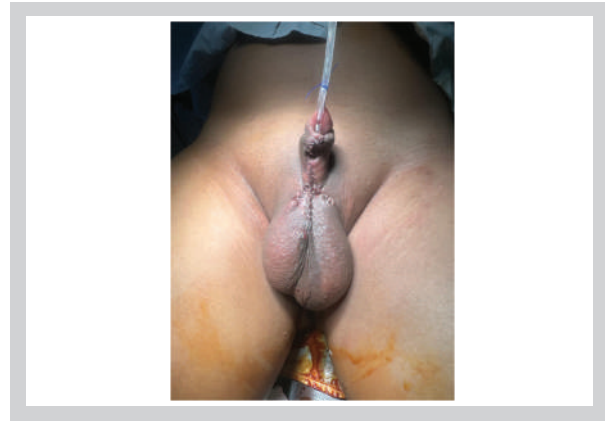

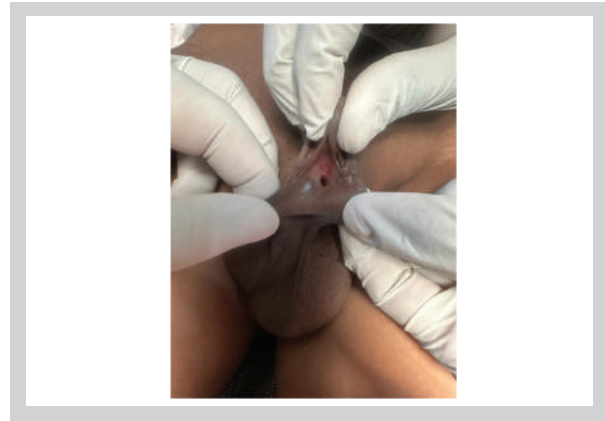

Broad webbed penis associated with hypospadias is very uncommon congenital anomaly. Treatment is functionally and cosmetically acceptable penis.

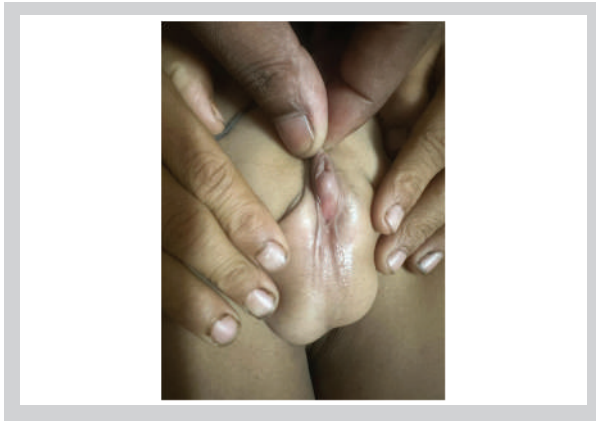
### Financial support and sponsorship

No

### Conflicts of interest

There are no conflicts of interest.





### References

1. Srinivasan AK, Palmer LS, Palmer JS. Inconspicuous penis. *The Scientific World JOURNAL*. 2011; 11:2559–64.
2. Negm M, Nagla S, Shalaby R, Halawa NA. Congenital webbed penis: Surgical outcomes of a simplified technique. *Journal of Pediatric Urology*. 2021 Dec 1;17(6):813-e1.
3. Chao TC, Shei-Dei Yang S, Chang SJ, Lin CD. Webbed penis: etiology, symptoms, surgical treatments, and outcomes. *Urological Science*. 2020 Sep 1;31(5):200-5.
4. Maizels M, Zaontz M, Donovan J, Bushnick PN, Firlit CF. Surgical correction of the buried penis: Description of a classification system and a technique to correct the disorder. *J Urol*1986;136:268-71.
5. El-Koutby M, El Gohary MA. Webbed penis: A new classification. *Journal of Indian Association of Pediatric Surgeons*. 2010 Apr;15(2):50.
6. Dilley AV, Currie BG. Webbed penis. *PediatrSurg Int* 1999; 15(5e6):447e8. <https://doi.org/10.1007/s003830050631>. PMID: 10415318.
7. Chang SJ, Liu SP, Hsieh JT. Correcting penoscrotal web with the VY advancement technique. *J Sex Med* 2008;5(1):249e50. <https://doi.org/10.1111/j.1743-6109.2007.00647.x>. PMID: 17971100.
8. Byars LT. Functional restoration of hypospadias deformities; with a report of 60 completed cases. *SurgGynecolObstet* 1951; 92: 149–154.