



*Original Article*

## Location of Anal Dimple and Its Positional Alignment with the Caudal Termination of the Striated Muscle Complex in Patients with Anorectal Malformations

Wafa F<sup>1</sup>, Farooq M A A<sup>2</sup>, Chowdhury T A<sup>3</sup>, Chowdhury T K<sup>4\*</sup>

### Abstract

**Background:** In children with anorectal malformations (ARM), the midline perineal skin feature known as the anal dimple (AD) is commonly used as a surface landmark to guide surgical placement of the neoanus. The striated muscle complex (SMC), vital for continence, is presumed to align with this dimple and misalignment may lead to poor functional outcome such as incontinence. This study was conducted to find out whether the location of the SMC correlate with AD in patients with ARM.

**Methods:** This cross-sectional study included 30 ARM patients undergoing various anorectal procedures. Intraoperatively, the boundaries of the AD and SMC were marked, and distances between centers (C-C) and lengths of AD (A-B) and SMC (A-B) were recorded using Vernier calipers.

**Results:** Mean age was 16 months and male to female

ratio 2:1. Recto-bulbar urethral fistula was predominant in male and vestibular fistula in female. In majority (80%) of the cases, SMC was posterior to AD. Male had more posterior location whereas female had more anterior location of SMC in relation to AD. Distance between the center of AD and center of SMC (C-C) was found higher in the recto-bulbar urethral fistula followed by the recto-vesical fistula in comparison with perineal and vestibular fistula ( $F= 8.22, p= 0.00$ ). Mean (C-C) displacement was 3.4 mm. Length of AD, SMC and C-C weakly correlated with each other.

**Conclusion:** The anatomical location of the SMC does not consistently match the AD. Reliance on the AD alone may risk misplacement of the neoanus, suggesting that intraoperative SMC visualization is crucial.

**Key words:** Anorectal malformation, striated muscle complex, anal dimple, anooplasty

1. Fahmida Wafa  
Medical Officer, Sadar Upazilla Health Office  
Narayganj, Dhaka
2. Md Abdullah ALFarooq  
Associate Professor, Department of Pediatric Surgery  
Chittagong Medical College and Hospital
3. Tahmina Akhter Chowdhury  
Associate Professor, Paediatric Urology, Dept. of Pediatric Surgery  
Chittagong Medical College and Hospital
4. Tanvir Kabir Chowdhury  
Associate Professor, Paediatric Urology, Dept. of Pediatric Surgery  
Chittagong Medical College and Hospital

### Correspondence to: Dr. Tanvir Kabir Chowdhury

Associate Professor, Paediatric Urology  
Department of Pediatric Surgery  
Chittagong Medical College and Hospital  
Cell: 01771477766, E-mail: [ivan\\_tanvir@yahoo.com](mailto:ivan_tanvir@yahoo.com)

### What is Already Known on This Topic

- ⇒ In patients with anorectal malformations neoanus should be placed within muscle complex to achieve a good continence mechanism.
- ⇒ Pediatric surgeons use muscle stimulator to locate the region of maximum muscle contraction to decide upon the site of neoanus and usually places marking along the anal dimple.

### What This Study Adds

- ⇒ This study shows the variability in anatomical alignment between AD and SMC.
- ⇒ It also observes gender-related trends: posterior SMC in males, anterior in females.

### How This Study Might Affect Research, Practice or Policy

- ⇒ This study puts emphasis on visual localization of muscle complex as this may poorly correlate with anal

dimple. Direct visual localisation is not always performed during laparoscopy assisted anooplasty procedures where a small perineal incision is given along the proposed anus based on location of anal dimple and muscle stimulation. As muscle stimulators are not available in many resource-limited centres, findings of this study will put valuable insight into planning placement of neoanus in ARM patients.

### Introduction

Goal of surgical reconstruction for anorectal malformations (ARM) is to achieve good bowel and urinary function, as well as the ability of children to lead a healthy life.<sup>1</sup> Accurate placement of the neoanus in ARM repair is essential for achieving continence. The AD has traditionally served as a surface guide for SMC location during laparoscopic and perineal approaches. During laparoscopy-assisted anopectoplasty (LAARP) and trans-perineal approaches, a short 1-2 cm incision is made over the AD at the point of maximal contraction and caudo-cephalad elevation of the perineum by electrical stimulation.<sup>2</sup> This conventional technique for creating the tunnel between the perineal skin and the pelvic floor has been criticized as being semi-blind and may have a significant error in interpretation of the location of SMC.<sup>3</sup> There is also evidence that the sphincteric musculature is displaced, as well as, affected by presence of associated anomalies in patients with ARM.<sup>3,4</sup> There is paucity of information regarding the relation between the location of AD and the caudal termination of the SMC. It is also not known how often AD-based guidance results in mispositioning and adverse outcome. It is important to know the relationship between them to optimize the placement of the rectum through the center of the SMC, determine the expansion of incision, and reduce tissue dissection, during repair in both open and laparoscopic procedures; and thus reduce the chance of fecal incontinence. The placement of neoanans in the correct position is extremely important as long term continence studies have shown that both constipation and fecal incontinence are common in treated ARM patients and they have significantly worse quality of life.<sup>5,6</sup> This study investigates whether the AD is a reliable indicator of underlying SMC anatomy in ARM cases.

### Materials and methods

#### Study settings

This cross-sectional study was conducted at the Department of Pediatric Surgery, Chittagong Medical College Hospital, Chattogram between January 2023 and January 2024. Patients of ARM who underwent posterior sagittal anopectoplasty (PSARP), anterior sagittal anopectoplasty (ASARP), anterior sagittal anopectoplasty (ASAP) and abdominoperineal pull through were included. Patients with distorted perineum (having meningocele, myelomeningocele, sacrococcygeal teratoma) that may make delineation

of the anatomy difficult, cloacal malformations, patients with absence of anal dimple and with previous perineal surgery were excluded. Outcome variables were length of AD (A-B distance), length of SMC (A-B distance), distance between the center of AD and center of SMC (C-C distance) and location of SMC in relation to AD that were marked intraoperatively by vernier callipers (Figure 1).

Pre-operative assessment of the perineum and anal dimple was done. After giving general anesthesia, perineum was inspected and reconfirmation of the diagnosis with planning of surgical procedure was done. During PSARP, ASARP, ASAP and abdominoperineal pull through, the anterior and posterior limits and midpoints of AD and SMC were marked. Measurements were taken using validated Vernier callipers. All the measurements were performed by a single investigator (principal author) after receiving training from three senior pediatric surgeons to avoid interobserver variability. However, binding was not possible.

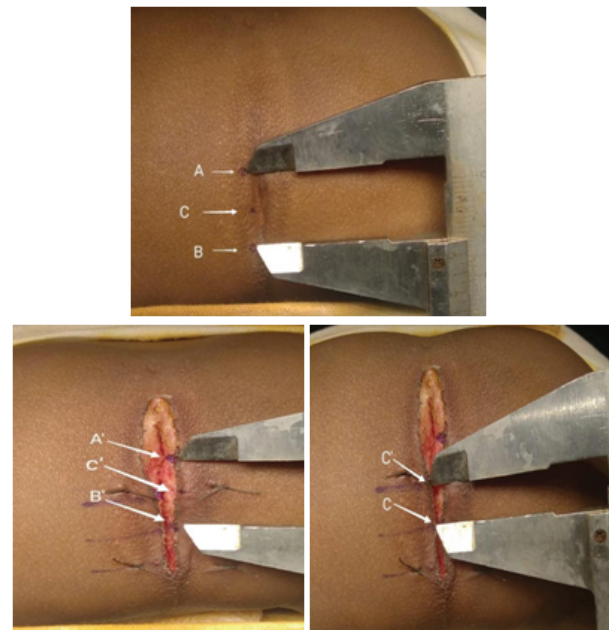


Figure 1: length of AD (A-B distance), length of SMC (A-B distance), distance between the center of AD and center of SMC (C-C distance) in a patient undergoing posterior sagittal anopectoplasty. A and A' were posterior limits and B and B' were anterior limits of AD and SMC respectively.

#### Operative technique:

After doing all pre-operative investigations, surgical procedures were done. Anterior sagittal anopectoplasty (ASARP), anterior sagittal anopectoplasty (ASAP) and abdominoperineal pull through were carried out in the supine position. Posterior sagittal anopectoplasty (PSARP) was carried out in the prone jack-knife

position. Appearance of the perineum was categorized as well or flat. AD was categorized as either "well developed" or "moderately developed" according to subjective evaluation. Indelible ink was used to define the anterior limit of AD (point A) and posterior limit (point B). The midpoint of this distance was designated as the center of AD (point C). During the surgical process, the anterior limit of SMC (point A'), posterior limit of SMC (point B) and midpoint of SMC (point C') were marked. These marks were made by assessment of the limits where vertical fibers of SMC merged with the parasagittal fibers. Based on its overall development and fiber density, SMC was categorized as either "well developed" or "moderately developed". Using Vernier calipers, the distance (C-C') between the center points of AD and SMC was measured. Location of SMC in relation to AD was determined.

**Data Analysis**

Descriptive analysis such as demographic information, clinical presentation was shown as frequency and percentage. For presentation of quantitative and qualitative data, mean ± SD and frequency and percentage was used accordingly. Gender variation of superimposition of SMC and anal dimple was analysed by Chi-square test, differences in the lengths of AD, SMC and C-C across different groups defined by the location of the striated muscle complex (SMC) were analysed using ANOVA, and correlation among lengths of AD, SMC and C-C between each other were analysed using Pearson's correlation test. Gender difference in length of AD, SMC and (C-C') were analysed using Student t test. Statistical significance was set at p<0.05. The Ethical Review Committee (ERC) of Chittagong Medical College and Hospital granted formal ethical clearance (Reference number of ERC is 59.27.0000.013.19. PG.009. 2023/967).

**Results**

Among the 30 patients, 4 (13.3%) were neonates, 17 (56.7%) were infants and 9 (30%) were children. More than two-third of the patients were less than 12 months of age. The mean age was 16.71 (± 27.75) months. 18/30 patients (60%) presented with well perineal appearance and 12 (40%) had flat perineum. 18 (60%) patients had previous fecal diversion (colostomy) and underwent staged procedure. 12 (40%) had no colostomy and underwent primary surgical procedure.

Mean length of AD (A-B) was 12.57 (± 3.58) mm ranging from 5mm to 22mm. Mean length of SMC (A-B) was 11.15 (± 3.33) mm ranging from 5mm to 18mm. Mean displacement of the center of AD with the center of SMC (C-C) was 3.4 (± 3.24) mm. Figure 2 shows differences in median values.

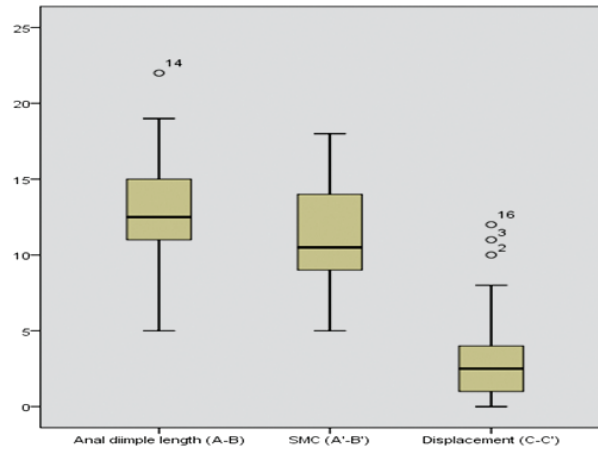


Figure 2: Box and Whisker plot diagram showing length of anal Dimple (AD), striated muscle complex (SMC) and displacement of the center of AD with the center of SMC (C-C). Boxes represent interquartile range, middle transvers line within boxes represent median values, whiskers represent lowest and highest values and outside circles represents outliers.

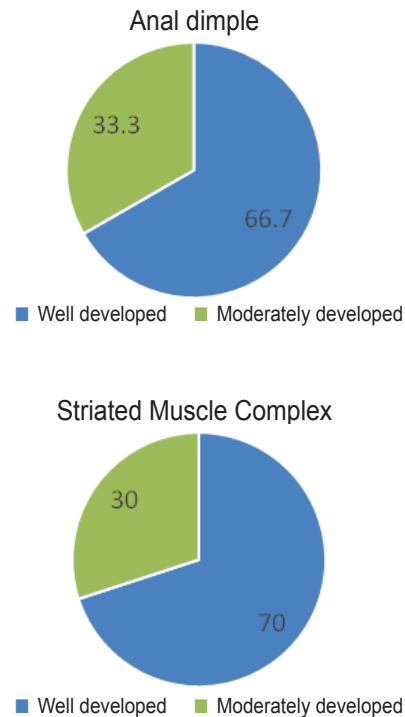


Figure 3: Development of Anal Dimple (AD) and striated muscle complex (SMC) in ARM patients (values represent percentage among total patients)

Among 30 patients, 20 (66.7%) patients had well-developed AD and 10 (33.3%) had moderately developed AD (Figure 3). In gender-wise analysis, among 20 male, 12 (60%) had well-developed AD and 8 (40%) had moder

ately developed AD. Among 10 female, 8 (80%) had well-developed AD and 2 (20%) moderately developed AD. Among 30 patients, 21 (70%) patients had well-developed SMC and 9 (30%) had moderately developed SMC. In gender-wise analysis, among 20 male, 13 (65%) had well developed SMC and 7 (35%) had moderately developed SMC. Among 10 female, 8 (80%) had well-developed SMC and 2 (20%) had moderately developed SMC. Location of SMC in relation to AD was categorized into superimposed and not superimposed (anterior and posterior). In 24 (80%) patients, center of SMC was posterior to AD. Among the rest, in 3 (10%) patients SMC was anterior to AD, in 3 (10%) patients center of SMC was superimposed with center of AD. (Table 1)

Table 1: Relationship of gender of the patient with location of striated muscle complex (SMC) in relation to anal dimple (AD) (n=30)

Location		Male (n=20)	Female (n=10)	Total	p value*
Not Superimposed	Posterior	17 (85)	7 (70)	24	p=0.34
	Anterior	1 (5)	2 (20)	3	
Superimposed		2 (10)	1 (10)	3	

\* P value obtained from Chi-square test.

The mean length of anal dimple (AD) was higher in patients whose SMC was posterior in relation to AD. The mean length of striated muscle complex (SMC) was higher in anteriorly located SMC in relation to AD. The mean length of C-C was found higher in patients whose SMC was posterior in relation to AD. To find out the differences in variance, one-way ANOVA was performed and statistical significance was not found in either length of AD or length of SMC. But statistical significance was found in length of C-C in posterior location (Table 2).

Table 2: Relationship of length of AD, length of SMC and length of C-C with location of SMC in relation to AD

Length Mean $\pm$ SD (mm)	Location		Significance*
	Anterior	Posterior	
Length of AD	10.3 $\pm$ 1.52	13.12 $\pm$ 3.61	F=1.15, p=0.24
Length of SMC	14.0 $\pm$ 3.6	11.35 $\pm$ 2.95	F=4.9, p=0.24
Length of (C-C)	3.33 $\pm$ 3.21	3.83 $\pm$ 3.26	F=7.72, p=0.002

\* P value obtained from One way analysis of variance (ANOVA) test.

The length of AD and the length of SMC correlated with each other and found statistically significant ( $p < 0.05$ ) (Table 3). There was also significant correlation between

the length of AD (A-B) and length of (C-C) ( $p < 0.05$ ). Similarly, the length of SMC (A-B) and length of (C-C) significantly correlated with each other ( $p < 0.05$ ). However, the correlation between them were weak as shown by the correlation's coefficients ranging from 0.37-0.48.

Table 3: Correlation between length of AD, SMC and length of (C-C)

Characteristics	Correlation coefficient(r)	p-value*
Length of AD and length of SMC	0.43	p=0.02
Length of AD and length of (C-C)	0.37	p=0.006
Length of SMC and length of (C-C)	0.48	p=0.04

\* P value obtained from Pearson's correlation test where r value less than 0.5 indicates a weak correlation.

The mean length of AD was slightly higher in female than male (Table 4). Similarly, the mean length of SMC was higher in female than in male. The mean range of (C-C) was found more in male. The difference was not statistically significant.

Table 4: Gender difference in Length of AD, SMC and (C-C')

Length	Mean $\pm$ SD (mm)		p-value*
	Male	Female	
Anal dimple (A-B)	12.40 $\pm$ 3.34	12.90 $\pm$ 4.17	p=0.67
SMC (A-B)	10.97 $\pm$ 3.77	11.5 $\pm$ 2.32	p=0.08
Distance between center of AD and center of SMC (C-C)	4.4 $\pm$ 3.54	1.4 $\pm$ 0.84	p=0.09

\* P value obtained from Student t test.

## Discussion

The main goal of surgery for ARM is to provide a better outcome for a healthy lifestyle of the patient. There are a significant number of patients who have post-operative problems such as, fecal incontinence or constipation. Pringle, K.C., et. al. concluded that the narrow width and short extent of SMC play an important role in defecation.<sup>7</sup> Patel, J.N., et. al. studied the anal position index (API) and concluded that the midpoint of the AD is the representative position which is usually situated anterior to the normal anal position.<sup>2</sup> Therefore, in the event of definitive surgery, if the AD is chosen as the location of the planned neo-anus, the neo-anal position is likely to be anterior to the normal anal position in both males and females; particularly in males. Kumar, A., et. al., found that SMC was posterior to AD in 80%, superimposed in 15.6% and anterior in the rest which is consistent with this study.<sup>8</sup> Male had more posterior location of SMC in relation to AD, whereas female had more anterior

location. Therefore, it can be concluded that in 90% cases the termination of the cephalocaudal band of fibers constituting the SMC doesn't match with AD.

Male ARMs were recto-bulbar urethral, rectovesical, recto-bladder neck fistula, imperforate anus without fistula and perineal fistula whereas, female ARMs were vestibular, perineal and recto-vaginal fistula. Perineal fistula was found more in male than female. ARM without fistula was found only in male. Elrouby, A., et. al., found more rectovestibular fistula and anovestibular fistula with a few rectovaginal fistulas (71.7% vs 16.8 vs 1.2%).<sup>1</sup> Patel, J.N., et. al., found more cases of vestibular and perineal fistula in their studies (26.9 vs 13.8%).<sup>2</sup> Qazi, S.H., et. al., showed that most of the cases had recto-bulbar urethral and recto-vestibular fistula (33% and 31%) followed by recto-vesical, recto-vaginal and recto-perineal fistula (17% vs 9% vs 9%).<sup>9</sup> Kumar, A., et. al., also found more vestibular and perineal fistula (40% vs 15.5%).<sup>8</sup> Types of ARM varies among studies. In this study, vestibular fistula was common in female which is similar to other studies. In contrast, recto bulbar urethral, recto vesical and ARM with no fistula were more in male which differs from other studies.

In this study, two third of the patients had well-developed AD and the rest had moderately developed AD. Female had more well-developed AD than male (80% vs 60%). Recto-vesical, perineal, vestibular fistula and ARM with no fistula had well developed AD. In contrast, Recto-bulbar urethral fistula, recto-vaginal fistula and recto-bladder neck fistula had moderately developed AD. In the study by Kumar, A., et. al. well-developed AD was predominant (80%) and its was higher in male than female (85% vs 76%) which is opposite to this study.<sup>8</sup> Patel, J.N., et. al. found well-developed AD in 81.5% and moderately developed in 18.5% cases which is similar to the findings of this study.<sup>2</sup> Males (91%) had more well-developed AD than females. Boys with recto-bulbar urethral fistula had moderately developed AD.

A study related to rectoplasty classified SMC as adequate or deficient according to their availability.<sup>10</sup> Kumar, A., et. al. classified the SMC as well developed and moderately developed category.<sup>8</sup> In this study, we classified SMC as well-developed and moderately developed. More than two-third of the patients (70%) had well-developed SMC, and the rest (30%) had moderately developed SMC. Female had more well-developed SMC than male (80% vs 65%). In male, recto-bulbar urethral fistula and recto-vesical fistula (3 cases in each group), with one recto-bladder neck fistula had moderately developed SMC. In female, only two cases of vestibular fistula had moderately developed SMC. In contrast, perineal fistula, five cases of vestibular fistula, recto-vaginal and ARM with no fistula had well developed SMC. Kumar, A., et. al.

found that the majority of the patients had well-developed SMC (86.7%) and the rest were moderately developed. Male had more well-developed SMC than female (90% vs 84%) which is opposite to the findings of this study. They found one case of recto-vesical fistula in male and two cases of vestibular fistula with moderately developed SMC. These differences may be due to different geographical distribution and racial variations. All cases of recto-perineal fistula had well-developed SMC in this study which is similar to their study.

Magnetic resonance imaging was done in patients with untreated ARM by Pringle, K.C., et. al., 1987.<sup>7</sup> They found the length of SMC ranging from 1-2 cm. Studies including Kumar et al. showed similar results regarding SMC where female have more width than male (14.24 vs 13.45 mm). The overall mean length of AD was slightly higher in female than male (12.90±4.17 mm vs 12.4±3.34 mm) and the mean length of SMC was more in female than in male (11.5±2.32 mm vs 10.97±3.77 mm). In contrast, the length of C-C was higher in male than female (4.4±3.5 mm vs 1.4±0.8 mm). However, the differences were not statistically significant. In this study, correlation between the lengths were measured and statistical significance was found between AD and SMC ( $r=0.43$ ,  $p=0.02$ ), SMC and length of C-C ( $r=0.37$ ,  $p=0.006$ ) and between AD and length of C-C ( $r=0.48$ ,  $p=0.04$ ). The mean displacement of the center of AD from the center of SMC was higher in the posterior location than the anterior (3.83±3.26 vs 3.33±3.21 mm) and was statistically significant. Studies that located normal anal position showed that anus is more anteriorly placed in females than in males. Anal position index was 0.56 in males and 0.4 in females. In this study it was also observed that females had more anterior location of SMC in relation to AD and males had more posterior location.<sup>11,12</sup> This is also an indication that anal dimple does not represent an accurate position of neanus. However, the clinical impact of this misplacement is yet to be established.

During the comparison of C-C with ARM subtypes, the recto-bulbar urethral fistula had the maximum posterior deviation followed by ARM with no fistula and recto-vesical fistula. In boys with recto-vesical fistula, anterior displacement of C-C was 7mm. In comparison, Kumar, A., et. al., 2022 found a higher mean width of AD and SMC in female than in male. They also found the mean displacement of C-C was 4.8±3.4mm in posterior location, which is higher than this study findings (3.83±3.26 mm). Kumar, A., et. al., also found the maximum posterior deviation in recto-vesical fistula followed by recto-perineal fistula and ARM with no fistula. In this study, in anterior deviation, mean length of AD and SMC was 9.5± 0.71 and 12± 1.41 respectively in vestibular

lar fistula. In the recto-vesical fistula, length of AD, SMC and C-C distance was higher; 12mm, 18 mm and 7 mm respectively. In the superimposed cases, the highest length of AD and SMC was  $9.5 \pm 4.9$  and  $7.5 \pm 2.12$  mm respectively in perineal fistula. The length of AD and SMC was 12mm and 5mm respectively in ARM with no fistula. However, in posterior deviation, the mean length of AD was higher in recto-bulbar urethral fistula ( $14.8 \pm 2.48$ mm). ARM with no fistula showed the highest mean length of SMC ( $12.0 \pm 2.94$ mm). Posterior deviation of (C-C) was maximum in the recto-bulbar urethral fistula ( $7.8 \pm 3.83$  mm). In case of length of AD and SMC, the recto-bladder neck (12mm and 16mm) and recto-vaginal fistula (22mm and 15mm) showed higher distance. Both categories showed a posterior deviation of 3 mm from the center point of AD. This finding is also consistent with the findings by Liman et al who showed that preoperative and post operative anal position indices were significantly different when it was based on AD.<sup>12</sup>

The findings of the study have practical implications for optimizing the placement of the rectum through the center of the SMC during surgical procedures. During the procedures, great care should be taken to place the anus within the boundary of SMC to prevent complications and achieve a better functional outcome. This study recommends use of intraoperative muscle stimulator or direct visual confirmation instead of relying on AD. This is also important due to the current advocations in the practise of Anal Dimple Anorectoplasty by some institutes instead of traditional ASARP or PSARP.<sup>13</sup>

The study has some limitations. Sample size is small. As muscle stimulator were not available in our set up, we could not use it in this study and the lack of neuro-mapping reduces its international acceptance and reproducibility. However, many pediatric surgical centres in low income and developing countries, who have the most caseloads in the world, cannot afford muscle stimulators. For their perspective, findings from this study would be beneficial for planning surgical repair in ARM patients. Although this study supports previous findings that AD does not reliably indicate SMC location and in 90% of cases there is a mismatch; information from many other parts of the world were not available searching literature and could not be compared which limits its global relevance.

### Conclusion

The AD does not align with the SMC in most ARM cases. Depending solely on it for surgical guidance may lead to poor outcomes. Intraoperative visualization or neuromonitoring is recommended for accurate neanus placement.

### Acknowledgement

None

### Conflict of Interest

None

### References

1. Elrouby, A., Waheeb, S. and Koraitim, A., Anterior sagittal anorectoplasty as a technique for the repair of female anorectal malformations: a twenty-two-years-single-center experience. *Journal of Pediatric Surgery*, 2020;55(3), pp.393-396.
2. Patel, J.N., Kumar, A., Yadav, P.S., Chadha, R., Datta, V. and Choudhury, S.R.,. The position of the anal dimple in newborns and infants with anorectal malformations and its correlation with the normal anal position. *Journal of Pediatric Surgery*, 2018;53(8), pp.1560-1565.
3. Li L, Ren X, Xiao H, Wang C, Xu H, Ming A, Wang X, Li Z, Diao M, Cheng W. Normal anorectal musculatures and changes in anorectal malformation. *Pediatric Surgery International*. 2020;36(1):103-11.
4. Pitaka RT, Fauzi AR, Makhmudi A, Gunadi. Comparison and impact of associated anomalies on the anal position index in neonates with anorectal malformation. *BMC Research Notes*. 2022; 7;15(1):294.
5. Firinci B, Salman AB. Evaluation of Long-term Results and Stool Incontinence of Patients with Operated Anorectal Malformations. *Journal of Behcet Uz Children's Hospital*. 2023;1:13(1).
6. Beattie H, Subramanian T, Scudamore E, Middleton T, MacDonald C, Lindley R, Murthi G. Assessment of long-term quality of life, bowel and voiding function outcomes in patients with anorectal malformation at a single UK centre. *Pediatric Surgery International*. 2024;3;40(1):95.
7. Pringle, K.C., Sato, Y. and Soper, R.T.,. Magnetic resonance imaging as an adjunct to planning an anorectal pull-through. *Journal of pediatric surgery*, 1987;22(6), pp.571-574.
8. Kumar, A., Bangar, V., Khan, N.A., Patel, J.N., Gupta, A., Yadav, P.S., Chadha, R. and Choudhury, S.R.,. Correlation of the position of the anal dimple with the caudal termination of the striated muscle complex in patients with anorectal malformations. *Journal of Indian Association of Pediatric Surgeons*, 2022; 27(2), p.185.
9. Qazi, S.H., Faruque, A.V., Khan, M.A.M. and Saleem, U.,. Functional outcome of anorectal malformations and associated anomalies in era of Krickenberg classification. *JCPSP: J Coll Physicians Surg Pak*, 2016;26(3), p.204.
10. Nah, S.A., Ong, C.C., Lakshmi, N.K., Yap, T.L., Jacobsen, A.S. and Low, Y.,. Anomalies associated with anorectal malformations according to the Krick

enbeck anatomic classification. *Journal of pediatric surgery*, 2012;47(12), pp.2273-2278.

11. Mohamed S, Mohamed A. The anal position index: A simple method to determine the normal position of the anus in neonates and its significance in diagnosis of constipation. *AAMJ* 2011;9:374-84
12. Liman BI, Mohammed MA, Anyanwu LJ, Abdullahi LB, Aji SA, Aliyu MS, Sa'ad B, Jalo RI, Mamuda A, Hassan MM, Usman AN. Evaluation of Anal Position Indexes from Anal Dimple and Neoanus at Sphincter Muscle Complex in Children with High Anorectal Malformations in Kano, Nigeria. *African Journal of Paediatric Surgery*. 2024;10-4103.
13. Su H, Li Z, Yuan T, Li H, Wang F. Investigating the Efficacy of Anal Dimple Anorectoplasty in Congenital Anal Atresia: A Systematic Review and Meta-Analysis. *Alternative Therapies in Health and Medicine*. 2024 Jun 28;AT10521.