



Original Article

DORSAL DOUBLE LAYER DARTOS FLAP IN THE SNODGRASS TECHNIQUE OF HYPOSPADIAS REPAIR: AN EXPERIENCE IN DHAKA MEDICAL COLLEGE HOSPITAL

DAS SK¹, HASINA K², HUQ MA³, KHAN JG⁴, ALAM SMS⁵, ISLAM MT⁶

Abstract

Introduction: Hypospadias is one of the most common congenital anomalies and more than 300 operation techniques have been described for primary hypospadias. The Snodgrass technique and its modification have become a preferred for all varieties of hypospadias in the past decade. However fistula is the most common of this technique. The aim of the study is to investigate the importance of double layer dartos flap to prevent fistula formation in the Snodgrass technique.

Materials and Methods: It's a retrospective study, among 52 patients aged 11 months to 144 months who underwent mid penile and distal hypospadias repair in the Snodgrass technique using dorsal dartos flap for neo-urethral coverage. This study was done in the Department of Pediatric Surgery in Dhaka Medical College & Hospital from November 2014 to December 2016.

Results: Urethrocutaneous (UC) fistula were encountered in 10 patients (19.23%), meatal stenosis in 3 patients (5.76%),

partial glanular dehiscence in 1 patient and residual chordee in 1 patient.

Conclusions: For preventing fistula formation, urethral covering by a well vascularized dorsal double layer dartos flap should be the important part of the Snodgrass technique.

Key words: Hypospadias, UC fistula, Meatal Stenosis, Residual Chordee, Dartos Flap

Introduction:

Since 1994, the Snodgrass repair (tubularized incised plate or TIP) has been the procedure of choice for distal and mid-shaft hypospadias repair and its application has been extended to all types of hypospadias defect. The procedure is easy to follow and gives good cosmetic and functional results¹. Urethrocutaneous (UC) fistula remains the most frustrating complication of hypospadias repair, with a frequency of 5–23%². The more proximal the hypospadiac orifice the greater is the rate of postoperative UC fistula formation³. There are different techniques for preventing this complications. The dartos flap is composed of vascularized subcutaneous tissue that is dissected from the dorsal preputial and shaft skin. Its placement over the neourethra in incised plate urethroplasty reduces the incidence of postoperative UC fistula⁴. The aim of this study is to evaluate the importance of double layered dartos flap to prevent fistula formation in the Snodgrass technique.

Materials and Method

Type of study: Retrospective study.

Place of study: The study was conducted in the Department of Pediatric Surgery, Dhaka Medical College and Hospital (DMCH), Dhaka.

1. Dr. Sahadeb Kumar Das, Indoor Medical Officer, Dept. of Pediatric Surgery, Dhaka Medical College and Hospital, Dhaka.
2. Prof. Kaniz Hasina, Professor, Dept. of Pediatric Surgery, Dhaka Medical College and Hospital, Dhaka.
3. Prof. Md. Ashraf Ul Huq, Professor and Head, Dept. of Pediatric Surgery, Dhaka Medical College and Hospital, Dhaka.
4. Dr. Jaglul Gaffer Khan, Associate Professor, Dept. of Pediatric Surgery, Dhaka Medical College and Hospital, Dhaka.
5. Dr. S. M. Shafiqul Alam, Senior Consultant, Dept. of Anaesthesiology and ICU, Dhaka Medical College and Hospital, Dhaka.
6. Dr. Md Tawhidul Islam, Assistant Professor, Dept. of Pediatric Surgery, Dhaka Medical College and Hospital, Dhaka.

Correspondence to: Dr. Sahadeb Kumar Das, Indoor Medical Officer, Dept. of Pediatric Surgery, Dhaka Medical College and Hospital, Dhaka. Email: sahadbk8@yahoo.com

Duration of the study: 26 months (From November 2014 to December 2016).

Study subjects: The study included children with mid penile and distal (coronal & distal penile) hypospadias.

Sample size: Total 56 cases were recorded but 4 records are incomplete. Finally 52 cases (11 months to 144 months) was selected for the study (Sample size, n=52).

Data collection method: Hospital records of patients diagnosed as mid penile and distal hypospadias who underwent hypospadias repair in the Snodgrass technique using dorsal dartos flap as tissue interposition for preventing fistula. Record file of each patient was scrutinized and total number of patients during the period was calculated. The fistula rate and other complications related to each group were recorded.

Processing and statistical analysis of data: Statistical analysis was performed using the Statistical Package for Social Science (SPSS) version 22.0.

Surgical procedure: Under general or caudal anaesthesia, patient was placed in supine position. Preoperative prophylactic dose of antibiotic (Ceftriaxone) was given according to body weight. Social toileting was done with hexiscrub and normal saline. After painting and drapping, a traction suture was applied to the glans by 4/0 round body proline. A U-shaped incision was made around the urethral plate border and hypospadias orifice. Then circumcoronal preputial incision was made and the penis was degloved. Two parallel longitudinal incisions were made to separate the lateral edges of the urethral plate from the glans wings. An artificial erection test performed to assess for residual ventral curvature. Any chordee if present was corrected by midline dorsal tunica albuginea plication. The incised urethral plate was tubularized using 6/0 polyglactin sutures over a stent in one layer, turning all of the epithelium into the neourethral lumen. Tubularization of the urethral plate started from the proximal end to the midglanular level. Dartos flap was taken from the dorsal preputial skin and divided in two wings and laterally twisted to cover the neourethra as double layer (bat wing) fashion. The glans wings were approximated with no tension, and the penile skin was sutured. All patients were then circumcised. The stent was secured to the glans with the traction

suture. Pressure dressing was applied in all cases with cotton guaze and adhesive tape.

Ceftriaxone and Amikacin in injectable form was given in all the patients upto 3rd postoperative day (POD). Syrup Cefixime was given from 4th to 10th POD. First dressing was checked on 4th POD, wound was kept open and Mupirocin ointment was applied on the wound 3 times daily for 14 days. Stent was removed on 10th POD. Patients were discharged on 14th POD with advice of meatal calibration.

Follow up consisted of a first visit at the end of 1st month, second visit at the end of 3rd month and further visit at 1 year.

Table-I
Patients Characteristics

Preoperative features	
Mean Age (Month)	80.19
Meatal location:	
Coronal	22
Distal penile	16
Mid penile	14
Chordee:	
Absent	19
Mild (<30°)	24
Moderate(30° - 60°)	9
Urethral Plate	
Narrow	25
Width	27

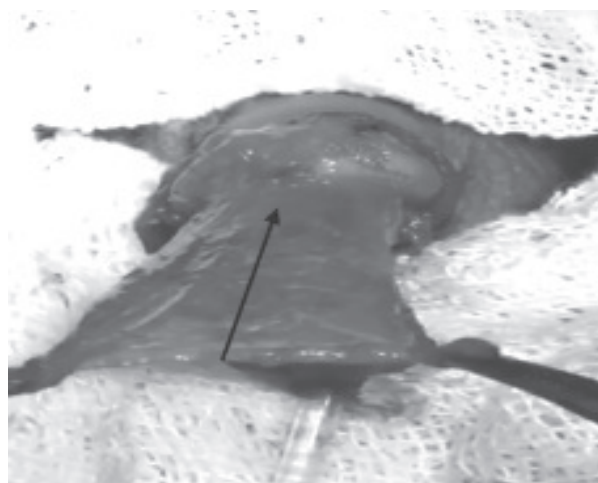


Fig.-1: Dartos flap taken from dorsal preputial skin that was splitted in the midline.

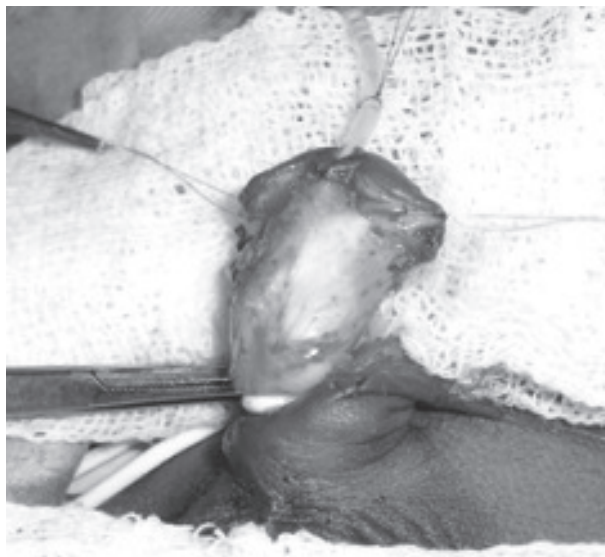


Fig.-2: Transferring two flaps to the ventral side over the neourethra and suturing of the two layers in double layer fashion

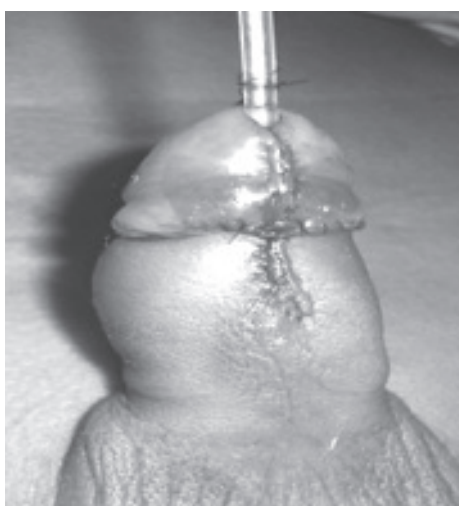


Fig.-3: Appearance after completing the urethroplasty

Results:

All the patients of mid penile and distal hypospadias underwent urethroplasty in the Snodgrass procedure using an overlapping double-layered well vascularized dorsal dartos flap for covering the neourethra. At a follow up of 1 year, all patients except one had a satisfactory cosmetic and functional result, with a vertically oriented, slit-like meatus at the tip of the glans. UC fistula were encountered in 10 patients (19.23%). There was no significant difference between the type of hypospadias and UC fistula

formation ($p=0.22$). Table 3 shows the relation of type of hypospadias and UC fistula formation. Meatal stenosis was found in 3 patients on follow up (5.76%) that was successfully managed by dilation. Partial glanular dehiscence occurred in 1 patient. One patient who developed residual chordee had moderate chordee preoperatively.

Table-II
Complications after urethroplasty

Complications	
Fistula	10(19.23%)
Meatal Stenosis	3 (5.76%)
Glanular dehiscence	1(1.92%)
Residual chordee	1(1.92%)

Table-III
Relation of type of hypospadias and UC Fistula

Type of hypospadias	UC fistula		Total
	No	Yes	
Coronal	20	2	22
Distal penile	11	5	16
Mid penile	11	3	14
Total	42	10	52

P=.22

Discussion:

A tubularized incised plate urethroplasty described by Snodgrass presents the method of choice in the treatment of distal and mid shaft hypospadias with minimal complication rate⁵.

The ideal age for repair of hypospadias is 6-18 months⁶. The growth of penile length takes place for upto 5 years followed by little change until the onset of puberty⁷. In this study, the mean age was 80.19 months. The mean age of the both groups were higher than the ideal age for hypospadias repair. This may be due to the fact that people living in low socio-economic condition are not aware of their health.

A UC fistula is an inherent complication of hypospadias repair, and represents the most common problem after such surgery, occurring at various rates⁸⁻¹¹. Different tissues and techniques have been described to solve this problem.

The vascularized dartos flap is suitable for second layer coverage of the neo-urethra. The flap can be easily harvested, as the tissue is available in the external genitalia lining the prepuce, penile shaft and scrotum. So, dissection can be extended to the base of the penis to obtain a suitable flap length and size. There have been many reports of different techniques for harvesting and applying the dartos flap. Harvested dorsal dartos flap can be laterally twisted or buttonholed and transposed to the ventrum for neo-urethral coverage. A ventrally based dartos flap was also used to avoid penile rotation, with a fistula rate of 1.8%¹².

In this study, dartos flap was taken from dorsal preputial and penile skin and used for neourethral coverage in the same technique of double-layer fashion (bat wing). Using this technique, different investigators from different studies observed no fistula in double dartos flap coverage in comparison with single dartos flap. In their study, fistula rate ranging from 5.2% to 13.7% in whom single dartos flap was given¹³⁻¹⁹. On the other hand, Elsayed et al. reported no significant difference in subsequent UC fistula between a double layer dorsal dartos flap and single layer for covering the urethra as a part of TIP urethroplasty for repairing hypospadias²⁰. In the present study, post-operative fistulae were found in 19.23% (10/52) of the cases in which only the dartos flap was used as double layer fashion. These results were dissimilar with the above mentioned studies. This difference may be due to higher age of the patients, below average socioeconomic condition, poor nutritional status, poor hygienic environment in the ward or may be due to lack of maintaining proper sterility in the OT, lack of fine instruments for meticulous tissue handling, failure to use the magnification glasses or loupes etc.

This technique also gives satisfactory cosmetic results: no penile rotation occurs since the equal dartos strips create counter traction on both sides of the penile shaft. The drawback of this technique is the bulk of tissue that may make approximation and closure of the granular wings difficult. To avoid this drawback, the glandular wings were widely separated and generously deepened.

Conclusion:

A urethral covering should be performed as a part of the Snodgrass procedure. It has been suggested that double dartos flap covering as neourethral coverage

are more effective than a single flap coverage for prevention of UC fistula formation. However, the role of double layer dartos flap can be evaluated in a prospective, randomized and controlled study in a large number of patients.

Disclosure: All the authors declared no competing interest.

References:

1. Abolyosr A. Snodgrass hypospadias repair with onlay overlapping double-layered dorsal dartos flap without urethrocutaneous fistula: Experience of 156 cases. *J Pediatr Urol* 2010; 6: 403-407.
2. Maarouf AM, Shalaby EA, Khalil SA & Shahin AM. Single vs. double dartos layers for preventing fistula in a tubularised incised-plate repair of distal hypospadias. *Arab J Urol* 2012; 10: 408-413.
3. Gapany C, Grasset N, Tercier S, Ramseyer P, Frey P, Meyrat BJ, et al. A lower fistula rate in hypospadias surgery. *J Pediatr Urol* 2007; 3: 395-397.
4. Kamal BA. Double dartos flaps in tubularized incised plate hypospadias repair. *Urology* 2005; 66: 1095-1098.
5. Snodgrass WT. Tubularised incised plate urethroplasty for distal hypospadias. *J Urol* 1994; 151: 464-465.
6. Schultz J, Klykylo W & Wacksman J. Timing of elective hypospadias repair in children. *Pediatrics* 1983; 71: 342-351.
7. Chalapathi G, Rao KLN, Chowdhary SK, Narasimhan KL, Samujh R & Mahajan JK. Testosterone therapy in micropallic hypospadias: Topical or parenteral? *J Pediatr Surg* 2003; 38(2): 221-223.
8. Elbakry A. Tissue interposition in hypospadias repair: a mechanical barrier or healing promoter? *Arab J Urol* 2011; 9: 127-128.
9. Borer JG, Bauer SB, Peters CA, Diamond DA, Atala A, Cilento Jr BG et al. Tubularized incised plate urethroplasty: expanded use in primary and repeated surgery for hypospadias. *J Urol* 2001; 165: 581-585.
10. Chen SC, Yang SSD, Hsieh CH & Chen YT. Tubularized incised plate urethroplasty for proximal hypospadias. *BJU Int* 2000; 86: 1050-1053.

11. Holland AJ & Smith GH. Effect of the depth and width of the urethral plate on tubularized incised plate urethroplasty. *J Urol* 2000; 164: 489-491.
12. Furness 3rd PD. Successful hypospadias repair with ventral based vascular dartos pedicle for urethral coverage. *JUrol* 2003; 169: 1825-1827.
13. Maarouf AM, Shalaby EA, Khalil SA & Shahin AM. Single vs. double dartos layers for preventing fistula in a tubularised incised-plate repair of distal hypospadias. *Arab J Urol* 2012; 10: 408-413.
14. Abolyosr A. Snodgrass hypospadias repair with onlay overlapping double-layered dorsal dartos flap without urethrocutaneous fistula: Experience of 156 cases. *J Pediatr Urol* 2010; 6: 403-407.
15. Erol A, Kayikci A, Memik O, Cam K & Akman Y. Single vs. double dartos interposition flaps in preventing urethrocutaneous fistula after tubularized incised plate urethroplasty in primary distal hypospadias: a prospective randomized study. *Urol Int* 2009; 83: 354-358.
16. Appignani A, Prestipino M, Bertozzi M, Nardi N & Falcone F. Double-cross flap protection. New technique for coverage of neourethra in hypospadias repair. *J Urol* 2009; 182: 1521-1527.
17. Mustafa M, Wadie BS & Abol-Enein H. Standard Snodgrass technique in conjunction with double-layer covering of the neourethra with dorsal dartos flap is the therapy of first choice for hypospadias. *Int Urol Nephrol* 2008; 40: 573-576.
18. Bakan V & Yildiz A. Dorsal double-layer dartos flap for preventing fistulae formation in the Snodgrass technique. *Urol Int* 2007; 78: 241-244.
19. Kamal BA. Double dartos flaps in tubularized incised plate hypospadias repair. *Urology* 2005; 66:1095-1098.
20. Elsayed ER, Zayed AM, Sayed DE & Adl ME. Interposition of dartos flaps to prevent fistula after tubularized incised-plate repair of hypospadias. *Arab J Urol* 2011; 9: 123-126.