



## Original Article

# EARLY POST-OPERATIVE OUTCOME OF PRIMARY REPAIR OF BLADDER EXSTROPHY WITH OR WITHOUT OSTEOTOMY

SMB UDDIN<sup>1</sup>, MAB AKAN<sup>2</sup>, R KHASTGIR<sup>3</sup>, MR AMIN<sup>4</sup>

### Abstract:

**Background:** Bladder exstrophy (BE) is a variety of infra-umbilical midline anterior abdominal wall defect. This rare spectrum of anomalies involves the urinary tract, genital tract, musculoskeletal, system and sometimes the intestinal tract. Surgical reconstruction with or without osteotomy is the treatment of choice for BE. **Objective:** To evaluate the intersymphyseal gap (ISG) before, during and after operation (pubic diastasis) and to evaluate the status of post-operative wound healing. **Materials & Methods:** This cross sectional study was conducted on 18 patients of paediatric age group over a period from February 2007 to October 2008 who were admitted with classical bladder exstrophy (BE) in the department of paediatric surgery, BSMMU.. They were divided into two groups. In group-A: 8 patients of BE were undergone primary repair with osteotomy and in group-B primary repair done in 10 patients without osteotomy. **Results:** Two (2) months post-operative follow-up revealed that all osteotomy patients (group-A) developed re-diastasis of pubic symphysis. **Discussion:** Statistically no significant difference of ISG was observed in two groups of patients. Wound healing was better in without osteotomy (group-B) patients (80% vs 50%) and wound failure was more in osteotomy patients (50% vs 20%). Moreover, osteotomy group need hospitalization for longer period of time. **Conclusions:** Although osteotomy is an essential step in the management of BE, this study revealed that it does not improve the early post-operative outcome.

**Keywords:** Bladder exstrophy, osteotomy, diastasis.

1. Dr.S.M. Borhan Uddin, Asstt. Professor, Department of Paediatric Surgery, Dinajpur Medical College.
2. Dr. Md Abu Bakar Akan, Medical Officer Upozila Health Complex, Swarupkati, Pirojpur
3. Dr. Rajib Khastgir, Lecturer, Department of Anatomy, Chittagong Medical College
4. Prof.Md Ruhul Amin, Professor Department of paediatric Surgery, BSMMU

**Correspondence to :** Dr. S.M.Borhan Uddin, Asstt. Professor, Department of Paediatric Surgery, Dinajpur Medical College. Bangladesh, E-mail dr\_philip78@yahoo.com.

### Introduction:

Bladder exstrophy is a variety of infra-umbilical midline anterior abdominal wall defect. It is a rare anomaly with an incidence of 1 in 10,000 to 50,000 live births<sup>15</sup>. In classical bladder exstrophy, most anomalies are related to defects of the abdominal wall, bladder, genitalia, pelvic bone, rectum and anus<sup>6</sup>.

This defect is usually associated with other conditions e.g. inguinal hernia, undescended testis, vesicoureteric reflux<sup>3</sup>.

Surgical reconstruction with or without osteotomy is the treatment of choice. The primary objectives of modern surgical management of classical bladder exstrophy are secure abdominal wall and bladder closure, reconstruction of functionally and cosmetically acceptable penis in male and external genitalia in female and continent urinary bladder with well preservation of renal function<sup>6</sup>.

Jeffer proposed a staged reconstruction procedure to repair bladder exstrophy. Primary repair (bladder, posterior urethra and abdominal wall closure) should be done immediately after birth (usually within 24 to 72 hours). After 72 hours, he preferred to do osteotomy during primary repair. Epispadias repair is done between 6 months to 12 months. And finally, bladder neck is reconstructed at 4-5 years of age<sup>3</sup>.

In 1995, Kelly proposed a staged procedure for reconstruction of bladder exstrophy without osteotomy. Though it is staged procedure but outcome in terms of wound healing and continence are better here. The physiological continence rate was 73% (14 out of 19 patients). Osteotomy related morbidity can be avoided in this procedure<sup>11</sup>.

Mitchell has described an approach of complete primary repair of bladder exstrophy that combines the bladder closure with epispadias repair in newborn period. He has shown that the overall continence rate was 76 % (13 of 17 patients) & complications rate were also minimum as compared to other procedure<sup>12</sup>.

So, both Mitchell and Kelly differ from Jeffs in primary repair of bladder exstrophy. They have shown better outcome without performing osteotomy<sup>11,12</sup>.

So for the management of bladder exstrophy, some advocate a single stage repair in neonatal period<sup>12</sup>. Some prefer staged repair comprised of initially bladder and abdominal wall closure, epispadias repair & bladder neck reconstruction at later dates<sup>1</sup>. Some surgeon repaired the bladder exstrophy by extensive soft tissue mobilization<sup>11</sup>.

The goal of osteotomy is to restore a more normal configuration of bony pelvis, prevent wound dehiscence and thus increase the chance to be continent<sup>2</sup>. When the pubic separation is wide (>4 cm), or the surgery is performed at an older age (usually after 72 hours of life), or at the time of failed exstrophy repair, osteotomy is a good option to achieve a better closure<sup>10</sup>. It is also beneficial in primary procedure as it might improve orthopedic and urological outcomes<sup>4</sup>.

But osteotomy has many disadvantages. It is a difficult procedure, the operative time is more, increased operative blood loss and need repositioning of the patient (from prone to supine in bilateral posterior iliac osteotomy)<sup>3</sup>. Osteotomy patient needed hospitalized for a longer period of time and took more time to return in normal activity. They needed plaster and external or internal fixation. So there are possibilities of complications related to plaster and immobilization<sup>14</sup>. Following primary closure of bladder exstrophy with osteotomy, there was considerable progressive separation (re-diastasis) of the pubic bones<sup>5,8,9</sup>.

So this study represents an easy and rational approach to address this controversial issue whether surgery should be done with or without osteotomy. We feel so much interest to see the early post-operative outcome of bladder exstrophy repair with osteotomy and without osteotomy in terms of wound healing.

#### Methods of the study:

Appropriate written informed consent was taken from the legal guardians to include the patients in this study. A total of 18 patients of classical bladder exstrophy were included. They were divided into two groups.

In Group- A: Eight patients of bladder exstrophy were underwent primary repair with osteotomy.

In Group- B: Ten patients of bladder exstrophy were undergone primary repair without osteotomy.

Patients were prepared after taking history, physical examination and relevant investigations. And operation was done under general anaesthesia with endotracheal intubation.

X-ray pelvis- was done pre-operatively and post-operatively to measure the Intersymphyseal gap (ISG) in mm. Measurements of ISG were taken as 25 mm, 30 mm, 35 mm and so on.

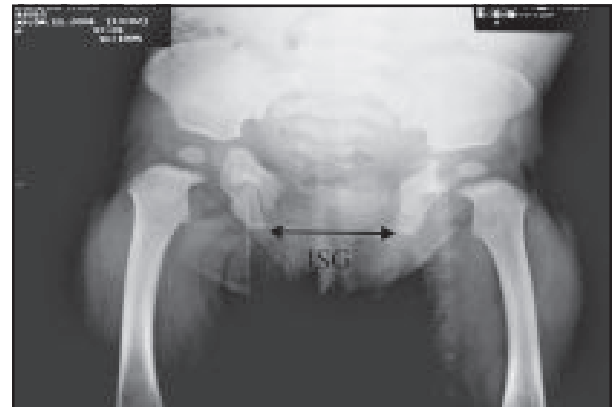


Fig.-1: Pre-operative X-ray pelvis.

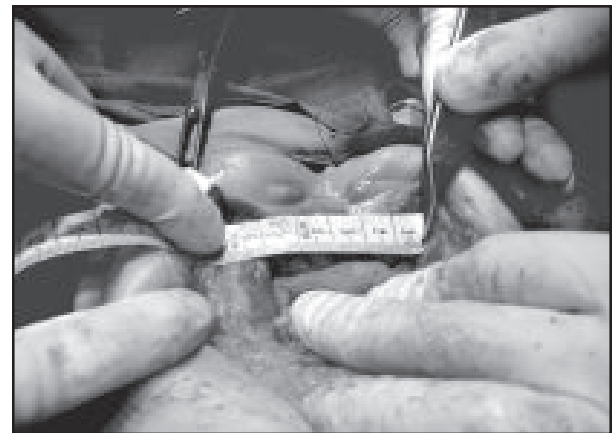

Fig.-2: Per-operative measurement of ISG.

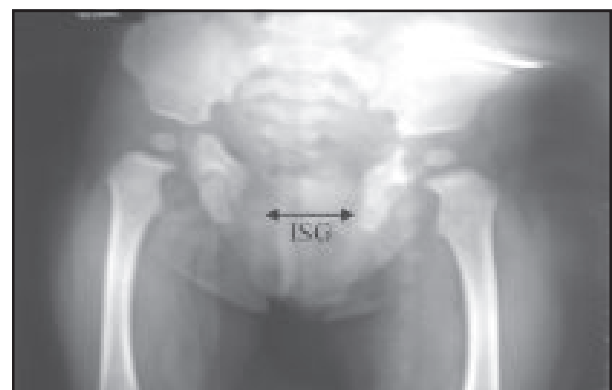


Fig.-3: Post-operative X-ray pelvis.

### Post-operative follow-up

Patients with osteotomy needed immobilization with full leg plaster for 1½ months. Plasters were removed after 6 weeks and patients were discharged with advice to follow up weekly for next two weeks. Ureteric catheter, urethral catheter and bladder catheter were removed on 10<sup>th</sup> POD, 14<sup>th</sup> POD and 21<sup>st</sup> POD respectively. After removal of the catheter, patients were observed for fistula formation and urinary stream. The patients without osteotomy were discharged within one month and advised to attend Paediatric Surgery OPD weekly for another one month.

The analysis of the results was done by using Fisher's exact test and ANOVA test. P value of <0.05 was considered as significant.

### Results:

#### Age distribution (months):

Age range of osteotomy Group (Group–A) was 2.5 – 156 months with a mean of 37.31 + 56.16 and for Group- B it was 0.3 – 180 with a mean of 57.96 + 62.11. P value was 0.476, which was statistically not significant.

#### Intersymphyseal gap (ISG):

In group- A (Osteotomy group): Mean of pre-operative and per-operative ISG is 43.13 + 13.87 and 7.50 + 2.67 (Table I), p value is 0.0001, which is statistically highly significant. Here after osteotomy, approximation of pubic bone was done, so ISG was minimum and significant difference of ISG was present between pre-operative and per-operative period. Mean of per-operative and post-operative ISG is 7.50 + 2.67 & 43.13 + 10.33. P value is 0.0001, which is also highly

significant; because re-diastasis of pubic symphysis occurred even after approximations of pubis were done during operation. Finally mean of pre-operative and post-operative ISG is 43.13 + 13.87 and 43.13 + 10.33. p value is 1.00, which is not significant. Due to re-diastasis, pre-operative and post-operative ISG was almost same.

In Group- B (Without osteotomy group): Mean of pre-operative ISG is 48.00 + 13.98 and per-operative is 49.00 + 14.68 (table I), P value is 0.873, which is not significant. Again mean of per-operative ISG is 49.00 + 14.68 and post-operative ISG is 47.00 + 12.95. P value is 0.873, which is not significant. Finally mean of pre-operative ISG is 48.00 + 13.98 and post-operative ISG is 47.00 + 12.95. P value is 0.750, which is not significant.

In this group, as pubic bone approximations were not done, so there was no significant difference of ISG in pre-operative, per-operative and post-operative period.

#### Wound healing:

In Group- A wound healed in four patients (50%) and failed in four patients (50%). In Group- B wound healed in eight patients (80%) and failed in two patients (20%). P value is 0.321, which is statistically not significant.

Total failure indicates complete wound dehiscence and partial failure indicates superficial wound infection.

In Group- A one patient (25%) showed partial failure and three (75%) total failure among four patients. In Group- B among two patients, partial failure occurred in one patient (50%) and total failure occurred in one patient (50%). P value of two groups is 1.000, which is not significant.

**Table I**  
**Comparison of pre operative, per operative and post operative ISG**

Parameters	Pre-operative ISG (mm) (Mean ± SD)	Per-operative ISG (mm) (Mean ± SD)	Post-operative ISG (mm) (Mean ± SD)
With osteotomy group (n=8)	43.13 ± 13.87	7.50 ± 2.67	43.13 ± 10.33
<i>P values</i>			
Pre-operative vs Per-operative		0.0001***	1.000 <sup>ns</sup>
Without osteotomy group (n=10)	48.00 ± 13.98	49.00 ± 14.68	47.00 ± 12.95
<i>P values</i>			
Pre-operative vs Per-operative	0.873 <sup>ns</sup>	0.873 <sup>ns</sup>	0.750 <sup>ns</sup>

ANOVA (Multiple Comparisons); ns= Not significant; \*\*\*= highly significant (P<0.0001)

**Table II**  
*Status of post-operative wound healing*

Status of post-operative wound healing	With osteotomy No. (percentage)	Without osteotomy No. (percentage)	P value
Healed	4 (50.0)	8 (80.0)	0.321 <sup>ns</sup>
Failed	4 (50.0)	2 (20.0)	

Fisher's exact Test; ns= Not significant

### Discussion:

The present study shows that in osteotomy group, per-operative ISG was minimum as approximation of pubic symphysis was done with prolene suture during operation. Post-operatively the ISG became almost same as pre-operative value due to separation of pubis from each other (re-diastasis). In without osteotomy group, pre-operative and post-operative ISG were same, because approximations of pubic symphysis were not done in this group.

Castagnetti et al. (2008) showed in a small number of bladder exstrophy patients who treated with osteotomy and without osteotomy that all patients developed pubic diastases<sup>4</sup>. There were insignificant differences revealed between pre-operative and post-operative median value of ISG in two groups of patients. Our study revealed that there were no significant differences of mean values of ISG in both group of the patients. O'Phelan reported in an acceptable number of the patients that all the bilateral iliac osteotomies developed more or less separation of symphysis pubis<sup>13</sup>.

In spite of immobilization with plaster, all patients of this study developed significant degree of diastasis post-operatively. Jones et al. treated an acceptable number of patients of bladder exstrophy with pelvic osteotomy<sup>9</sup>. All patients developed re-diastasis post-operatively. In the present study, all osteotomy patients developed re-diastasis irrespective of post-operative outcome. Chiari and co-workers reported in a small series of bilateral anterior pubic osteotomy patients that partial re-diastasis occurred regardless the type of osteotomy<sup>5</sup>. So our findings matched with the findings of above authors who worked in this field.

In this study, wound healing was better in without osteotomy patients (80% versus 50%). On the other hand wound failure was more in osteotomy patients (50% versus 20%). Among wound failure, total disruption of the wound was revealed more in osteotomy patients (75% versus 25%).

This study demonstrated that after primary repair with osteotomy and approximation of pubis, all patients developed re-diastasis of pubic symphysis. Post-operative morbidity like pain, prolonged immobilization and hospitalization, plaster related complications were more in this group of patients. Wound failure rates were also more in these patients. On the other hand, wound healing was relatively better in patients who were underwent primary repair without osteotomy. So it may be concluded that there is no extra advantages of osteotomy were observed in two months follow-up after primary repair of bladder exstrophy.

### Conclusion:

The primary repair of bladder exstrophy can be done with osteotomy or without osteotomy. In the present study, early post-operative outcome of the primary repair of bladder exstrophy patients treated with osteotomy and without osteotomy were compared. Primary repair was done in eight patients with osteotomy and in ten patients without osteotomy. In two months follow-up, the intersymphyseal gap and status of wound healing were evaluated. During operation, the pubic symphysis was approximated in osteotomy group but not in without osteotomy group. Post-operatively all osteotomy group developed re-diastasis.

Wound healing was better in without osteotomy group (80% versus 50%). On the other hand, wound failure was more in osteotomy group (50% versus 20%). From this study it was observed and concluded that there is a significant benefit of surgery without osteotomy in terms of wound healing.

So, this study has the scope to say that primary repair of bladder exstrophy can be better without osteotomy.

### References:

1. Baird, AD, Nelson, CP, Gearhart, JP. 'Modern staged repair of bladder exstrophy; A contemporary series', Journal of Paediatric Urology, 2007; 3: pp. 311-15

2. Ben-Chaim, J, Docimo, SG, Jeffs, RD, Gearhart, JP 1996, 'Bladder exstrophy from childhood into adult life', *Journal of the Royal Society of Medicine*, 1996; 89: pp. 39-46
3. Canning DA, Synder, HM. 'Bladder Exstrophy', in Ziegler, M M, AzizKhan, RG and Weber, TR (eds), *Operative Pediatric Surgery*, McGraw Hill Companies, New York, 2003; p. 887-901.
4. Castagnetti M, Gigante C, Perrone G, Rigamonti, W. 'Comparison of musculoskeletal and urological functional outcomes in patients with bladder exstrophy undergoing repair with and without osteotomy'. *Pediatric Surgery International*, 2008; 24: p. 689-93.
5. Chiari, G, Avolio, L, Bragheri R.. 'Bilateral anterior pubic osteotomy in bladder exstrophy repair: Report of increasing success', *Pediatric Surgery International*, 2001; 17: p. 160-63.
6. Ferrer, FA, Gearhart, JP. 'Bladder exstrophy: Consideration & management of the newborn patient', in Puri, P (ed), *Newborn surgery*, 2<sup>nd</sup> edn, Arnold, London, 2003; pp. 619-27.
7. Frey, P, Cohen, SJ. 'Anterior pelvic osteotomy: A new operative technique facilitating primary bladder exstrophy closure', *British Journal of Urology*, 1989; 64: p. 641-43.
8. Gibbon, AJ, Mfulli, N, Fixsen, JA. 'Horizontal pelvic osteotomy for bladder exstrophy', *The Journal of Bone and Joint Surgery*, 1991; 73-B: p. 896-98.
9. Jones, D, Parkinson, S, Hosalkar, HS. 'Oblique pelvic osteotomy in exstrophy/epispadias complex', *The Journal of Bone and Joint Surgery*, 2006; 88-B(6): p. 799-806.
10. Kajbafzadeh, AM, Quinn, FMJ, Ransley, PG. 'Radical single stage reconstruction in failed exstrophy', *The Journal of Urology*, 1995; 154: pp. 868-70.
11. Kelly, JH. 'Vesical exstrophy: Repair using radical mobilization of soft tissues', *Pediatric Surgery International*, 1995; 10: p. 298-304.
12. Mitchell, ME. 'Bladder exstrophy repair: Complete primary repair of exstrophy', *Urology*, 2005; 65: p. 5-8.
13. O'Phelan, EH. 'Iliac osteotomy in exstrophy of the bladder', *The Journal of Bone & Joint Surgery*, 1963; 45: pp. 1409-22.
14. Schaeffer, AJ, Purves, JT, King, JA, Sponsellor PD, Jeffs, RD, Gearhart JP. 'Complications of primary closure of classical bladder exstrophy', *The Journal of Urology*, 2008; 180(4): p. 1671-74.
15. Sponsellor, PD, Bisson, LJ, Gearhart, JP, Jeffs, RD, Magid, D, Fishman, E. 'The anatomy of the pelvis in exstrophy complex', *The Journal of Bone & Joint Surgery Am.*, 1995; 77: p. 177-89.