

## Picture Quiz

---

### A Young Man with Headache & Loss of Vision

MD. MAHMUDUR RAHMAN SIDDIQUI,<sup>1</sup> MD. SHAHRIAR MAHBUB,<sup>1</sup> MOHAMMAD ASHIK IMRAN KHAN,<sup>2</sup>

#### Clinical Presentation

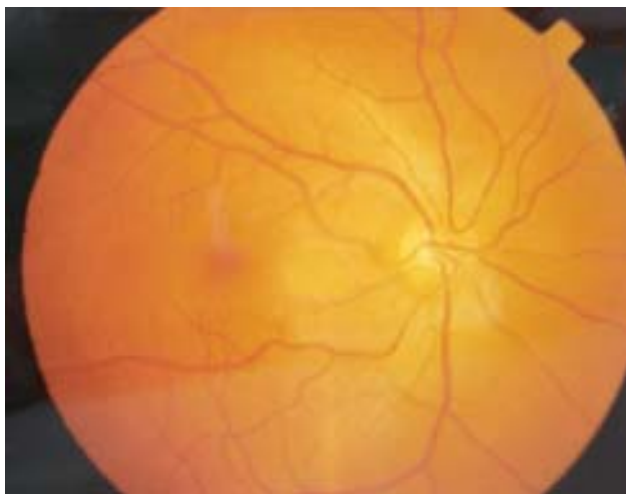
A 30-year-old man presented with headache for 1 month, which was associated with early morning nausea and vomiting for last 20 days. For last 15 days he developed gradual dimness of vision in the left eye. Clinical examination revealed that, he has got emotional lability, right sided extensor plantar reflex. Fundoscopy showed (Fig 1, 2).

#### Questions

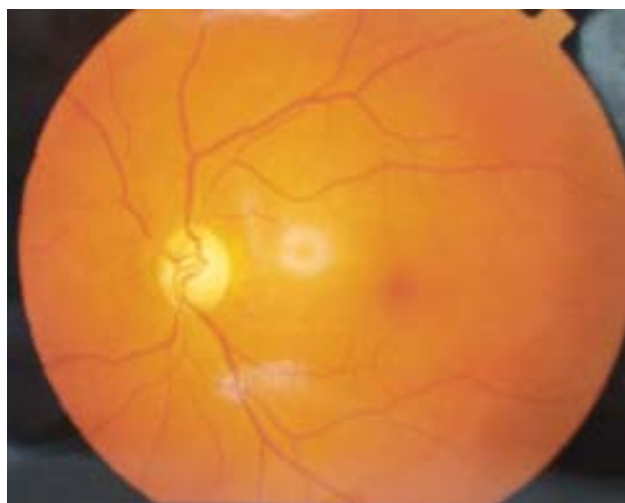1. What are the findings in both pictures?
2. What is the diagnosis?

#### Answer

See page 54 for answer.



**Fig.-1:** Fundus photography of the right eye.



**Fig.-2:** Fundus photography of the left eye.

---

1. FCPS (Medicine) Course, Department of Medicine, Dhaka Medical College.  
2. Postgraduate trainee, Department of Medicine, DMCH.