

## CASE REPORT

# Acute Myocardial Infarction in a Amphetamine Abuser with Low ASCVD Risk: A Case Report

Afroza Ahmed, Afzalur Rahman, Shamsun Nahar, Gulam Mostafa, Nusrat Parvin

### Abstract:

Wide availability of recreational drugs, like amphetamine, cocaine, cannabis etc has spread out these drugs to all classes and age groups in the society of Bangladesh. Among them association cocaine and cannabis with acute myocardial infarction has been well established. But the popular drug, amphetamine, which is available in tablet form containing the active ingredient named 3,4 methylenedioxymethamphetamine (MDMA), has been reported to have significant cardiac and CNS toxicity. Repeated angina, even myocardial infarction due to active coronary vasospasm and accelerated atherothrombosis in amphetamine abusers has been reported in several case studies worldwide. But, only a few cases has been reported in Bangladesh. Here we present a case of acute myocardial infarction in a amphetamine abuser with low 10 years ASCVD risk.

Keywords: Amphetamine, myocardial infarction, ASCVD risk

*J Inv Clin Cardiol* 2023; 5(2): 53-55

### Introduction:

Amphetamine is a variety of recreational drug which has been popular among the young generation throughout the world. Its easy availability and widespread abuse has been involving people of different age groups and Bangladesh is not an exception. Amphetamine is a sympathetic stimulant and has a variety of adverse effect on cardiovascular system.<sup>1</sup> Cases has been reported from various countries which has demonstrated amphetamine induced hypertensive emergencies, acute coronary vasospasm, necrotizing vasculitis, spontaneous coronary artery dissection, aggravated coronary atherosclerosis, raised coronary thrombus burden, acute left ventricular failure, cardiomyopathy, arrhythmia, pulmonary hypertension and sudden cardiac death.<sup>2,3,4</sup> The most popular amphetamine found to be abused 3,4 methylenedioxymethamphetamine (MDMA) and several other varieties. Though cocaine has been well established as causing acute coronary syndrome but the role of amphetamine as a cause of ACS is yet to be established.<sup>5,6</sup>

### Case description

Our patient a 42 years old a chronic substance abuser, came to ER of a tertiary care hospital with the complaints of central compressive chest pain, which

has been radiating to jaw and left arm and associated with sweating and vomiting for few hours. He was a known case of diabetes and hypertension for 1 year with 10 years ASCVD risk 24%. He had been a substance abuser, especially amphetamine for last 3 years. Examination revealed, he was anxious, his pulse was 106/min, regular; BP 140/90 mmHg; S1&S2 normal; lung base clear. Emergency ECG was obtained which revealed acute STEMI inferior. Echocardiography revealed inferior wall hypokinesia. Hs Trop I first sample was negative and 2<sup>nd</sup> sample wasn't tested as the scenario was clearly indicative of acute myocardial infarction. He was thrombolysed with tenecteplase and prepared for coronary angiography. On next morning CAG was done which revealed long segment ulcerated lesion involving proximal to mid RCA along with thrombus burden. Pharmacoinvasive PCI to RCA along with thrombosuction was done. He had history of hospital admission with similar episodes of chest pain at least twice before but during those time his ECG showed sinus tachycardia with hyperacute T wave from V1 to V4, hsTropI was normal, echocardiography showed no wall motion abnormality and CAG revealed normal coronaries. His urine for amphetamine level were negative during his previous admissions. This time he denied any form of substance abuse but his

characteristic coronary lesion triggered high level of suspicion and despite of his denial, urine for drug abuse test was positive for amphetamine and negative for benzodiazepine and cocaine Table 1. His blood sugar was uncontrolled during the period of admission and also had raised HbA1c which means uncontrolled

blood sugar for long. Subsequently the patient was stabilized. DAPT (aspirin & clopidogrel), atorvastatine, beta blocker, amlodipine, enoxaparine, empagliflozine, insulin was administered. Psychological counseling and lifestyle modifications were advised and he was discharged at home after 5 days.

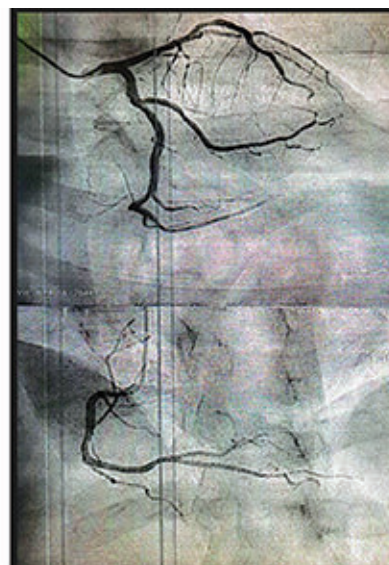
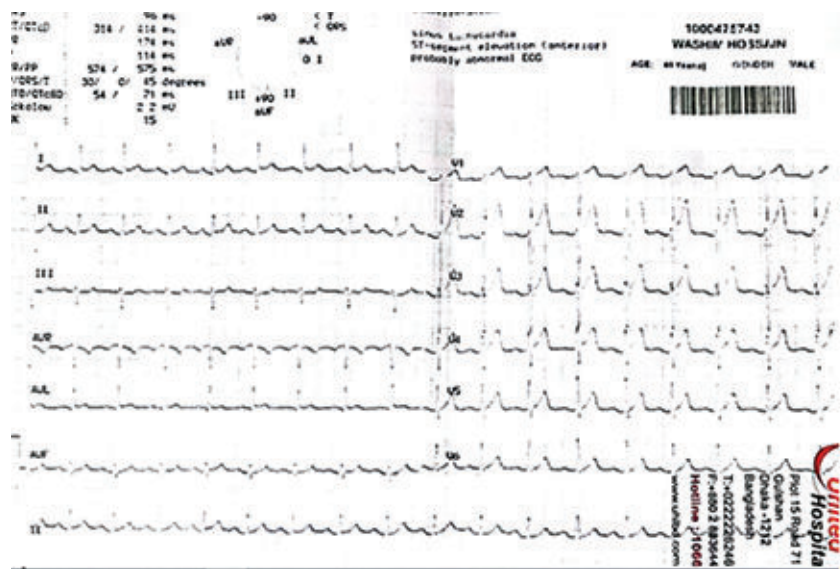


Figure1&2: ECG and angiography

**Table-I**  
Comparing clinical and laboratory parameters in two separate admissions

Patient parameters	Oct 2021	Feb 2023
Hs Tropl	7.5pg/ml	11.3pg/ml
Echo	no RWMA	Inf wall hypokinesia
Angiography	Normal	SVD
RBS	24 mmol/L	20 mmol/L
HbA1c	10g/L	7 g/L
Creatinine	1.2mg/dl	1 mg/dl
Na	133mmol/L	138mmol/L
K	5.5mmol/L	4.8mmol/L
Ca	2.4 mmol/l	2.8 mmol/L
Mg	0.97mmol/L	0.92mmol/L
Hb	17.5 gm/dl	15.8
WBC	7×10 <sup>3</sup>	9.4×10 <sup>3</sup>
Platelet	252×10 <sup>3</sup> /μL	281*10 <sup>3</sup> /μL
NTproBNP	15pg/ml	229pg/ml
Ferritin	199μg/L	not done
Urine amphetamine	negative	positive
Urine benzodiazepines	not done	negative
Urine cocaine metabolites	not done	negative

**Discussion:**

Characteristic chest pain, in a patient with low ASCVD risk, who has a history of recreational amphetamine abuse must raise the suspicion of acute myocardial infarction. Amphetamine stimulates norepinephrine release from sympathetic nerve ending. Norepinephrine stimulates alpha 1 adrenoceptor and eventually promotes coronary vasospasm.<sup>1</sup> Amphetamine also enhances reactive oxygen species production and eventually myocardial damage. It also enhances structural and electric remodeling of cardiac muscle and leads to arrhythmia. Patients who used to take amphetamine, may have repeated anginal attack due to coronary vasospasm and angiography may be normal in those cases. Amphetamine promotes endothelial release of endothelin 1, reduce NO sensitivity and coronary smooth muscle dysfunction.

Amphetamine also enhances pro-inflammatory process by increasing IL1, IL6 release and aggravates platelet aggregation and thrombus formation.<sup>7</sup> Thus aggravated atherosclerotic process has been reported in young amphetamine abusers compared to age matched group in different studies.<sup>10</sup> Atherosclerotic plaque in laboratory mouse treated with methamphetamine has been found to have smooth muscle apoptosis and reduced extracellular matrix deposition, for which the plaques are more unstable and vulnerable to rupture.<sup>8</sup>

Our patient had known cardiovascular risk factors like uncontrolled diabetes and hypertension. But from his last medical records, it was known that, when he came to ER with typical angina for the first time 1 year back, he was newly diagnosed as diabetic and hypertensive. During that admission his angiography was also normal. So, the chest pain occurred that time is guessed to be due to coronary vasospasm. Moreover conventional coronary artery disease risk factors like diabetes and hypertension promotes lipid rich atherosclerotic plaque formation but amphetamine aggravates the atherosclerotic process.<sup>9</sup> Our patient who had normal coronaries 1 year back, was now found to have severe narrowing of RCA with ulcerated lesion with thrombus burden which raises the possibility of amphetamine induced aggravated atherosclerosis, coronary dissection and thrombus formation.<sup>10</sup>

Our patient had urine for amphetamine level positive this time which was negative during earlier admissions. Amphetamine persists in urine for 2 to 3 days, and after that the assay may be negative.<sup>11</sup>

Finally, this rare case of amphetamine induced coronary artery lesion and acute MI, indicated a newer emerging epidemic of heart attack in young patient. So, toxicology analysis is a mandatory in young patient with angina. Coronary angiogram is also an utmost necessity in those cases. Reporting these type of cases in medical journals will help to build awareness among general people and medical practitioners.

**References :**

1. Bashour TT. Acute myocardial infarction resulting from amphetamine abuse: A spasm-thrombus interplay? *Am Heart J.* 1994;128(6 PART 1):1237–9.
2. Kevill CG, Goeders NE, Woolard MD, Bhuiyan MS, Dominic P, Kolluru GK, et al. Methamphetamine Use and Cardiovascular Disease. *Arterioscler Thromb Vasc Biol* [Internet]. 2019 Sep 1 [cited 2023 May 6];39(9):1739–46. Available from: <https://www.ahajournals.org/doi/abs/10.1161/ATVBAHA.119.312461>
3. MacMahon MJ, Tallentire VR. Stimulating stuff: The pathological effects of cocaine and amphetamines on the cardiovascular system. *Br J Diabetes Vasc Dis.* 2010 Sep;10(5):251–5.
4. Jacobs W. Fatal amphetamine-associated cardiotoxicity and its medicolegal implications. *Am J Forensic Med Pathol.* 2006 Jun;27(2):156–60.
5. Waksman J, Taylor RN, Bodor GS, Daly FFS, Jolliff HA, Dart RC. Acute myocardial infarction associated with amphetamine use. *Mayo Clin Proc.* 2001;76(3):323–6.
6. Watts DJ, McColleston L. Methamphetamine-induced myocardial infarction with elevated troponin I [2]. *Am J Emerg Med.* 2006 Jan;24(1):132–4.
7. Gebhard C, Breitenstein A, Akhmedov A, Gebhard CE, Camici GG, Lüscher TF, et al. Amphetamines induce tissue factor and impair tissue factor pathway inhibitor: Role of dopamine receptor type 4. *Eur Heart J.* 2010 Jul;31(14):1780–91.
8. Bo Gao, Lun Li, Pengfei Zhu, Mingjing Zhang, Lingbo Hou, Yufei Sun, Xiaoyan Liu, Xiaohong Peng YG. Chronic administration of methamphetamine promotes atherosclerosis formation in ApoE<sup>-/-</sup> knockout mice fed normal diet. *Atherosclerosis.* 2015;243(1):268–77.
9. Brennan K, Shurmer S, Elhendy A. Coronary artery rupture associated with amphetamine abuse. *Cardiol Rev.* 2004 Sep;12(5):282–3.
10. Haft JI, Kranz PD, Albert FJ, Fani K. Intravascular platelet aggregation in the heart induced by norepinephrine. Microscopic studies. *Circulation.* 1972;46(4):698–708.
11. Alghamdi M, Alqahtani B, Alhowti S. Cardiovascular complications among individuals with amphetamine-positive urine drug screening admitted to a tertiary care hospital in Riyadh. *J Saudi Hear Assoc.* 2016 Jul 1;28(3):129–35.