

Laparoscopic Hand-Sewn Duodenojejunostomy for Superior Mesenteric Artery Syndrome Using 3D-4K Image - A Case Study

JH BHUIYAN^a, F BEGUM^b, MA HOSSAIN^c

Abstract:

Background: Superior mesenteric artery (SMA) syndrome, also known as wilkie's syndrome, is a rare condition characterized by vascular compression of third part of the duodenum that leads to duodenal obstruction. Traditionally, open or laparoscopic stapled duodenojejunostomy is recommended when conservative management failed. We report a 3D-4K image hand-sewn duodenojejunostomy (DJ) for the treatment of SMA syndrome.

Materials and Methods: A 13 years old patient presented with anorexia, post prandial vomiting, dull abdominal pain & weight loss for 6 years. Upper GI endoscopy revealed duodenal stenosis and Barium follow through demonstrated obstruction to the third part of the duodenum. Ultrasound examination revealed gastric & duodenal dilatation. With these clinical and radiological findings, the diagnosis of SMA syndrome was suspected. He was identified as a candidate for a duodenojejunostomy. 3D-4K image system was used for superior image quality and binocular depth perception and a laparoscopic hand-sewn duodenojejunostomy performed on september 20, 2020

Introduction:

SMA syndrome is an uncommon condition resulting from 3rd part of duodenal obstruction caused by extrinsic compression of the duodenum that creates reduction of the angle formed between the SMA and the aorta.¹ Symptoms are typically chronic and intermittent and include nausea, vomiting, abdominal distention, and post-prandial epigastric pain, with resultant weight loss. The compression may occur in the setting of a narrowed

Results: Diagnostic laparoscopy detected SMA syndrome. Laparoscopic hand-sewn duodenojejunostomy took 120 minutes time. There were no intraoperative complications. The blood loss was minimum. The postoperative course was uneventful with resolution of duodenal obstruction. The patient discharged on 6th postoperative day. He gained 10 kg weight 6weeks after surgery.

Conclusion: 3D-4K image laparoscopic hand-sewn duodenojejunostomy as a surgical option for the treatment of SMA syndrome is safe, cost effective, feasible, and valid alternative to open and laparoscopic stapled technique with added benefits of a minimally invasive approach. Additionally hand-sewn anastomosis ensures good tissue approximation. Of course it is time consuming and needs expertise in intracorporeal suturing. 3D-4K image technology makes this difficult procedure easier.

Keywords: SMA syndrome, laparoscopic duodenojejunostomy, Hand-Sewn, 3D-4K image.

(J Bangladesh Coll Phys Surg 2022; 40: 68-71)
DOI: <https://doi.org/10.3329/jbcps.v40i1.57062>

- Dr. Md. Jahangir Hossan Bhuiyan, Associate Professor, Department of Surgery, Cumilla Medical College, Cumilla
- Dr. Farhana Begum, Senior Consultant, Gynae, Cumilla Medical College Hospital, Cumilla
- Dr. Mohammad Anwar Hossain, Junior Consultant Surgery, Cumilla Medical College Hospital, Cumilla

Address of Correspondence: Dr. Md. Jahangir Hossan Bhuiyan, Associate Professor, Department of Surgery Cumilla Medical College, Cumilla, Bangladesh, Mobile: +8801712251060, e-mail: dr.jhbhuiyan@yahoo.com

Received:

Accepted:

aortomesenteric angle, abdominal compression by a cast or girdle, or it may be categorized as idiopathic.^{2,3,4} Some authors have suggested a genetic predisposition.⁵ Patients are usually young, and women are affected more often than men. Surgical therapy is indicated when conservative management fails. Historically, surgery has entailed laparotomy with duodenojejunostomy.^{6,7} Other technical approaches includes lysis of the ligament of Treitz or gastrojejunostomy which may be less effective, a DJ is required if these fails. Now, advances in laparoscopic skills have enabled surgeons to perform DJ laparoscopically. The advantage of performing laparoscopic DJ using a minimally invasive approach are clear and include fewer wound complications, quicker return to bowel function, less pain than the open operation and a quicker recovery to normal activities for the patient.^{8,9} Herein, we describe the operative technique for a laparoscopic hand-sewn DJ using 3D-4K image system in a patient with an external compression of the duodenum by the SMA.

Case Report:

The patient was a thin 13 years old boy with history of nausea, bilious vomiting, dull abdominal pain and weight loss for 6 years. Upper GI endoscopy revealed duodenal stenosis and Ba follow through demonstrated obstruction of the third portion of the duodenum with marked dilatation proximally. With these clinical and radiological findings, the diagnosis of SMA syndrome was assumed. The patient did not improve with conservative management and subsequently surgical consultation and operation was requested. After thorough evaluation, the patient was taken to the operating room for laparoscopic hand-sewn duodenojejunostomy. 10mm sub umbilical port was placed for 3D binocular telescope. Two 5mm port lateral to umbilicus in the midclavicular line and one 5mm port in rt subcostal region in the anterior axillary line were placed. Diagnostic laparoscopy revealed stomach, first and second part of duodenum notably dilated while jejunum appeared to be normal. Superior mesenteric vessels were found prominent and crossing anterior to third part of duodenum. No masses found in the duodenum or head of the pancreas. The ligament of Treitz was identified and a portion of the proximal jejunum, approximately 30cm distal to the ligament of Treitz, was selected and brought closure to the second part of the duodenum for anastomosis. Two stay suture were placed between second part of the duodenum and jejunum 7cm apart holding these two portion of the bowel in apposition. Duodenotomy and jejunotomy were made

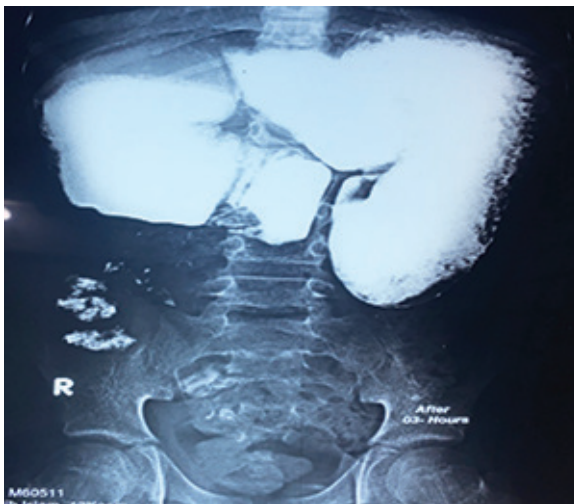

Fig-1: Ba follow through: obstruction to the 3rd part of duodenum

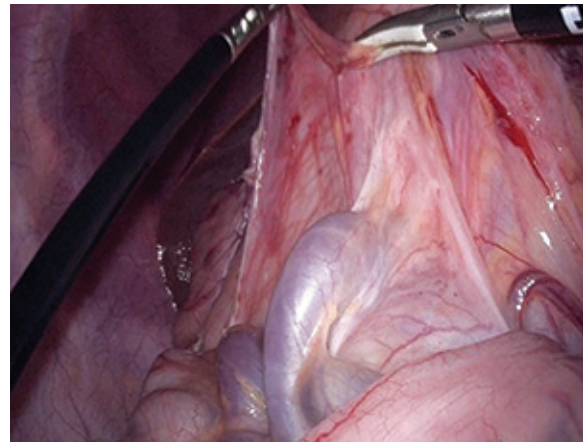


Fig-2: Laparoscopic view of SMA crossing 3rd part of duodenum

using diathermy hook. 5cm DJ done using 2/0 vicryl suture in four layer fashion. First and fourth layer were continuous suture and 2nd and 3rd layer were continuous interlocking suture. 3D-4K image system played a great role in easy intracorporeal suturing. The whole procedure

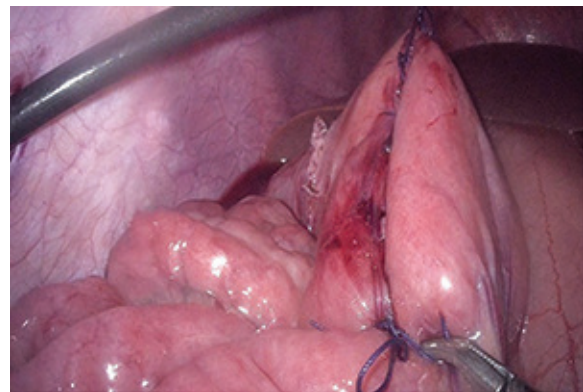


Fig-3: 1st layer of hand-sewn DJ

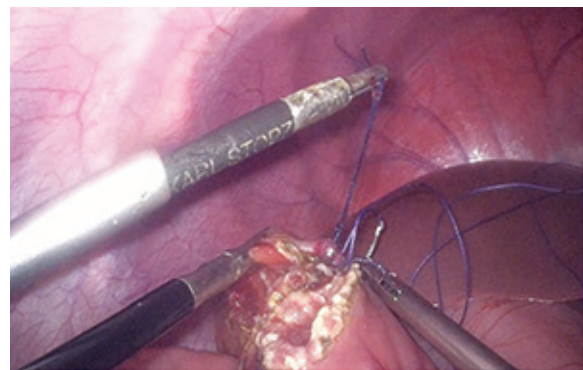


Fig-4: Duodenotomy & jejunotomy

took 120 minutes time. The patient did well postoperatively and was ambulating the morning after surgery. NG tube removed and oral diet started on 5th postoperative day. Patient discharged on 7th postoperative day.

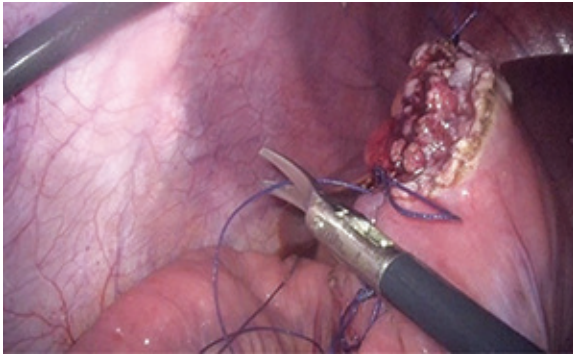


Fig.-5: 2nd layer of hand-sewn DJ

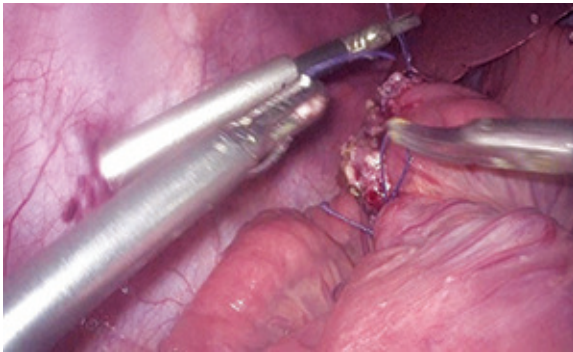


Fig.-6: 3rd layer of hand-sewn DJ

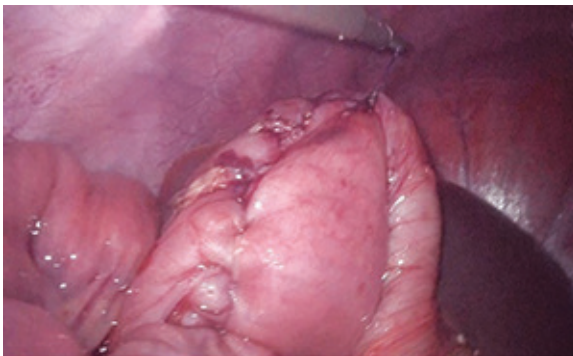


Fig.-7: 4th layer of hand-sewn DJ

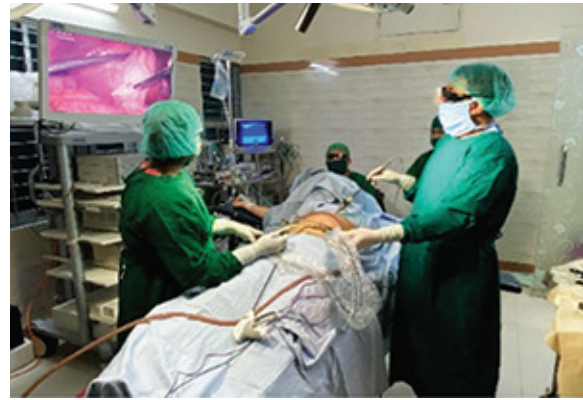

Fig.-8: Operating set-up with 3D camera, 3D goggles & 4K monitor

Discussion:

Von Rokitsky first described SMA syndrome in 1861.¹⁰ It is a rare condition with an incidence of 0.013% - 0.3%.¹¹ SMA syndrome has a specific anatomic basis. The SMA originates from the anterior aspect of the aorta at L1- L2 vertebral level and descends downwards at an acute angle of approximately 45° (range 38°-60°) and a distance of 10-28mm.¹² The duodenum crosses the middle at the level of the L3 vertebra in the distance between SMA and aorta. Thinning out of the fat pad between the aorta and SMA, consequently upon weight loss, narrows the aortomesenteric angle as well as the distance between them, causing compression of the duodenum. The classical diagnostic criteria are a dilated proximal duodenum and an aortomesenteric angle of < 20° with the aortomesenteric distance reduced to 8mm.¹³ Treatment options for SMA syndrome involve medical management using tube feedings to increase both weight and the mesenteric fat pad.¹⁴ If symptoms persist, surgical options for treatment can include less accepted methods of severing the ligament of Treitz or gastrojejunostomy. More accepted standard duodenojejunostomy bypass, have been proposed by Wilkie et al, in the largest series on 75 patients.¹¹ This procedure has traditionally been performed in an open and laparoscopic approach.^{11,15} More recently, robotic duodenojejunostomy has been utilized with success.¹⁶ Butter et al¹⁷ recently reported the treatment of a patient with SMA syndrome by a hand- sewn robotic duodenojejunostomy side to side anastomosis with good result. Herein, we describe a 3D-4K image laparoscopic hand sewn duodenojejunostomy side to side anastomosis with good result. Hand sewn technique

is cost effective and good for low socioeconomic patient. Using 3D-4K image system we experienced 4 times resolution of HD, superior depth perception, greater image definition, more realistic and life like view. Mental work load and operating time also less using 3D-4K image technology. Gomez –Gomez E et al also experienced less time and mental workload using 3D-4K technology in their study of laparoscopic Surgery.¹⁷ We also experienced increased personal felt safety and task efficiency using this most modern image technology which is correlate with the study done by Buia A et al.¹⁸

Conclusion: SMA can be added to the growing list of disorders that can be successfully treated laparoscopically. 3D-4K image hand-sewn duodenojejunostomy as a surgical option for the treatment of SMA syndrome is safe, cost effective, feasible, and valid alternative to open and laparoscopic stapled technique with added benefits of a minimally invasive approach. Additionally hand-sewn anastomosis ensures good tissue approximation. Of course it is time consuming and needs expertise in intracorporeal suturing.

References:

1. Subhashin M, Mario A et al. Robotic Roux-en-Y Duodenojejunostomy for superior Mesenteric Artery syndrome: Operative Technique. *Journal of Laparoendoscopic and Advanced Surgical Techniques*. 2011; 21(9):841-844.
2. Stavely Al. Acute and chronic gastromesenteric ileus with cure in a chronic case by duodenojejunostomy. *Bull John Hopkins Hosp*.1908; 19:252.
3. Mansberger AR, Byers RM et al. Vascular compression of the duodenum. Emphasis on accurate diagnosis. *Am J Surg*.1968; 115:89-96.
4. Lukes PJ, Rolny P et al. Diagnostic Value of hypotonic duodenography in superior mesenteric artery syndrome. *Acta Chir Scand*. 1978; 144:39-43.
5. Ortiz C, Cleveland RH et al. Familial superior mesenteric artery syndrome. *Pediatr Radiology*. 1990;20: 588-589.
6. Kalouche I, Leturgie C et al. The superior mesenteric artery syndrome: apropos of a case and review of the literature. *Ann chir* 1991;45: 609.
7. Pool EH, Niles WL et al. Duodenal status: Duodenojejunostomy for superior mesenteric artery syndrome. *Ann Surg* 1933 ; 98: 587.
8. Fraser JD, Hughes JH et al. Laparoscopic duodenojejunostomy for superior mesenteric artery syndrome *JLS* 2009; 13: 254-259.
9. Morris TC, Devitt PG et al. Laparoscopic duodenojejunostomy for superior mesenteric artery syndrome – how I do it. *J Gastrointest Surg* 2009;13: 1870-1873.
10. Von Rokitsansky C. *Lehrburch der Pathologischen Anatomie* Vienna, Austria: Raumuller and seidel, 1861.
11. Baltazar U, Dunn J et al. superior Mesenteric Artery syndrome: An uncommon cause of intestinal obstruction. *South Med J* 2000;93: 606-608.
12. Ozkurt H, Cenker MM et al. Measurement of the distance and angle between the aorta and superior mesenteric artery: normal values in different BMI categories. *Surg Radiol Anat* 2007;29(7): 595-9.
13. Jo JB, Song KY et al. laparoscopic duodenojejunostomy for superior mesenteric artery syndrome. *Repost of a case. Surg Laprosc Endosc Percutan Tech* 2008;18: 213-215.
14. Merrett ND, Wilson RB et al. superior mesenteric artery syndrome: Diagnosis and treatment strategies. *J Gastrointest Surg* 2009; 13: 287-292.
15. Munene G, Knab M et al. laparoscopic duodenojejunostomy for superior mesenteric artery syndrome. *Am Surg* 2010;76: 321-4.
16. Ayloo SM, Masrur MA et al. Robotic Roux-en-Y duodenojejunostomy for superior mesenteric artery syndrome: Operative technique. *J Laparoscopic Adv Surg Tech* 2011;21(a): 841-4.
17. Gomez-Gomez E, Corrasco – Valiente J et al. Impact of 3D version on mental workload and Laparoscopic performance in inexperienced Subjects. *Actas Urol ESP* 2015 May;39(4): 229-35.
18. Bui A, Stockhausen F et al. 2D vs 3D imaging in laparoscopic Surgery-results of prospective randomized trial. *langenbechs Arch Surg* 2017 Dec;402(8): 1241-1253.