

# Parahaemophilia: A Rare Case Report

MN BHUIYAN<sup>a</sup>, S GITI<sup>b</sup>, AA KHAN<sup>c</sup>, MM RAHMAN<sup>d</sup>, MA KARIM<sup>e</sup>

### Abstract :

*Parahaemophilia or Owren's disease is a rare haemorrhagic disorder that occurs due to congenital and frequently familial deficiency of Factor V. It is characterized by epistaxis, bruising, mucosal bleeding, soft tissue bleeding and haemarthrosis. We report a case of a 6-year-old female patient with overlapping features with other haemorrhagic disorders. With the complaints of recurrent episodic per rectal bleeding, the patient was evaluated at different hospitals in Chattogram and was diagnosed as a case of Haemophilia B and treated accordingly. As her condition was not improved as expected, she was referred to Armed Forces*

*Institute of Pathology (AFIP) for further evaluation. The lab tests showed prolongation of prothrombin time (PT) and activated partial thromboplastin time (APTT), with normal bleeding time (BT) and thrombin time (TT). Coagulation factors assay revealed a significant decrease of factor V, 1% of normal range. Other coagulation factors are normal. She was treated with FFP and recovered four weeks after treatment.*

**Key word:** Autosomal Recessive Disorder, FFP-Fresh Frozen Plasma, Parahaemophilia, RICD-Rare Inherited Coagulation Disorder.

(*J Bangladesh Coll Phys Surg 2020; 38: 205-208*)

DOI: <https://doi.org/10.3329/jbcps.v38i4.48985>

### Introduction:

Parahaemophilia is a rare inherited coagulation disorder (RICD) which affects both sexes. Factor V deficiency was first described in a Norwegian patient in 1943 and reported by Dr. Paul Owren in 1947.<sup>1</sup> The hereditary factor V deficiency is very rare, and probably fewer than 500 patients affected worldwide have been reported since its discovery in 1943. Prevalence of homozygous forms is estimated at 1/1,000,000.<sup>3,4</sup> Bleeding diathesis and the concentration of plasma factor V in patients with

factor V deficiency was not as well related as plasma factor level. Miletich et al. have proposed that platelet factor V level as much better correlated with bleeding symptoms.<sup>5</sup> Congenital Factor V deficiency is caused by mutations in the *F5* gene (1q23) controlling the production of plasma Factor V. Transmission is autosomal recessive.<sup>6,7</sup>

Congenital Factor V deficiency can manifest at any age, with the most severe forms manifesting early in life. Common clinical signs include epistaxis, bruising, mucosal bleeding, soft tissue bleeding and haemarthrosis. Excessive and prolonged bleeding during or following surgery, delivery or trauma are frequent. Women may present with menorrhagia. In severe forms of the disease, there can be a risk of intracranial, pulmonary or gastrointestinal bleedings. The severity of the bleeding manifestations correlates with the Factor V levels.<sup>8</sup>

We are reporting a case of a 6-year-old female patient with features overlapping with other haemorrhagic disorders. This paper aimed at bringing awareness to health professionals of this rare congenital disorder in the Bangladeshi population.

### Case report:

A 6-year-old young girl of consanguineous parents presented on 21 January 2020 with recurrent episodes

- Lieutenant Colonel Mohammed Nuruzzaman Bhuiyan, MBBS, MCPS, DCP (DU), FCPS (Haematology), Classified Specialist in Pathology, AFIP, Dhaka Cantonment.
- Major General Susane Giti, MBBS, MCPS, FCPS (Haematology), MMed (BSMMU), Classified Specialist in Pathology, Commandant, AFIP, Dhaka Cantt
- Brig Gen Arif Ahmed Khan, MBBS, MCPS, FCPS (Microbiology), Classified Specialist in Pathology, Deputy Commandant, AFIP, Dhaka Cantonment.
- Lieutenant Colonel Md Moshir Rahman, MBBS, MCPS, DCP, FCPS (Haematology), Classified Specialist in Pathology, AFIP, Dhaka Cantonment.
- Major Md Anwarul Karim, MBBS, AFMI, Dhaka Cantt.

**Address of Correspondence:** Lt Col Mohammed Nuruzzaman Bhuiyan, MBBS, MCPS, DCP (DU), FCPS (Haematology), Classified Specialist in Pathology, AFIP, Dhaka Cantonment. E-mail: [drnuruzzaman4@gmail.com](mailto:drnuruzzaman4@gmail.com), Mob: 01769101147.

Received: 31 May, 2020

Accepted: 08 September, 2020

of bleeding per rectum for 1 month which was painless and occasionally mixed with stool. The patient developed gradual worsening of generalized weakness and easy fatigability for same duration. There are ecchymosis on different parts of the body present since birth, intermittent in nature, aggravates after minor injury and resolves spontaneously. Patient had history of occasional nasal bleeding since birth which aggravates after minor injury and nose pricking. She has a positive family history of bleeding disorder. She is the fourth issue of consanguineous parents. Her eldest sister died at the age of 17 years due to excessive bleeding, the cause of which was undiagnosed. Her uncles and cousins of both side have no such type of illness. Initially she was evaluated at different hospitals in Chattagram and ultimately was diagnosed a case of Haemophilia B as her lab findings of factor IX assay revealed deficiency. Then she was treated accordingly. As her condition did not improve, she was suspected as a case of von Willebrand Disease at Dhaka Medical College Hospital (DMCH). After that patient was referred to AFIP for further detailed evaluation. There was no history of joint swelling, gum bleeding, bony tenderness or fever. Her bladder habit was normal. On general examination, she was found anaemic with multiple ecchymosis on both lower limb. Systemic examination revealed no abnormality.

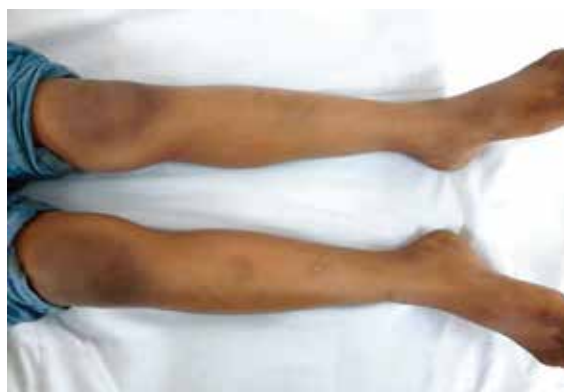

Fig-1: Photograph of the ecchymosis on patient's lower limbs.

Laboratory findings of complete blood count (CBC) and peripheral blood film (PBF) revealed microcytic hypochromic anaemia, possibly iron deficiency anaemia.

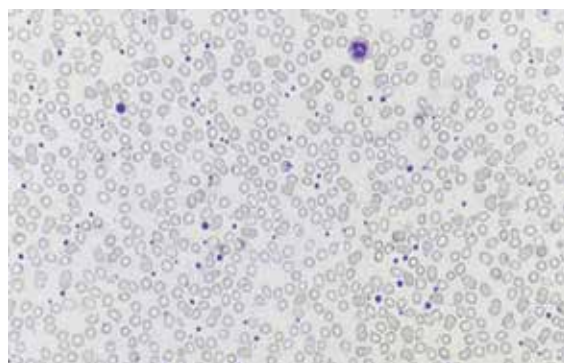


Fig-2: Peripheral Blood Film (40X)

Her relevant lab reports have been tabulated in table-1

Table-1

Investigations details of reported case			
Date	Test	Result	Ref value
<b>Coagulation profile</b>			
17.01.2020	Bleeding time	02 min 30 sec	2-8 minutes
17.01.2020	Coagulation time	08 minutes	5-11 minutes
18.02.2020	Prothrombin time:		
	Control	13.0 Seconds	
	Patient	<b>36.0 Seconds</b>	
	Index	100%	ISI 1.05
	Ratio	<b>2.77</b>	

	INR	<b>2.91</b>	
<b>18.02.2020</b>	APTT:		
	Patient	<b>93 Seconds</b>	
	Control	31 Seconds	
<b>18.02.2020</b>	Thrombin time	18 Seconds	14-18 Seconds
<b>18.02.2020</b>	Von Willebrand Ag	114%	50-160%
<b>18.02.2020</b>	Mixing study	50:50 mixture, Normal	

**Factor assay:**

	Factor VIII	124%	60-150%
	Factor IX	85%	60-150%
	Factor X	72%	70-120%
<b>18.02.2020</b>	<b>Factor V</b>	<b>01%</b>	<b>70-140%</b>
	Protein C	82%	70-140%
	Protein S	111%	70-140%
	Fibrinogen	359 mg/dl	200-400 mg/dl

**Comment: Severe Factor V deficiency.**

**Serum Iron profile:**

	S. Iron	<b>15 µgm/dL</b>	37-145µgm/dL
<b>18.02.2020</b>	S. Ferritin	<b>4.0 ng/ml</b>	6.0-159.0 ng/ml
	TIBC	<b>512 µgm/dL</b>	250-450 µgm/dL

On the basis of history, clinical examinations and laboratory investigations- a diagnosis of Parahaemophilia was made. Patient was treated with FFP and haematinics. Two weeks later, follow up physical examination and investigations showed disappearance of ecchymosis, stoppage of per rectal bleeding and epistaxis with factor v level increasing up to 20% of normal range. She completely recovered after 04 weeks having factor V level 30% and has been followed up at the out patient department. Family screening of other family members revealed no coagulation abnormality. Due to non-availability, mutation study was not performed.

**Discussion:**

In 1943, Owren described a female patient who had a bleeding diathesis attributable to the lack of single blood clotting factor, namely factor V or labile factor. Owren designated the disease "parahemophilia," to emphasize the clinical similarity to hemophilia. At that time, only four coagulation factors were considered: fibrinogen, calcium, prothrombin, thrombokinase. After owren reported parahemophilia,

it was soon found that labile factor and factor V were one and same factor.<sup>1,3</sup>

The coagulation factors that function as enzymatically active serine protease activators, factor VIII and factor V, are cofactors in the coagulation cascade. Activated factor V is a cofactor in the conversion of prothrombin to thrombin by factor Xa in an action that are phospholipid and calcium dependent. The activator complex formed by factor Xa, activated factor V, phospholipid and calcium was called the prothrombinase complex. Activation of factor V by thrombin is achieved through a series of proteolytic cleavages. Activated factor V was inactivated by activated protein C in a surface dependent reaction that requires calcium ion and protein S.<sup>9</sup>

Our patient presented with history and features which overlapped with the features of Haemophilia B and Von Willebrand Disease. These overlapping features posed a diagnostic dilemma. Parahaemophilia is a milder disorder than other congenital haemorrhagic disorder. Even though patient may develop

complications, like anaemia. If not timely diagnosed; it would have been fatal.

Factor V is labile coagulation factor which appears to be necessary both for the production of fully potent intrinsic thromboplastin and for the rapid conversion of prothrombin to thrombin in the presence of tissue thromboplastin. Thus, the patients with Factor V deficiency manifest impaired thromboplastin generation and prolongation of prothrombin time.<sup>10</sup>

Diagnosis is based on prolonged prothrombin (PT) and activated partial thromboplastin times (APTT) and on low plasma Factor V levels. Bleeding time (BT) can be prolonged in severe cases.<sup>11</sup>

Differential diagnoses include vWD, Haemophilia (homozygous type), inhibitors to coagulation factor, and very rarely combined deficiency of factor V and factor VIII.

The level of factor V activity in the patients' plasma is usually < 5% of that in normal plasma. Most bleeding episodes in patients with factor V deficiency can be treated with sufficient fresh frozen plasma to raise the plasma factor V level to 30%.<sup>12</sup>

Fresh frozen plasma (FFP) is the only treatment as Factor V concentrates are not available. In acute cases of severe bleeding, the addition of platelet concentrates may be helpful. Prognosis is good with early diagnosis and adequate treatment.<sup>8, 13</sup>

#### Conclusion:

This is the first reported case on Parahaemophilia in Bangladesh. Parahaemophilia is a very rare inherited coagulation disorder. If not investigated thoroughly, patients can be misdiagnosed. Screening test and associated coagulation factor assay should be done for proper diagnosis. Although factor V deficiency is a milder disorder than Haemophilia A/B, patients with factor V deficiency may sometimes require replacement therapy. With proper treatment; prognosis is good. If untreated, it can be fatal.

#### References:

- Owren PA: Parahaemophilia, Hemorrhagic Diathesis Due to absence of previously unknown clotting factor. *Lancet* 1947;5:446-448. [https://doi.org/10.1016/S0140-6736\(47\)91941-7](https://doi.org/10.1016/S0140-6736(47)91941-7)
- Charles WB: Parahaemophilia (Congenital Factor V Deficiency). *Can Med Assoc J.* 1965; 92:979-981.
- Gilbert C, White II. Coagulation factors V and VIII Normal function and clinical disorder. In: Robert IH, Samuel EL, Thomas PS, eds. *Blood, Principles & practice of Hematology.* 1995;1151-1179.
- Ruth AS: Parahaemophilia. *Medical Clinics of North America* 1972;56:119-125. [https://doi.org/10.1016/S0025-7125\(16\)32427-0](https://doi.org/10.1016/S0025-7125(16)32427-0)
- Miletich JP, Majerus DW, Majerus PW. Patients with congenital factor V deficiency have decreased factor Xa binding sites on their platelets. *J Clin Invest* 1978;62:824-831. <https://doi.org/10.1172/JCI109194>, PMID:701480; PMCID:PMC371834
- Moret A: Next generation sequencing in bleeding disorders: two novel variants in the F5 gene (Valencia-1 and Valencia-2) associated with mild factor V deficiency. *J Thromb Thrombolysis* 2019 Nov;48(4). <https://doi.org/10.1007/s11239-019-01911-z>, PMID:31267299
- Ding H: Phenotypic and genetic analysis of a pedigree affected with hereditary FV deficiency due to a novel deletion variant of F5 gene. *Zhonghua Yi Xue Yi Chuan Za Zhi* 2019 Nov; 36(11).
- Tabibian S: A Comprehensive Overview of Coagulation Factor V and Congenital Factor V Deficiency. *Semin Thromb Hemost* 2019 July; 45(5). <https://doi.org/10.1055/s-0039-1687906>, PMID:31121608
- Desage S: The potential value of thrombin generation assay in the diagnosis of FV inhibitors. *Int J Lab Hematol* 2019 Oct; 41(5). <https://doi.org/10.1111/ijlh.13027>
- Billoir P: Thrombin generation assay is a useful pre-operative tool to predict non-bleeding risk in a patient with mild factor V deficiency. *Transfus med* 2020 Apr 6. <https://doi.org/10.1111/tme.12680>, PMID:32250000
- Walker FJ, Sexton PW, Esmon CT. The inhibition of blood coagulation by activated protein C through the selective inactivation of activated factor V. *Biochim Biophys Acta* 1979;71:333-342. [https://doi.org/10.1016/0005-2744\(79\)90103-7](https://doi.org/10.1016/0005-2744(79)90103-7)
- William HK, Earl WD. Blood coagulation Factor V and VIII: Structural and Functional Similarities and Their Relationship to Hemorrhagic and Thrombotic Disorders. *Blood* 1988;71:539-555. <https://doi.org/10.1182/blood.V71.3.539>. bloodjournal713539
- Takemoto K: Challenges in management of unusual acquired factor V deficiency: A case report. *Medicine (Baltimore)* 2019 Apr; 98(7). <https://doi.org/10.1097/MD.00000000000015259>. PMID:31027075 PMCID:PMC6831250