Original Article

Overcoming Dogear of Lateral End of Mastectomy Wound By Y-Closure Technique: Our Experience

Sadia Armin Khan[1], Taposhi Rabeya Khan[2], Mohammad Jahangir Alam[3]

Abstract

Introduction: The improvement in the treatment of breast cancer is due to early diagnosis, better understanding of the natural history of this disease and therapeutic improvements over the years. There is a gradual shift away from radical surgery to the breast conservative surgery during the last few decades all over the world. Till now modified radical mastectomy is the most common surgery performed by surgeons for carcinoma breast.

Objective: This study aims to evaluate a technique of mastectomy wound closure designed to maximize cosmesis at the lateral end.

Methods: As a surgical technique, patients were evaluated according to NCCN guidelines, and all underwent modified radical mastectomy using a transverse Stewart incision. After achieving hemostasis, closure was planned. At the lateral end, equal markings were made on the superior and inferior flaps based on redundant skin over the latissimus dorsi. A triangular flap was advanced medially, three points sutured, residual dog ears excised, producing a Y-shaped closure. This procedure was performed in 31 cases between January 2024 to June 2025 those were undergone modified radical mastectomy by Stewart incision.

Result: The patient's mean age was 46 years (range 28-62 years). The mean weight of the excised breast tissue was 1015 g (range 356–2003). The mean lengths of the two limbs of the Y-plasty were 5.3 cm (range 3–10). The mean length of the base of the flap was 7.6 cm (range 4–14). 9 patients developed a small area of skin necrosis at the apex of the Y-plasty. 8 further patients developed superficial wound infections following marginal flap necrosis and 3 patients developed wound hematoma.

Conclusion: The Y-shaped closure approach (y-closure) for modified radical mastectomy is a simple and safe technique. It improves cosmesis and prevents discomfort in obese women by eliminating lateral dog ear deformity.

Keywords: Mastectomy; Dog ear; y-shaped closure.

1. Associate Professor, Department of Surgery, Holy Family Red Crescent Hospital, Dhaka, Bangladesh
2. Professor, Department of Radiology, Ad-din Medical College, Dhaka, Bangladesh
3. Assistant Professor, Department of Endocrinology, Mugda Medical College, Dhaka, Bangladesh

Correspondence: Dr. Sadia Armin Khan, Associate Professor, Department of Surgery, Holy Family Red Crescent Hospital, Dhaka Bangladesh, Phone: +8801720809726, Email: arminbd@yahoo.com

Received Date: 10 September, 2025

Accepted Date: 20 September, 2025

Introduction

Breast cancer is the number one cancer in women. There were 2,296,840 new cases of breast cancer in 2022 among women.[1] A modified radical mastectomy is a commonly performed surgical procedure worldwide for breast cancer still now. However, if the mastectomy incision is not planned properly, it can result in a dog ear laterally. This is not only cosmetically unpleasing but can also be a source of discomfort to the patients, interfering with arm movement and the fitting of the brassiere and/or prosthesis placement. Its actual incidence is

The Journal of Ad-din Women's Medical College; Vol. 14(1), Jan 2026; p 34-40
https://doi.org/10.3329/jawmc.v14i1.92576

unclear, but this lateral mastectomy dog ear formation is seen more frequently in overweight or obese women.

Several techniques have been described to prevent or correct lateral dog-ear deformity following mastectomy, including elliptical excision, fish-tail closure, Z-plasty, and extended lateral incisions.[2] While these methods may be effective, they often increase scar length, compromise wound tension, or create additional cosmetic concerns.[3] Moreover, some techniques are technically demanding and may not be easily reproducible in routine surgical practice, particularly in high-volume or resource-limited settings.[4]

An ideal closure technique should be simple, reliable, cosmetically acceptable, and should not significantly prolong operative time or increase morbidity. Proper management of redundant lateral skin is especially important in patients with higher body mass index, where excessive axillary and lateral chest wall tissue predisposes to dog-ear formation.[3] Failure to address this issue at the primary surgery may necessitate secondary corrective procedures, leading to patient dissatisfaction and additional healthcare costs.[5]

The Y-closure technique is a modification designed to redistribute redundant lateral skin without excessive tissue excision or scar extension. By converting redundant tissue into a triangular advancement flap, this method allows for a tension-free closure with improved contour of the lateral chest wall.[6] In this study, we describe our experience with the Y-closure technique in preventing lateral dog-ear deformity following modified radical mastectomy and evaluate its feasibility, simplicity, and cosmetic outcome in our patient population.

Materials and Methods

This prospective study was conducted between January 2024 and June 2025 and included patients who underwent Modified Radical Mastectomy (MRM) using a transverse Stewart incision. A total of 31 patients were enrolled in the study. The procedures were performed at Ad-din Medical College Hospital and in private practice.

All patients underwent thorough preoperative evaluation in accordance with NCCN (National Comprehensive Cancer Network) guidelines. Distant metastasis was ruled out in every case before surgery, and all patients were planned for modified radical mastectomy. The Stewart incision consisted of an elliptical skin incision of variable dimensions, tailored according to breast size, tumor size, and tumor location. Standard techniques were used for mastectomy and axillary lymph node dissection.

After achieving meticulous hemostasis, wound closure was planned. At the lateral end of the incision, redundant skin was managed using the Y-closure technique, resulting in a final Y-shaped wound closure. Any residual lateral dog-ear deformity was excised to achieve optimal contour.

Data were collected prospectively using a structured data sheet. Statistical analysis was performed using Statistical Package for Social Sciences (SPSS) version 25.0. Descriptive statistics were used to summarize patient demographics and surgical outcomes. Results were expressed as frequencies, percentages, and means where appropriate.

Procedure: After completion of mastectomy and axillary dissection, depending on the extra skin covering the latissimus dorsi muscle, marking is done on the superior and inferior flap margins at equal distances from the lateral end of the incision. Three points, as seen in the photo, are sutured together after the triangle flap is advanced medially. Any dog ears that are lateral are removed. The final look upon closure is shaped like a "Y."

Figure 1: Final Appearance of Scar as Like as Y

Advantages:

- Easy closing technique without undue tension
- Cosmetically superior
- No hindrance to movement of ipsilateral arm
- Brassiere fits without any discomfort
- Avoids seroma formation in the lateral pocket of the dog ear
- Avoids lateral shift of scar thus reducing the volume to be irradiated

Disadvantages:

- creates a tri point at risk for necrosis
- an additional limb scar apart from the linear scar

Results

Table 1: Age Distribution of the Study Population (n = 31)

Age group (years)	Number of cases (%)
21–30	3 (9.7)
31–40	5 (16.1)
41–50	14 (45.2)
51–60	5 (16.1)
61–70	4 (12.9)

Table 1 shows the age distribution of patients undergoing modified radical mastectomy with Y-closure technique. The majority of patients belonged to the 41–50 years age group 14 (45.2%), indicating a higher prevalence in middle-aged women. Patients aged 31–40 years and 51–60 years each accounted for 5 (16.1%) of cases, while younger patients aged 21–30 years constituted the smallest proportion 3 (9.7%).

Table 2: Body Mass Index (BMI) Distribution of the Study Population (n = 31)

BMI category	Number of cases (%)
Underweight	0 (0)
Normal	9 (29)
Overweight	17 (54.8)
Obese	4 (12.9)
Morbidly obese	1 (3.2)

Table 2 summarizes the BMI distribution of patients undergoing modified radical mastectomy with Y-closure technique. More than half of the patients were overweight 17 (54.8%), while obese and morbidly obese patients together constituted (16.1%), highlighting the predominance of higher BMI in the study population—a known risk factor for lateral dog-ear formation.

Table 3: Weight Distribution of the Mastectomy Specimen (n = 31)

Specimen weight (grams)	Number of cases (%)
0–500	2 (6.5)
501–1000	9 (29)
1001–1500	11 (35.5)
1501–2000	8 (25.8)
2001–2500	1 (3.2)

Table 3 shows the distribution of mastectomy specimen weight among the study population. The majority of specimens weighed between 1001–1500 grams 11 (35.5%), followed by 501–1000 grams 9 (29.0%) and 1501–2000 grams 8 (25.8%). Heavier specimen weights, which may contribute to increased lateral skin redundancy, were observed in a substantial proportion of patients.

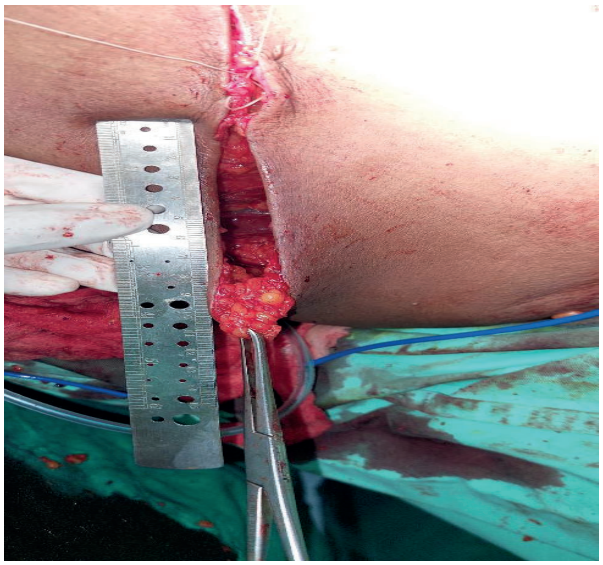

Figure 2: Mean of Upper Limb 6.2cm

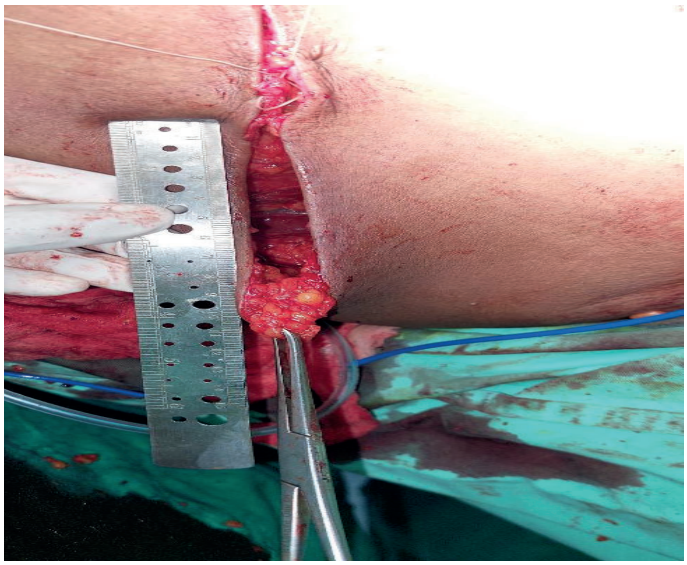

Figure 3: Mean of Lower Limb 5.6cm

Table 4: Length of Hospital Stay of the Study Population (n = 31)

Length of hospital stay (days)	Number of cases (%)
3–5	23 (74.2)
6–10	7 (22.6)
11–15	1 (3.2)

Table 4 shows the duration of hospital stay following modified radical mastectomy with Y-closure technique. The majority of patients 23 (74.2%) were discharged within 3–5 days, indicating a favorable postoperative recovery. Only 1 (3.2%) of patients required hospitalization beyond 10 days, suggesting a low rate of prolonged postoperative morbidity.

Table 5: Postoperative Complications Following Y-Closure Technique (n = 31)

Postoperative complication	Number of cases (%)
Necrosis at tripoint/apex	9 (29)
Marginal flap necrosis	8 (25.8)
Wound seroma	4 (12.9)
Wound hematoma	3 (9.7)

Table 5 summarizes the postoperative complications observed after modified radical mastectomy with Y-closure technique. The most common complication was necrosis at the tripoint or apex 9 (29.0%), followed by marginal flap necrosis 8 (25.8%). Seroma 4 (12.9%) and hematoma 3 (9.7%) were less frequent. Some patients experienced more than one complication. Most complications were managed conservatively and did not require reoperation.

Figure 4: Marginal Flap Necrosis with Necrosis

Figure 5: Completely Healed Wound at Apex

Follow-up

- Cosmetic result was excellent without lateral dog ear deformity. Patients did not complain of any discomfort. Pain was minimal in the postoperative period.

  After 6-month postoperative follow-up, most of the patients are very satisfied with the cosmesis.

Discussion

Mastectomy, both with and without reconstruction, is still a crucial component of surgical management for the treatment of breast cancer, despite significant advancements in oncoplastic breast-conserving surgery. The mastectomy wound typically has uneven opposite side lengths and a significant lateral apical angle. The "dog-ear" is the phrase used to describe the outward and upward protrusion of tissue caused by rotational and compressive forces applied to the corners of the wound as it closes. After a mastectomy, dog ears are not unusual, especially in patients with big breasts or obesity.[7] Dog ears are unattractive, can cause pain or pressure injuries, and typically lie at or above the bra line, resulting in an ill-fitting bra.[7,8,9] Additionally, dog ears frequently need surgical repair and can be a subject of litigation from disgruntled patients.

- Several surgical methods to prevent or treat dog ear on the lateral aspect of the mastectomy scar have been published, but there is no set technique.[10]

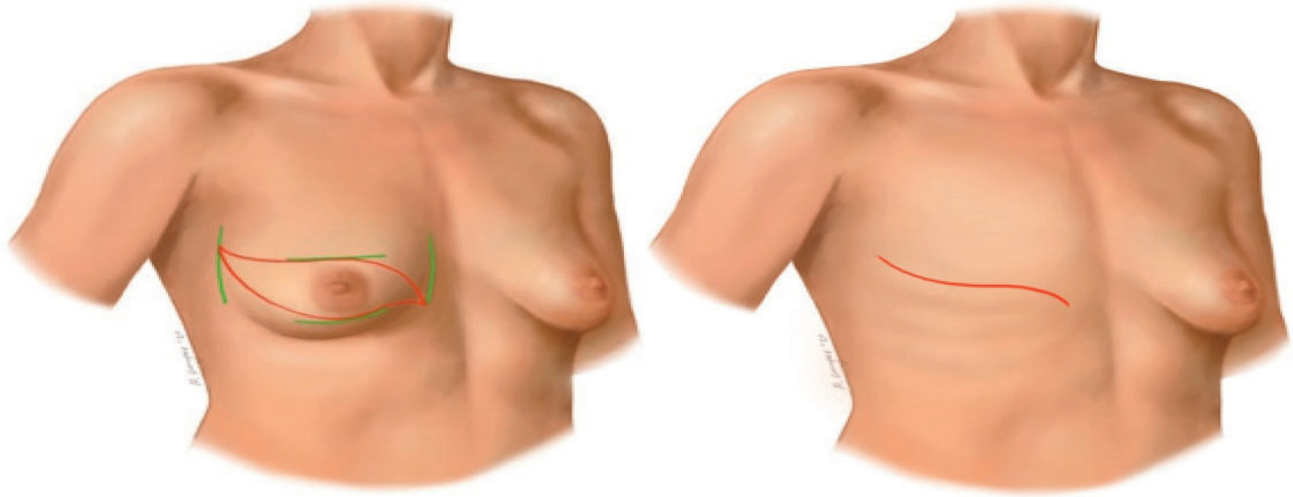

Figure 6: Double S Incision

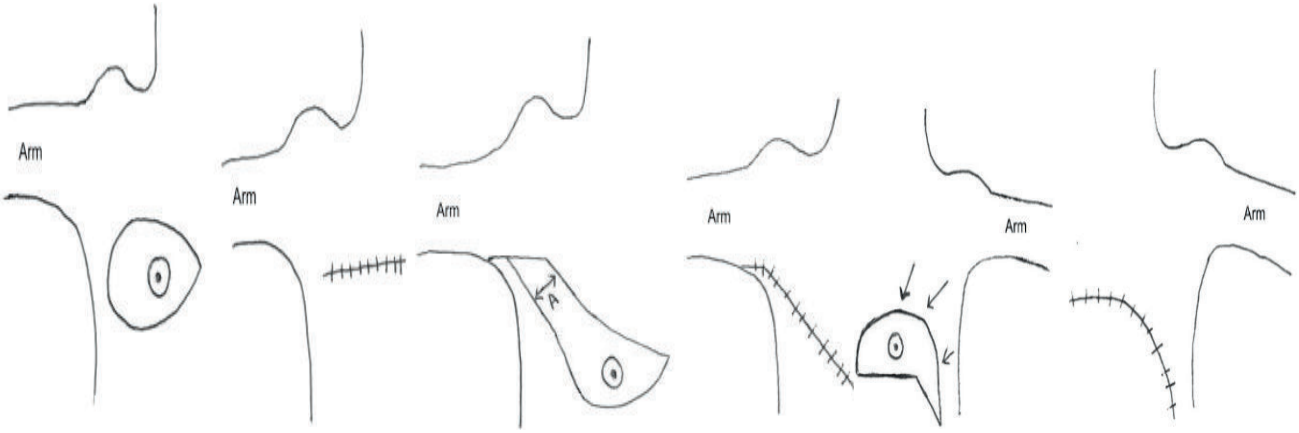

Figure 7: Tear Drop Incision (L-Technique and FISH Technique)[11]

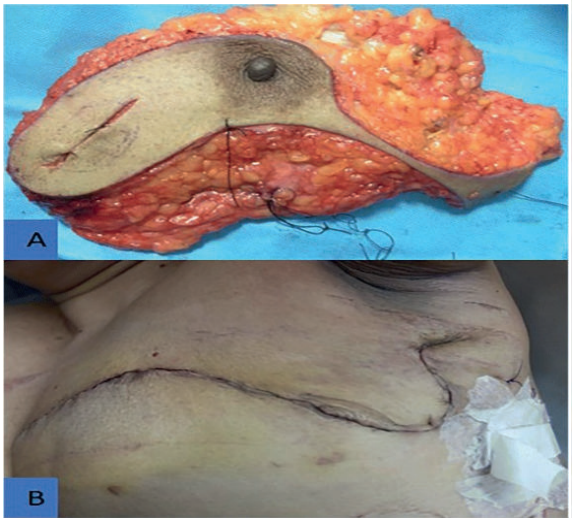

Figure 8: D-Incision

Figure 9: Y Closure is the Commonest Described Technique

The Y-closure procedure is straightforward and requires no further incisions. It involves pulling excess axillary tissue forward and creating a "Y" configuration at the lateral half of the transverse mastectomy incision (Stewart incision). Compared to other methods mentioned, the cosmetic result is better.[7]

Originally reported in the late 1980s, the Y-technique of closure after mastectomy is mostly employed to remove lateral "dog ears."[6]

A research initially presented the Y-shaped closure approach, and another study independently defined the phrase "fish-shaped closure." The same year, redundant axillary tissue is dragged forward in the Y-closure procedure, which creates a "Y" shape at the lateral half of the transverse mastectomy incision (Stewart incision).[7]

Researchers performed a systematic review of the studies describing techniques aimed at preventing the dog ear.[12] They found Y-closure or fish-shaped closure to be the most common described methods. In their review, they found results of 160 patients with Y-shaped or fish-shaped closures and found 8 complications in them, which included necrosis in 3, infection in 4, and hematoma in 1. All complications were treated successfully. They concluded this technique to be safe and gives best cosmetic outcome.

Several modifications and alternative techniques have been proposed to address lateral dog-ear deformity following mastectomy. A research demonstrated that the addition of quilting sutures to Y-plasty further reduces dead space and dog-ear formation in patients with large cup-sized breasts.[13] Other approaches, such as the L-incision with lipoaspiration described as the modified M-plasty, double-S closure, and angel wings incision, have shown satisfactory cosmetic outcomes but often involve longer scars, increased technical complexity, or additional operative steps.[14,15,16,17,18] Systematic reviews emphasize that technique selection should be individualized, considering breast size, body habitus, and surgeon expertise.[16] In this context, the Y-closure technique remains a simple, reproducible option with acceptable cosmetic and clinical outcomes.

Conclusion

There have been several surgical methods described to address the lateral dog ear of the mastectomy scar, each with advantages and disadvantages of its own. The most often reported method, known as "fish-shaped" incision or "Y closure," was shown to be safe. In order to improve cosmesis after a mastectomy, a Y-shaped closure may be advised, particularly in obese patients and avoid discomfort caused by redundant skin. It is crucial that the breast surgeon is familiar with the various techniques so that the patient can receive individualized surgical management.

References

1. Breast cancer statistics: World Cancer Research Fund
2. Goel V, Shukla S, Raju KV, Murtuza S, Ramchandra, Rao TS. Revisiting Y-shaped closure technique to prevent the dog ear formation in women undergoing mastectomy. Indian Journal of Surgical Oncology. 2019; 10(1): 95-97.
3. Steffens D, Kappos EA, Lunger A, Schwab FD, Zehnpfennig L, Weber WP, Haug M, Heinzelmann-Schwarz V, Kurzeder C. The double S technique to achieve aesthetic flat closure after conventional mastectomy. World Journal of Surgical Oncology. 2022; 20(1): 42-50.
4. El-deen AB, Ashour HG, Khalil A. Y-Shaped Closure Technique to Prevent the Dog Ear Formation in Women Undergoing Mastectomy. Surgical Chronicles. 2022; 27(2): 222-227.
5. Samy A, Hemida M, Elsoud MA, Hany M, Ramadan R. Evaluation of different techniques used to avoid the formation of dog ear at lateral end of mastectomy scar. Journal of the Medical Research Institute.2016; 37(2): 41-48.
6. El-deen AB, Ashour HG, Khalil A. Mastectomy with Y-Shaped Incision a Technique Designed for Women with Obesity. Zagazig University Medical Journal. 2024; 30(1.3): 36-40.
7. Robertson SA, Jeevaratnam JA, Agrawal A, et al. Mastectomy skin flap necrosis: challenges and solutions. Breast Cancer (Dove Med Press). 2017; 9: 141–152.
8. Hussien M, Daltrey IR, Dutta S, et al. Fish-tail plasty: a safe technique to improve cosmesis at the lateral end of mastectomy scars. Breast. 2004; 13: 206–209.
9. Hill EL, Ochoa D, Denham F, Merrill A, Lin-Duffy MF, Wilson AB, Corbin S, Rivere A, Preston M, Henry-Tillman R. The angel wings incision: a novel solution for mastectomy patients with increased lateral adiposity. The Breast Journal. 2019; 25(4): 687-690.
10. Farrar WB, Fanning WJ. Eliminating the dog-ear in modified radical mastectomy. Am J Surg.1988; 156: 401–402.

11. Nowacki MP, Towpik E, Tchorzewska H. Early experience with 'fish-shaped' incision for mastectomy. Eur J Surg Oncol. 1991; 17: 615–617.

12. Lim GH, Tan HF. Surgical techniques to avoid lateral dog ear of the mastectomy scar: a systematic review. Int J Surg. 2016; 26: 73–78.

13. Alhussini MA, Awad AT, Kholosy H. Adding quilting sutures to Y plasty to avoid postmastectomy lateral dog ears in patients with large cup sized breast. The Egyptian Journal of Surgery. 2024; 43(1): 270-275.

14. El Hajj H, Millochau J, Mpungu LF, Sabaila A, Nos C, Sarfati I, Clough KB. Avoiding post mastectomy lateral "Dog Ears" by an L incision and lipoaspiration: The Paris Breast Center technique. European Journal of Surgical Oncology. 2022 Sep 1; 48(9): 1925-1928.

15. Meybodi F, Pham M, Sedaghat N, Elder E, French J. The modified m-plasty approach to mastectomy: Avoiding the lateral dog-ear. Plastic and Reconstructive Surgery–Global Open. 2022; 10(2): e4116.

16. Kang AS, Kang KS. A systematic review of cutaneous dog ear deformity: a management algorithm. Plastic and Reconstructive Surgery– Global Open. 2020; 8(9): e3102.

17. Thomas R, Mouat C, King B. Mastectomy flap design: the 'waisted teardrop'and a method to reduce the lateral fold. ANZ journal of surgery. 2012; 82(5): 329-333.

18. Butz DR, Kim EK, Song DH. CY trilobed flap for improved nipple-areola complex reconstruction. Plastic and Reconstructive Surgery. 2015; 136(2): 234-237.