

Short Communication

Chikungunya's Lingering Pain: Arthritis in the Aftermath

Richmond Ronald Gomes¹

Introduction

The term "Chikungunya" originates from the Makonde language, translating to "that which bends up," which reflects characteristic posture of patients exhibiting severe symptoms.¹ The fever is locally also named 'Langra Jor'.

Chikungunya Fever (CHIKF) is caused by an RNA virus (CHIKV) that is single-stranded belonging to the genus Alphavirus belonging to the Togaviridae family, comprising some viruses transmitted (mostly) by arthropods.² Only 5% of infected individuals are asymptomatic³. The virus was first isolated in 1952-1953 from both men and mosquitoes during an epidemic of fever that was considered clinically indistinguishable from dengue fever in Tanzania⁴. It is a single-stranded RNA virus, heat-labile, and sensitive to temperatures above 58⁰C.

Chikungunya virus is transmitted by *Aedes* mosquitoes (*Ae. Aegypti* & *Ae. Albopictus*) which breed in clean water collections in containers, tanks, disposables, and junk material in domestic and peri-domestic situations besides natural habitats like tree holes, plantations etc⁵. Transmission of CHIKV is associated with rainfall, temperature, and other climatic variables, similar to that of dengue mosquitoes. In recent years an increase in CHIKV during monsoon and post-monsoon seasons has been reported due to a varied vector population associating rainfall and its lifespan affected by temperature and humidity. In Bangladesh, *Ae. Aegypti* remain the primary carrier/main vector to transmit

CHIKV principally being day biters. The incubation period (time from infection to illness) can be 2-12 days but is usually 3-7 days.⁵ Acute Chikungunya fever typically lasts a few days to a couple of weeks, but some patients have prolonged fatigue lasting several weeks. Additionally, most patients have reported incapacitating joint pain, or arthritis which may last for weeks or months. The prolonged joint pain associated with CHIKV is not typical of dengue. Joint pain is often severe, and most often involves the metacarpal-phalangeal and interphalangeal joints of the hands, the wrists, the ankles, and the metatarsal-phalangeal joints of the feet. Less commonly involved but described joints include the shoulders, elbows, hips, knees, and inter-vertebral joints.

Maternal-to-child transmission has also been reported, with up to 50% of neonates acquiring infection during childbirth if born within 5 days of maternal infection. Musculoskeletal manifestations are less prominent in newborns, with CHIKF being more notable for fevers, rash, cytopenias, hepatitis, and/or encephalitis.⁵

Chikungunya in Bangladesh⁵

Bangladesh experienced its first reported outbreak in 2008 during an outbreak in the northwest of the country in two villages near the Indian border. Despite several subsequent isolated outbreaks, culminating in an enormous nationwide epidemic in 2017, very little is known about the burden or dynamics of Chikungunya within the country and the risk factors for infection. A significant outbreak of Chikungunya virus (CHIKV) took place in Bangladesh between April and September 2017, putting more than two million individuals at risk of infection. Between April 1, 2017, when the outbreak began, and September 7, 2017, the Ministry of Health, Govt. of Bangladesh documented 984 cases confirmed through real-time PCR testing, alongside over 13,176 clinically confirmed cases across 17 out of 64 districts.

The Journal of Ad-din Women's Medical College; Vol. 13 (1), Jan 2025; p 23-30
<https://doi.org/10.3329/jawmc.v13i1.81326>

Correspondence: Dr. Richmond Ronald Gomes, Professor and Head, Dept. of Medicine, Ad-din Women's Medical College Hospital, Dhaka Bangladesh, e-mail:rrichi.dmc.k56@gmail.com, Cell: +88018-19289499

Received Date : 2 August,2024

Accepted Date : 30 August,2024

Criteria for the Identification of Chikungunya Infection⁵**Clinical criteria:**

- acute onset of fever >38.5°C
- severe arthralgia/arthritis not explained by other medical conditions

Epidemiological criteria:

- Residing or having visited epidemic areas
- having reported transmission within 15 days prior to the onset of symptoms

Laboratory Criteria:**At least one of the following tests in the acute phase:**

- Virus isolation by Cell Culture
- Presence of viral RNA by real-time RT-PCR (Within 5 days of onset of illness)
- Presence of viral-specific IgM antibody in a single serum sample collected within 5 to 28 days of onset of Fever
- Four-fold Rise of IgG antibody in samples collected at least three weeks apart (1st sample after 7 days)

Clinical Presentation⁵**Table 1:** Clinical features of Chikungunya fever

Common	Infrequent	Rare in adults but common in children
Fever	Stomatitis	Photophobia
Arthritis/arthralgia	Oral ulcer	Retro orbital pain
Backache	Exfoliative dermatitis	Vomiting/diarrhoea
Headache	Photosensitivity	Mental confusion
Rash	Hyperpigmentation	Signs of meningeal irritation

Clinical course and outcome⁵

1. Acute symptoms typically resolve within 7–10 days with overall reported case fatality rate of <1% based on epidemics in the Indian Ocean region and the Americas. Nonetheless, case fatality rate is elevated in newborns, older adults, and individuals with preexisting cardiovascular & pulmonary conditions.
2. Some patients may experience a relapse of rheumatologic symptoms, such as polyarthralgia, polyarthritis, and tenosynovitis, several months after the acute illness.
3. In varying proportions of patients, joint pain can persist for months to years.
4. Rare complications associated with the disease include uveitis, retinitis, myocarditis, hepatitis, nephritis, bullous skin lesions, hemorrhage, meningoencephalitis, myelitis, Guillain-Barré syndrome, and cranial nerve palsies.

Table 2: Clinical and laboratory features of chikungunya virus infections compared with dengue virus infections⁵

Trait	Chikungunya	Dengue
Fever (>38.5°C)	+++	++
Arthralgia	+++	+/-
Arthritis	+	-
Headache	++	++
Rash	++	+
Myalgia	+	++
Hemorrhage	+/-	++
Shock	-	+
Lymphopenia	+++	++
Neutropenia	+	+
Thrombocytopenia	+	+++
Hemoconcentration	-	++

Vaccination⁵

A Chikungunya vaccine is designed to confer acquired immunity against the Chikungunya virus. The most frequently reported side effects associated with this vaccine include headache, fatigue, muscle pain, joint pain, fever, nausea, and tenderness at the site of injection. The first Chikungunya vaccine was approved for medical use in the United States in November 2023.

Prevention⁵

Although an approved vaccine exists, the most effective means of prevention are protection against contact with disease-carrying mosquitoes and controlling mosquito populations by limiting their habitat. Mosquito control focuses on eliminating the standing water where mosquitos lay eggs and develop as larvae; if elimination of the standing water is not possible, insecticides or biological control agents can be added. Methods of

protection against contact with mosquitos include using insect repellents with substances such as DEET, icaridin, PMD (p-menthane-3,8-diol, a substance derived from the lemon eucalyptus tree), or ethyl butylacetyl aminopropionate (IR3535). However, increasing insecticide resistance presents a challenge to chemical control methods.

Wearing bite-proof long sleeves and trousers also offers protection, and garments can be treated with pyrethroids, a class of insecticides that often have repellent properties. Vaporized pyrethroids (for example in mosquito coils) are also insect repellents. As infected mosquitoes often feed and rest inside homes, securing screens on windows and doors will help to keep mosquitoes out of the house. In the case of the day-active *Ae. Aegypti* and *Ae. Albopictus*, however, this will have only a limited effect, since many contacts between mosquitoes and humans occur outdoors.

Treatment⁵

Currently, there is no specific treatment available for Chikungunya. Supportive care is recommended, and symptomatic treatment of fever and joint swelling includes the use of nonsteroidal anti-inflammatory drugs such as naproxen, non-aspirin analgesics such as paracetamol (acetaminophen), and fluids. Aspirin is not recommended due to the increased risk of bleeding. Despite anti-inflammatory effects, corticosteroids are not recommended during the acute phase of the disease as they may cause immunosuppression and worsen infection.

Passive immunotherapy has potential benefits in the treatment of Chikungunya. Studies in animals using passive immunotherapy have been effective, and clinical studies using passive immunotherapy in those particularly vulnerable to severe infection are currently in progress. Passive immunotherapy involves the administration of anti-CHIKV hyperimmune human intravenous antibodies (immunoglobulins) to those exposed to a high risk of Chikungunya infection. No antiviral treatment for Chikungunya virus is currently available, though testing has shown several medications to be effective in vitro.

Chronic Chikungunya Arthritis/Post Chikungunya arthritis

Arthritis/arthritis is a principal feature of CHIKF caused by this virus, with high risk of progression to functional and quality of life sequelae.

The prevalence of chronic arthritis after acute CHIKV infection has been reported at approximately 14%. Factors such as an age of more than 45 years, high viral load (>109/mL) during the acute phase and severe immunologic response in post-viremic phase are predictors of development of chronic symptoms.

Arthritis/arthritis is a principal feature of CHIKF. Many patients recover within several weeks. When rheumatic disease persists for more than 12 weeks, we refer to these symptoms as chronic Chikungunya arthritis (CCA). Arthritic manifestations can last for weeks, months, or even years. Rodriguez-Morales and colleagues retrospectively studied 283 patients from the 2015 epidemic in Risaralda Department, Colombia. At 26 weeks post-infection, 53.7% of the patients reported chronic musculoskeletal symptoms, including 49.5% with morning stiffness, 40.6% with joint swelling, and 16.6% with joint erythema⁶. Another large observational study from Kerala, India, found that 57% of patients had chronic polyarthralgias, 22% chronic polyarthritis, and 19.5% chronic tenosynovitis 15 months after CHIKF⁷.

The classical pattern of arthritis involves the small to medium-sized joints in a peripheral and symmetric distribution. The pattern can resemble Rheumatoid Arthritis (RA), but most patients have negative tests for rheumatoid factor and anti-cyclic citrullinated peptide antibodies⁸. Patients with CCA often meet diagnostic and/or clinical criteria for RA or Spondyloarthritis⁹. The distinguishing clinical feature is a previous history of acute CHIKF, with laboratory confirmation of serum positivity for IgM and/or IgG anti-CHIK antibodies.

During acute CHIK infection, serum cytokines IL-1Ra, IL-1 β , IL-6, IL-7, IL-8, IL-12, IL-15, and IFN- α increase, while RANTES (CCL5) decreases^{10,11}. With the transition to CCA, elevated levels of IL-6, GM-CSF, and IL-17 become predominant¹¹. The IL-17 signature in particular may drive chronic joint inflammation, stimulating the upregulation of other pro-inflammatory cytokines, including IL-1, IL-6, and TNF- α , matrix metalloproteinases, and RANK-RANKL, leading to osteoclastogenesis and bone erosions¹². Alphavirus infection of osteoblasts has been shown to perturb the RANKL-osteoprotegerin ratio, contributing to bone loss. This imbalance may also provide a mechanism for joint erosions in chronic disease¹³.

CHIKV primarily infects human epithelial and endothelial cells, fibroblasts, and macrophages. Replication has not

been observed in lymphocytes, monocytes, or monocyte-derived dendritic cells¹⁴. Viral tropism to the highly vascularized synovial tissues of the joints may be responsible for the prominence of arthritis following acute infection. Whether CHIKV persists in synovial tissue during the chronic phase remains unclear, however, and there is an ongoing debate about whether CCA arises secondary to immunological dysregulation or is due to persistent alphavirus infection of the synovial tissue.

The international literature reports variable frequencies of RF and anti-CCP positivity, reporting between 12% and 43% of positivity RF in India, and between 30% and 50% for RF/anti-CCP according to French series, probably indicating a more severe clinical profile in some of these groups, and with a higher risk of erosion. The identification of a low prevalence IL-17 elevation supports the idea of a less severe clinical profile and possibly an improved prognosis in the long term. In terms of other cytokines profile, the percentage of patients with detectable IL-6 was significant in patients (65%).

Diagnosis of Chronic Chikungunya Arthritis (CCA)

The diagnosis of Chikungunya (CHIK) relies on epidemiological data, distinctive clinical features, the infection's progression, and laboratory confirmation. Many patients either reside in or have recently traveled to regions where *Aedes* mosquito transmission is endemic. Laboratory testing varies depending on the infection stage. During the acute phase, CHIK viremia typically lasts for 5–7 days, during which serum RT-PCR can provide a definitive diagnosis. Anti-CHIKV IgM antibodies usually appear within 3–8 days and remain detectable for 1–3 months, while IgG antibodies can be identified at 4–10 days and may persist for months to years⁴.

Patients with chronic Chikungunya arthritis (CCA) experience debilitating joint symptoms, which can range from morning stiffness and arthralgia to pronounced inflammatory synovitis. A typical pattern involves peripheral involvement of small and medium joints, although mono-arthritis and oligo-arthritis may also occur. In some patients, CCA presents clinically as an RA “mimic,” but most patients have negative tests for rheumatoid factor and anti-cyclic citrullinated peptide antibodies⁸. Patients with CCA often meet diagnostic and/or clinical criteria for RA or Spondyloarthritis⁹. The distinguishing clinical feature is a previous history of

acute CHIKF, with laboratory confirmation of serum positivity for IgM and/or IgG anti-CHIK antibodies.

Radiographic imaging of affected joints may initially appear normal, especially in the early stages of the disease; however, some patients may later develop bone erosions. Magnetic resonance imaging (MRI) is more sensitive for detecting inflammatory changes and can reveal synovial thickening, bone marrow edema, effusions, and/or tenosynovitis⁸.

Treatment of Chronic Chikungunya Arthritis (CCA)

Guidelines for the management of CCA emphasize symptomatic pain control with acetaminophen/paracetamol, codeine, and/or neuropathic medications such as gabapentin. Adjunctive treatment includes physical therapy, thermotherapy, and/or cryotherapy¹⁵. These approaches can relieve pain and improve function, but are not disease-modifying.

Corticosteroid and non-steroidal anti-inflammatory drugs (NSAIDs)

In an uncontrolled case series conducted during the 2005–2006 Indian Ocean pandemic, short-term corticosteroid therapy was found to alleviate arthritis and tenosynovitis while reducing disability in patients with chronic Chikungunya arthritis (CCA)¹⁶. Corticosteroid treatment led to greater pain relief and patient satisfaction compared to paracetamol, NSAIDs, medicinal herbs, and physical exercise¹⁷. Despite positive results, long-term use of corticosteroids is not advised due to well-known risks of infection, cataracts, glaucoma, hyperglycemia and diabetes mellitus, and osteopenia/osteoporosis associated with chronic corticosteroid use.

Chloroquine and Hydroxychloroquine

An open-label pilot study investigating chloroquine (CQ) treatment for chronic Chikungunya arthritis (CCA) in South Africa demonstrated improvements in both patient and physician assessments of disease activity, although it is important to note that this trial was not blinded. Brito and colleagues have recommended hydroxychloroquine (HCQ) at a daily dose of 6 mg/kg as the first-line treatment for CCA, potentially as part of a treatment regimen that could escalate to include triple therapy with sulfasalazine (SSZ) and methotrexate (MTX)¹⁹. However, the majority of current evidence indicates that antimalarials like CQ and HCQ are generally ineffective for treating CCA.

Sulfasalazine

The Ravindran and Alias trial included SSZ 1000 mg daily in combination with HCQ and MTX as part of triple therapy, compared to HCQ²⁰. Although the combination therapy demonstrated greater efficacy, the specific contribution of SSZ apart from MTX could not be determined. Overall, there is limited evidence supporting the effectiveness of SSZ as a monotherapy for chronic Chikungunya arthritis (CCA), though it may prove beneficial when used in combination with other medications such as MTX.

Methotrexate

In the trial conducted by Ravindran and Alias, the combination therapy regimen that included methotrexate (MTX) at a weekly dose of 15 mg, along with sulfasalazine (SSZ) at 1000 mg daily and hydroxychloroquine (HCQ) at 400 mg daily, was found to be more effective than HCQ alone. At 24 weeks, the Disease Activity Score 28 using the erythrocyte sedimentation rate (DAS28-ESR) was below 3.2 for 84% of patients in the combination group, compared to only 14% in the HCQ group. Both groups received prednisolone at a daily dose of 7.5 mg, which was tapered off over 6 weeks²⁰.

Additionally, in another trial by Ganu and Ganu, patients who did not respond adequately to the combination of SSZ and HCQ were switched to treatment with MTX at doses of 15–20 mg weekly compared to a placebo. The MTX group achieved a superior clinical response versus SSZ/HCQ (71.4% versus 12.5%)²¹.

Amaral and colleagues conducted a study involving 48 patients with chronic Chikungunya arthritis (CCA) who were treated with open-label methotrexate (MTX), starting at a weekly dose of 7.5 mg, with adjustments for persistent symptoms after 4 weeks. The average final dose of MTX was 9.2 ± 3.2 mg per week. Nine patients (18%) received MTX in combination with prednisone at a mean daily dose of 6.1 ± 2.2 mg. Additionally, two patients were treated with HCQ at 400 mg daily alongside MTX, while one patient also received sulfasalazine (SSZ) at 1000 mg daily. At the initial visit, the average pain score measured by a visual analog scale was 7.7 ± 2.0 . By the 4-week and 8-week marks, the mean pain scores had decreased to 3.0 and 2.6, respectively²².

Overall, MTX has shown potential as a treatment for CCA; however, previous trials either involved combinations with HCQ and SSZ or were unblinded. Further randomized trials are necessary to assess the efficacy of MTX monotherapy.

Biologics

To date, no human trials have been performed to assess the efficacy of biologic therapies utilizing monoclonal antibodies for the treatment of chronic Chikungunya arthritis (CCA). Bouquillard and Combe treated patients with acute CHIKF followed by the diagnosis of RA (not categorized as CCA) with TNF- α inhibitors. These patients had been refractory to initial therapy with MTX. 6 out of 6 patients had a good clinical response (four with etanercept, two with adalimumab)²³. The majority of the patients had been diagnosed with seronegative RA, which was not distinguished from CCA.

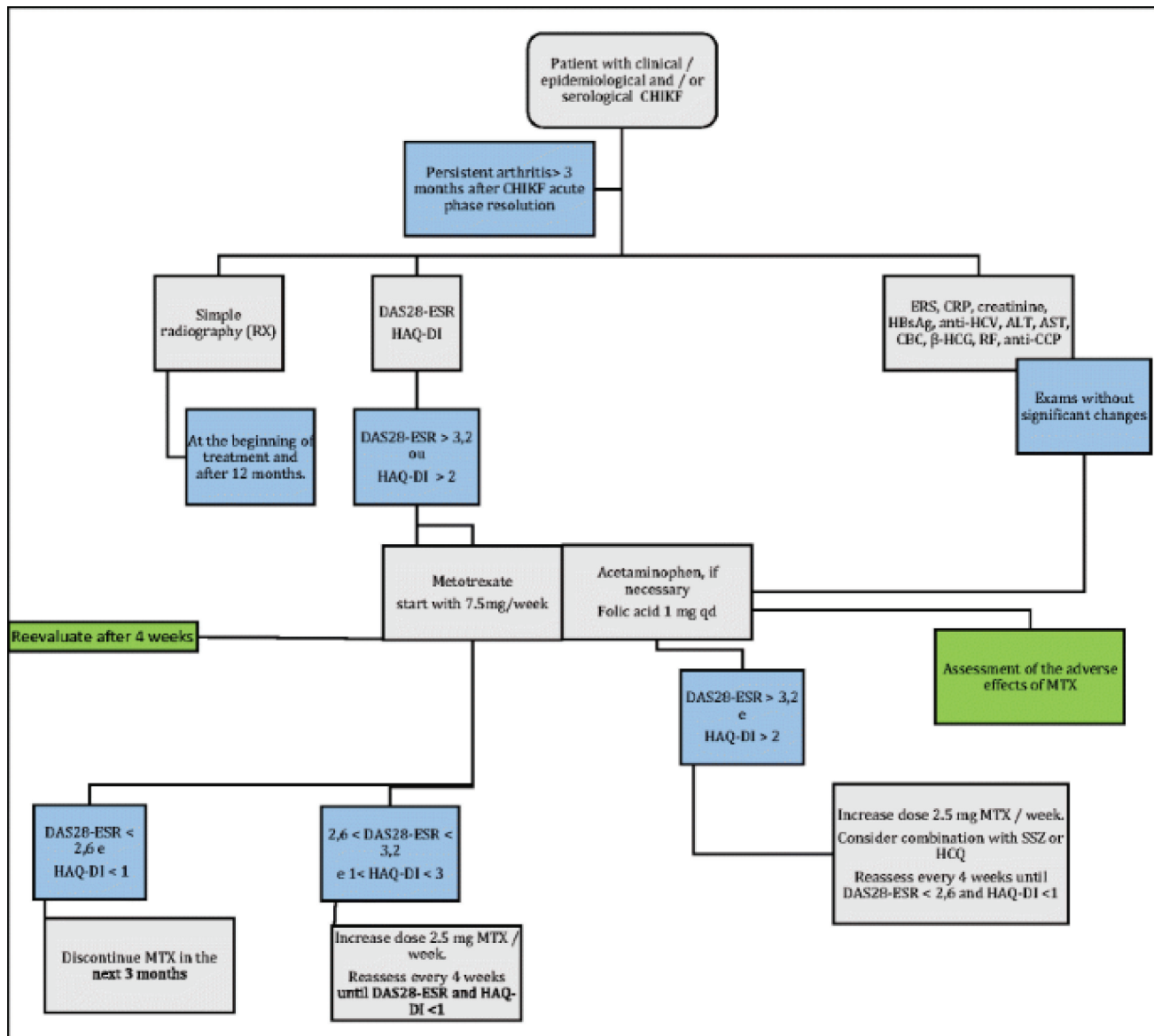
Treatment of CHIKV acutely-infected mice with the anti-CTLA-4 monoclonal antibody abatacept showed decreased T cell infiltration of joint tissues without affecting viral replication²⁴. There is currently no data for its use in humans nor for its use in treating CCA.

Novel agents

Pentosan polysulfide is an innovative glycosaminoglycan-like molecule designed for the treatment of alphavirus infections. In experiments with CHIKV-infected mice, treatment with pentosan polysulfide led to a reduction in cartilage thinning and immune cell infiltration in joints²⁵. Intra-articular levels of the pro-inflammatory cytokines IL-6, IL-9, CCL2, and G-CSF were decreased, and levels of the anti-inflammatory IL-10 were increased through unclear mechanisms²⁶.

While it was initially developed for the treatment of acute Chikungunya infection, it is uncertain whether pentosan polysulfide could be effective in preventing joint erosions in patients with Chronic Chikungunya Arthritis (CCA).

Fingolimod, a sphingosine 1-phosphate receptor agonist, was developed for treating multiple sclerosis. In studies involving CHIKV-infected mice, fingolimod treatment resulted in decreased migration of CD4+ T cells into the joints without affecting viral replication²⁷. Although the potential of fingolimod for treating CCA has yet to be established, the reduction in T cell migration into the joints could be advantageous.



Proposal treatment of CHIK arthritis using methotrexate. DAS28-ESR Disease Activity Score 28-Erythrocyte Sedimentation Rate, HAQ-DI Health Assessment Questionnaire Disability Index, CBC complete blood count, SSZ sulfasalazine, HCQ hydroxychloroquine, RF rheumatoid factor, ALT alanine aminotransferase, AST aspartate aminotransferase, CHIKF chikungunya.²⁸

Conclusion

Chronic Chikungunya arthritis (CCA) is an emerging, chronic, and debilitating rheumatological syndrome that can persist for weeks, months, or even years following an acute Chikungunya fever (CHIKF) episode.

With the global spread of the Chikungunya virus (CHIKV) in recent decades, an increasing number of patients,

particularly in developing countries, have developed or are at risk of this chronic and disabling condition. The pathophysiology of CCA remains unclear, although the prevailing evidence suggests that the syndrome may arise from a post-viral autoimmune process that occurs after viral clearance.

Currently, there is limited clinical trial evidence supporting the use of disease-modifying therapies for patients with CCA. Most of the previous trials have been open-label or of questionable quality, highlighting the need for more rigorous research to better understand and treat this condition.

Empiric treatment options, including corticosteroids, NSAIDs, antimalarials, and sulfasalazine (SSZ), may be considered for managing chronic Chikungunya arthritis

(CCA). However, due to the similarities between CCA and Rheumatoid Arthritis (RA), we believe that further evaluation of methotrexate (MTX) as a treatment option is warranted. Additionally, as research progresses, new therapies, including biologics and novel agents like pentosan polysulfate and fingolimod, may become viable treatment alternatives for patients with CCA.

References

- Ganesan VK, Duan B, Reid SP. Chikungunya virus: pathophysiology, mechanism, and modeling. *Viruses*. 2017;9(12):368.
- Solignat M, Gay B, Higgs S, Briant L, Devaux C. Replication cycle of chikungunya: a re-emerging arbovirus. *Virology*. 2009;393(2):183-197.
- Simon F, Javelle E, Oliver M, Leparç-Goffart I, Marimoutou C. Chikungunya virus infection. *Current infectious disease reports*. 2011;13:218-228.
- Suhrbier A, Jaffar-Bandjee MC, Gasque P. Arthritogenic alphaviruses—an overview. *Nature Reviews Rheumatology*. 2012;8(7):420-429.
- National Guidelines on Clinical Management of Chikungunya Fever. Disease Control Unit (CDC) Directorate General of Health Services, Ministry of Health & Family Welfare, Bangladesh. 2023
- Rodriguez-Morales AJ, Gil-Restrepo AF, Ramírez-Jaramillo V, Montoya-Arias CP, Acevedo-Mendoza WF, Bedoya-Arias JE, Chica-Quintero LA, Murillo-García DR, García-Robledo JE, Castrillón-Spitia JD, Londoño JJ. Post-chikungunya chronic inflammatory rheumatism: results from a retrospective follow-up study of 283 adult and child cases in La Virginia, Risaralda, Colombia. 2016;5:360.
- Mathew AJ, Goyal V, George E, Thekkemuriyil DV, Jayakumar B, Chopra A, Trivandrum COPCORD Study Group. Rheumatic- musculoskeletal pain and disorders in a naïve group of individuals 15 months following a Chikungunya viral epidemic in south India: a population based observational study. *International journal of clinical practice*. 2011; 65(12):1306-1312.
- Manimunda SP, Vijayachari P, Uppoor R, Sugunan AP, Singh SS, Rai SK, Sudeep AB, Muruganandam N, Chaitanya IK, Guruprasad DR. Clinical progression of chikungunya fever during acute and chronic arthritic stages and the changes in joint morphology as revealed by imaging. *Transactions of the Royal Society of Tropical Medicine and Hygiene*. 2010;104(6):392-399.
- Javelle E, Ribera A, Degasne I, Gaüzère BA, Marimoutou C, Simon F. Specific management of post-chikungunya rheumatic disorders: a retrospective study of 159 cases in Reunion Island from 2006-2012. *PLoS neglected tropical diseases*. 2015;9(3):e0003603.
- Ng KW, Chow A, Win MK, Dimatatac F, Neo HY, Lye DC, Leo YS. Clinical features and epidemiology of chikungunya infection in Singapore. *Singapore medical journal*. 2009 ;50(8):785.
- Chow A, Her Z, Ong EK, Chen JM, Dimatatac F, Kwek DJ, Barkham T, Yang H, Rénia L, Leo YS, Ng LF. Persistent arthralgia induced by Chikungunya virus infection is associated with interleukin-6 and granulocyte macrophage colony-stimulating factor. *Journal of Infectious Diseases*. 2011;203(2):149-157.
- Miossec P, Korn T, Kuchroo VK. Interleukin-17 and type 17 helper T cells. *New England Journal of Medicine*. 2009;361(9):888-898.
- Chen W, Foo SS, Rulli NE, Taylor A, Sheng KC, Herrero LJ, Herring BL, Lidbury BA, Li RW, Walsh NC, Sims NA. Arthritogenic alphaviral infection perturbs osteoblast function and triggers pathologic bone loss. *Proceedings of the National Academy of Sciences*. 2014;111(16):6040-6045.
- Sourisseau M, Schilte C, Casartelli N, Trouillet C, Guivel-Benhassine F, Rudnicka D, Sol-Foulon N, Roux KL, Prevost MC, Fsihi H, Frenkiel MP. Characterization of reemerging chikungunya virus. *PLoS pathogens*. 2007;3(6):e89.
- Simon F, Javelle E, Cabie A, Bouquillard E, Troisgros O, Gentile G, Leparç-Goffart I, Hoen B, Gandjbakhch F, Rene-Corail P, Franco JM. French guidelines for the management of chikungunya (acute and persistent presentations), November 2014. *Med Mal Infect*. 2015 ;45(7):243-263.
- Simon F, Parola P, Grandadam M, Fourcade S, Oliver M, Brouqui P, Hance P, Kraemer P, Mohamed AA, de Lamballerie X, Charrel R. Chikungunya infection: an emerging rheumatism among travelers returned from Indian Ocean islands. Report of 47 cases. *Medicine*. 2007 ;86(3):123-137.
- Simon F, Parola P, Grandadam M, Fourcade S, Oliver M, Brouqui P, Hance P, Kraemer P, Mohamed AA, de Lamballerie X, Charrel R. Chikungunya infection: an emerging rheumatism among travelers returned from Indian Ocean islands. Report of 47 cases. *Medicine*. 2007;86(3):123-137.

18. Brighton SW. Chloroquine phosphate treatment of chronic Chikungunya arthritis-an open pilot study. *South African Medical Journal*. 1984;66(6):217-218.
19. Brito CA, Sohsten AK, Leitão CC, Brito RD, Valadares LD, Fonte CA, Mesquita ZB, Cunha RV, Luz K, Leão HM, Brito CM. Pharmacologic management of pain in patients with Chikungunya: a guideline. *Revista da Sociedade Brasileira de Medicina Tropical*. 2016;49(06):668-679.
20. Ravindran V, Alias G. Efficacy of combination DMARD therapy vs. hydroxychloroquine monotherapy in chronic persistent chikungunya arthritis: a 24-week randomized controlled open label study. *Clinical rheumatology*. 2017;36(6):1335-1340.
21. Ganu MA, Ganu AS. Post-chikungunya chronic arthritis--our experience with DMARDs over two year follow up. *The Journal of the Association of Physicians of India*. 2011;59:83-86.
22. Amaral JK, Bingham III CO, Schoen RT. Successful methotrexate treatment of chronic chikungunya arthritis. *JCR: Journal of Clinical Rheumatology*. 2020;26(3):119-124.
23. Bouquillard É, Combe B. A report of 21 cases of rheumatoid arthritis following Chikungunya fever. A mean follow-up of two years. *Joint bone spine*. 2009;76(6):654-657.
24. Miner JJ, Cook LE, Hong JP, Smith AM, Richner JM, Shimak RM, Young AR, Monte K, Poddar S, Crowe Jr JE, Lenschow DJ. Therapy with CTLA4-Ig and an antiviral monoclonal antibody controls chikungunya virus arthritis. *Science translational medicine*. 2017;9(375).
25. Herrero LJ, Foo SS, Sheng KC, Chen W, Forwood MR, Bucala R, Mahalingam S. Pentosan polysulfate: a novel glycosaminoglycan-like molecule for effective treatment of alphavirus-induced cartilage destruction and inflammatory disease. *Journal of virology*. 2015;89(15):8063-8076.
26. Chen W, Foo SS, Rulli NE, Taylor A, Sheng KC, Herrero LJ, Herring BL, Lidbury BA, Li RW, Walsh NC, Sims NA. Arthritogenic alphaviral infection perturbs osteoblast function and triggers pathologic bone loss. *Proceedings of the National Academy of Sciences*. 2014;111(16):6040-6045.
27. Teo TH, Chan YH, Lee WW, Lum FM, Amrun SN, Her Z, Rajarethinam R, Merits A, Röttschke O, Rénia L, Ng LF. Fingolimod treatment abrogates chikungunya virus-induced arthralgia. *Science Translational Medicine*. 2017;9(375).
28. Kennedy Amaral Pereira J, Schoen RT. Management of chikungunya arthritis. *Clinical Rheumatology*. 2017;36:2179-2186.