

## Case Series

# Case Studies on Thiamine Replacement Therapy: For Suspected Cardiac Beriberi in Children and Literature Review

Mahmuda Hassan<sup>1</sup>, Kona Choudhury<sup>2</sup>, Afsana Mukti<sup>3</sup>, Masuma Khan<sup>4</sup>, Marium Begum<sup>5</sup>, Hamidur Rahman<sup>6</sup>

### Abstract:

Thiamine (vitamin B<sub>1</sub>) serves as an important cofactor in metabolism and energy production. It is related to the biosynthesis of neurotransmitters and the production of substances used in defense against oxidative stress. Lack of thiamine affects several systems of the body, predominantly the cardiovascular and nervous systems. The cardiac effect caused by thiamine deficiency is known as cardiac beriberi, also known as wet beriberi. Other than wet beriberi, dry beriberi presents with neurological symptoms. The more severe form is Shoshin beriberi with cardiac failure and lactic acidosis with cold periphery as the presenting feature. The disease is now very rare in developed countries in this era, but still present in South East Asia and developing countries including Bangladesh. Thiamine deficiency (TD) is an important public health problem because almost all of the populations in this area consume polished rice, which is the major staple food, and other primary dietary sources of thiamine are also poor. TD is frequently missed by pediatricians, with potentially fatal consequences. Herein, we present a series of cases to draw attention to cardiac beriberi. We believe that these cases will help prompt us to the importance and also a reminder of this forgotten but notable disease.

**Keywords:** Beriberi, Heart Failure, Thiamine Deficiency

### Introduction

A water-soluble vitamin, thiamine, also known as vitamin B<sub>1</sub>, has a physiologically active form called thiamine pyrophosphate, which functions as a coenzyme to make vital glucose for energy and is needed for the

metabolism of carbohydrates.<sup>1,2</sup> The absence of this active component is commonly denoted as beriberi or thiamine deficiency (TD). In numerous systems, including the cardiovascular system, TD makes pyruvate and some amino acids inaccessible. According to earlier research, TD has a negative long-term impact on cardiac contractility, which may eventually lead to heart failure.<sup>3,4,5</sup> The diagnosis of TD is frequently overlooked without any suspicion because clinically obvious TD is now extremely uncommon in affluent nations, and the majority of patients show no symptoms or indicators.<sup>6,7</sup> Physicians can, however, have a reasonable suspicion of heart failure when there is undernutrition and a history of polished rice consumption by the child or the nursing mother of a baby with heart failure. If treatment is not received, the consequences could be severe.

Here, we describe four cases of cardiac beriberi where prompt, effective treatment triggered a significant clinical improvement within a very short period.

The Journal of Ad-din Women's Medical College; Vol. 13 (1), Jan 2025; p 18-22  
<https://doi.org/10.3329/jawmc.v13i1.81325>

1. Professor, Dept. of Paediatrics, Ad-din Women's Medical College, Dhaka
2. Professor, Dept. of Paediatrics, Gonoshasthaya Somaj Vittik Medical College, Dhaka
3. Associate Professor, Dept. of Paediatrics, Ad-din Women's Medical College, Dhaka
4. Associate Professor, Dept. of Paediatrics, Ad-din Women's Medical College, Dhaka
5. Professor and Head, Dept. of Paediatrics, Dhaka Central International Medical College, Dhaka
6. Professor, Dept. of Paediatrics, Ad-din Women's Medical College, Dhaka

**Correspondence:** Mahmuda Hassan, Professor, Dept. of Paediatrics, Ad-din Women's Medical College, Dhaka. Cell: +8801711814940, e-mail: mahmudahasn@yahoo.com

**Received Date :** 2 August 2024

**Accepted Date :** 20 September 2024

These 4 classes were taken randomly and selected from Paediatric Inpatient Department (IPD) of Ad-din Women's Medical College and Hospital.

As there are risks of death from heart involvement and morbidity from permanent psychosis, it is crucial to start thiamine replacement therapy as soon as a thiamine deficiency is identified or even suspected<sup>8</sup>. Since thiamine supplementation can cause symptoms to improve dramatically and quickly, it can even be employed as a diagnostic test in cases of acute heart failure or creeping peripheral neuropathy. For those with thiamine deficiency who have not developed Korsakoff syndrome, the prognosis is promising. Psychosis in Wernicke-Korsakoff syndrome may be everlasting and not get better for months.<sup>9</sup> Clinical symptoms and blood thiamine diphosphate (TDP) levels following therapy are confirmatory for diagnosis in order to confirm TD to do the blood TDP concentrations.

### Case Series

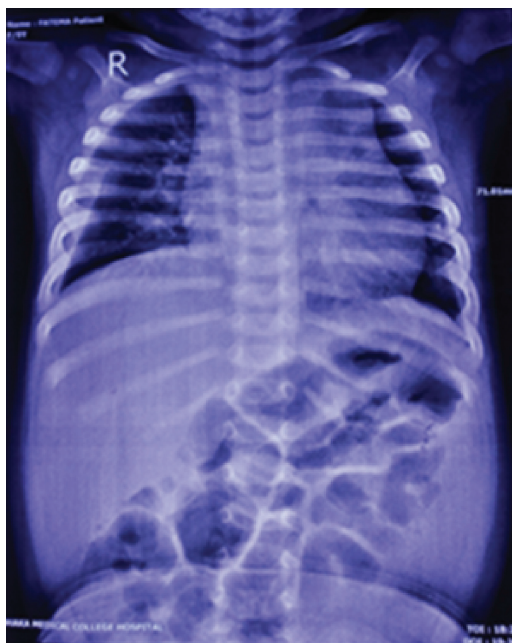
Case 1: A 9-month-old female adopted child who was delivered normally had a history of respiratory distress, and presented with fast breathing, respiratory rate of 66 breaths per minute, severe chest indrawing, and flaring of the ala nasi, she was centrally cyanosed on arrival at the hospital, with a SpO<sub>2</sub> of 83% in room air, cyanosis dissipated after receiving oxygen 2 liters per minute and succeeding development of SpO<sub>2</sub> was > 95%. Blood

pressure was 70/30 mm Hg, the pulse rate was 169 beats per minute, and a gallop was on auscultation. Her temperature was normal, and she had no history of fever. She also had feeding difficulty with vomiting. No significant past illness and immunized as per EPI schedule. She was adopted on her 3<sup>rd</sup> day of life and fed with diluted formula milk for up to 5 months. After 5 months, rice gruel was given along with diluted milk till hospital admission, with occasional history of having rice-based family food without any protein and vegetable intake.

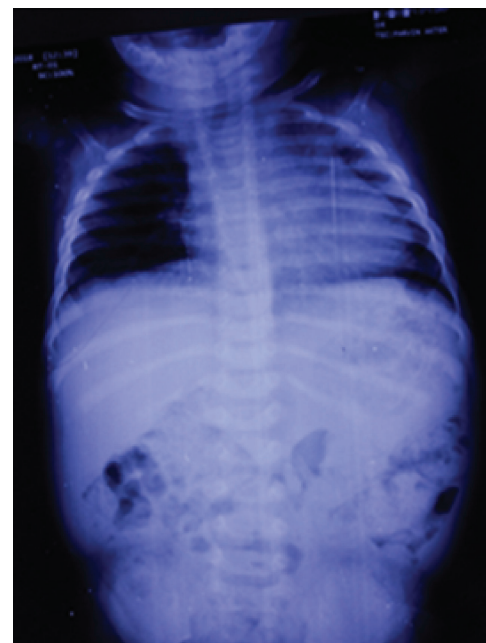
When examined, the baby was afebrile, severely pale, and had tender hepatomegaly. Also had fast breathing and chest indrawing. Her weight for height was on the 50th centile, her weight was 7 kg (below the 3<sup>rd</sup> centile), and her length was 65 cm (at the 3<sup>rd</sup> centile). The infant received the first dosage of furosemide and was kept on nothing orally while receiving restricted intravenous fluid.

The patient was diagnosed provisionally with severe anemia, heart failure, feeding mismanagement, failure to thrive, and presumed sepsis.

CBC showed severe iron deficiency anemia with Hb% 6.3gm/dl, and PBF showed microcytic hypochromic anemia with anisopoikilocytosis with few target cells. Blood C/S subsequently showed no growth, and portable chest X-ray revealed cardiomegaly. It was



Before



After

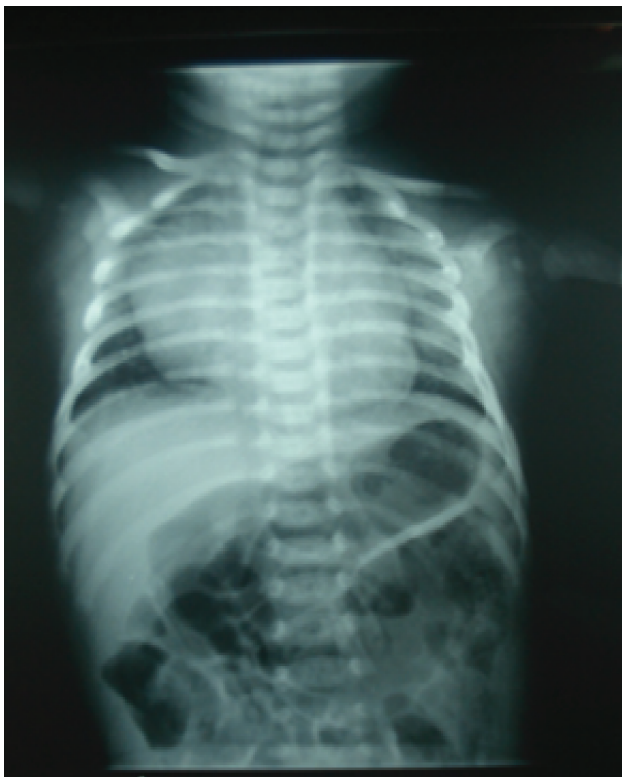**Figure 1:** Chest X-ray before and after treatment (Case 1)

planned to perform an ECG and echocardiogram. Within an hour of arriving at the hospital, injectable thiamine was given at a dose of 25 mg twice daily without waiting for further investigations.

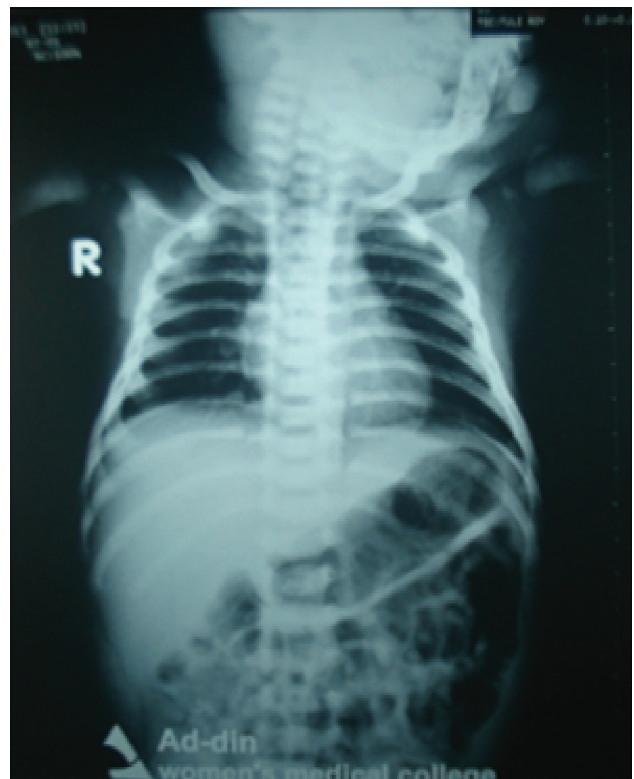According to hospital protocol, antibiotics were started as the bacterial infection was yet to be stopped. Packed Red Blood Cell (PRBC) transfused for anemia after 24 hours of admission. The suspected baby's condition improved surprisingly after getting two doses of injectable thiamine and one dosage of furosemide within eight hours. There was no tachypnea or tachycardia, and the liver size was reduced by 2 cm.

The results of the liver function tests, blood electrolytes, and serum calcium were all within satisfactory levels. The antibiotic was advised to stop on the fourth day after getting blood and urine culture report and kept the patient in the hospital for seven days with regular bedside follow-up for any deterioration clinically or improvement. We continued injectable thiamine, multivitamins, and extra iron. On the seventh day of the hospital stay, a second chest X-ray revealed normal lungs with normal cardiac shadow. The infant was released with dietary advice from a nutritionist for complementary feed.

**Case 2:** A 1½ month baby belonging to a middle-class family was admitted to our emergency with the complaints of sudden reluctance to feed, hoarseness of crying for 3 days, and severe respiratory distress for 1 day. There was no history of fever, cough, cyanosis, runny nose, or aspiration of milk. The baby was delivered by caesarian section at term due to placenta previa. The mother was on regular antenatal checkups & was transfused with 3 units of blood at 32 weeks of gestation due to severe anemia. After the birth of the baby, the mother took only iron & calcium tablets. Mother including the whole family had a regular habit of having polished milled rice & avoidance of leafy vegetables during postpartum period in the fear of gaseous abdominal distension of the baby. On physical examination, the baby was dyspnoic, crying in a hoarse tone, there was tachycardia, tachypnea, hepatomegaly and laterally shifted apex beat. There was no edema or cyanosis. Immediate chest X-ray showed cardiomegaly. A combination of unexplained heart failure and dysphonia led us to suspect infantile beriberi so 12.5 mg of intravenous thiamin was administered. Within 12 hours, features of heart failure started receding and the cry was also improved.



Day 1



Day 7

**Figure 2:** Chest X-ray before and after treatment (Case 2)

**Case 3:** A 4-month-old baby, was admitted with the complaints of acute watery diarrhoea for 4 days & aphonia for 2 days. There was no history of cough, vomiting, respiratory distress, or fever. The baby was fed with breast milk along with diluted formula milk up to one month of age. Since then rice powder had been started mixed with diluted milk & misery (locally available sugar crystals). Feeding history of mother revealed an intake of highly polished milled rice. During postpartum period, the mother did not take any vitamin supplementation. On examination, the baby had oedematous and malnutrition. So, in addition to other measures 12.5mg of injection. Thiamine was administered I/V and in next 24 hours, baby cried with a loud voice.

**Case 4:** A 3-month-old baby boy, only issue of his parents, presented with failure to thrive since one month of age with sudden onset of aphonia for 3 days. He was delivered at home by Normal Vaginal Delivery (NVD) and his birth weight was average. He was being exclusively breastfed but his growth was not satisfactory. His mother's staple food was polished milled rice. They belong to a poor family. His mother was only 16 years of age and was also suffering from malnutrition. On examination along with growth failure, also had angular stomatitis and cheilosis. This suspected baby also received injection thiamin intravenously and his aphonia improved within 72 hours.

### Discussion

Despite being extremely uncommon in the modern period, particularly in affluent nations, cardiac beriberi has been documented on numerous occasions throughout history.<sup>6</sup> Numerous studies have underlined the necessity of having a clinical suspicion of cardiac beriberi in patients who appear with heart failure since, in these situations, proper thiamine replacement can quickly improve cardiac function and avoid disastrous outcomes. Following admission, our patients received thiamine injections along with other medicines as needed and intravenous antibiotics following departmental practice, and significant clinical improvement was noted.

Digoxin was not administered because every patient recovered quickly. At the moment, the following three criteria determine the diagnosis of this illness: 1) A history of nutritional insufficiency and clinical symptoms associated with heart failure. 2) Exclusion of other etiologic types of heart disease. 3) Therapeutic response to thiamine administration.<sup>1</sup> Even with the support of sophisticated, contemporary cardiac imaging modalities

like echocardiography and cardiac magnetic resonance (CMR), they are not available in most situations at peripheral hospitals. In these situations, the diagnosis of cardiac beriberi is commonly missed without suspicion. However, the echocardiographic findings for cardiac beriberi are very similar to those of other forms of dilated cardiomyopathy, i.e., a reduction in Left Ventricle (LV) systolic function and Left Ventricle (LV) enlargement with or without valvular regurgitation. As such, we cannot establish a diagnosis of cardiac beriberi based exclusively on echocardiography.<sup>10, 11,12</sup> However, myocardial edema, apart from LV systolic dysfunction, is not a specific finding for cardiac beriberi. Besides this, myocardial edema may not constantly be present in cardiac beriberi. We did not place an order for laboratory confirmation of TD as mentioned above. The diagnosis of beriberi can be supported and confirmed by measuring blood levels of thiamine pyruvate, urine excretion of thiamine, and its metabolites and these investigations are not readily available in all hospitals. The diagnosis can also be confirmed by the shortage of any of these three criteria.<sup>13</sup> However, determining these compounds takes a lot of time and money, and it might delay diagnosis and treatment, which could be fatal. Because of these factors, thiamine replacement is thought to be the most practical, and treatment if given in such a critical baby without thiamine deficiency would have any negative impacts on health. It is reasonable to assume that TD caused the heart failure if the patient reacts to this experiential thiamine replacement, as we have observed in our cases.

### Conclusion

Due to its vague symptoms and indicators of cardiac beriberi secondary to TD, it is difficult to diagnose. As a result, a combination of the clinician's suspicion, thorough history and physical examinations can save lives with empirical thiamine replacement without doing any harm to the patients along with the other treatment protocols of the hospital.

### References

1. Blankenhorn MA. The diagnosis of beriberi heart disease. *Annals of Internal Medicine*. 1945; 23(3):398-404.
2. Astudillo L, Degano B, Madaule S, Sailler L, Galinier A, Couret B, Arlet-Suau E. Development of beriberi heart disease 20 years after gastrojejunostomy. *The American journal of medicine*. 2003;115(2):157-158.
3. Cappelli V, Bottinelli R, Polla B, Reggiani C. Altered



- contractile properties of rat cardiac muscle during experimental thiamine deficiency and food deprivation. *Journal of molecular and cellular cardiology*. 1990;22(10):1095-1106.
4. Sriram K, Manzanares W, Joseph K. Thiamine in nutrition therapy. *Nutrition in Clinical Practice*. 2012;27(1):41-50.
  5. Wooley JA. Characteristics of thiamin and its relevance to the management of heart failure. *Nutrition in clinical practice*. 2008;23(5):487-493.
  6. Yang JD, Acharya K, Evans M, Marsh JD, Beland S. Beriberi disease: is it still present in the United States?. *The American Journal of Medicine*. 2012;125(10):e5.
  7. Towbin A, Inge TH, Garcia VF, Roehrig HR, Clements RH, Harmon CM, Daniels SR. Beriberi after gastric bypass surgery in adolescence. *The Journal of pediatrics*. 2004;145(2):263-267.
  8. Russell RM, Suter PM, Fauci AS. Vitamin and trace mineral deficiency and excess. 2008; 441-450.
  9. Isenberg-Grzeda E, Kutner HE, Nicolson SE. Wernicke-Korsakoff-syndrome: under-recognized and under-treated. *Psychosomatics*. 2012;53(6): 507-516.
  10. Rao SN, Chandak GR. Cardiac beriberi: often a missed diagnosis. *Journal of tropical pediatrics*. 2010;56(4): 284-285.
  11. Naidoo DP, Gathiram V, Sadhabiriss A, Hassen F. Clinical diagnosis of cardiac beriberi. *S Afr Med J*. 1990; 77(3):125-127.
  12. Lahey WJ, Arst DB, Silver M, Kleeman CR, Kunkel P. Physiologic observations on a case of beriberi heart disease, with a note on the acute effects of thiamine. *The American Journal of Medicine*. 1953;14(2): 248-255.
  13. Lu J, Frank EL. Rapid HPLC measurement of thiamine and its phosphate esters in whole blood. *Clinical chemistry*. 2008;54(5):901-906.