

CASE REPORT

Radio-diagnosis of fecoliths and its non-surgical management in dogs

Arif Khan¹, Mohsin Ali Gazi^{2*}, Suhani Bashir¹, D.M. Dumralia³ and M.S. Bagate¹

¹Department of Animal Husbandry and Veterinary Services, Dadra and Nagar Haveli, Silvassa, India.

²Division of Surgery and Radiology, Sher-e-Kashmir University of Agricultural Sciences and Technology, India.

³Department of Animal Husbandry and Veterinary Services, Dadra and Nagar Haveli, Silvassa, India.

*Corresponding author's e-mail: mohsingazi9975@gmail.com

ABSTRACT

Two cases with a history of cessation of feces for 2 weeks, depression, lethargy and anorexia in two different dogs; a Labrador male and a Doberman female, were presented. On physical examination, abdominal distension along with intense pain was observed. Blood samples were collected from the dogs for hematological and biochemical analyses. The examination revealed an increased percentage of packed cell volume (PCV). By radiological examination, radiopaque material was seen in the large intestinal tract. The condition was suggestive of fecolith. The cases were managed by means of non-surgical management. Through an 11-day long medicinal treatment, the dogs recovered uneventfully.

Keywords:

Case report, dog, fecolith, non-surgical management, radiology

Received : 15 January 2014, Revised: 28 January 2014,
Accepted : 30 January 2014, Published Online: 15 February 2014.

CASE HISTORY & CLINICAL OBSERVATIONS

Two dogs of different breeds (Labrador male and Doberman female) presented to the Veterinary

Hospital Dadra and Nagar Haveli, Silvassa, India with the history of cessation of feces for 2 weeks, depression, lethargy and anorexia. Both of the cases were examined in detail. Deep palpation of abdomen was resisted by both as elicited by pain. Blood examination showed increased percentage of PCV due to hemo-concentration. The radiological examination of both dogs showed radiopaque material in the large intestinal tract (colon in Labrador and colon & cecum in Doberman). Right and left lateral (Figure 1) views were taken.

TREATMENT & MANAGEMENT

Both cases were treated by aggressive fluid therapy comprising of Normal Saline and Dextrose (5%), Oral Docusate Sodium, Augmentin 1.2g, NSAIDS, Meloxicam @0.5mg/kg of body weight (b. wt.), and Tribivet 1ml; each of them were administered through intravenous (IV) route for 5 days. The cases were assessed clinically and by radiological examination of the abdomen on daily basis during the treatment. Each case showed disintegration of the radiopaque material (fecolith) on subsequent days of the treatment (Figure 2). On the 5th day of treatment, Milk of Magnesia (2-4 ml/lb b. wt.) was given orally, followed by rectal Enemata with Liquid Paraffin. Both the cases showed evacuation of the semi hard stool after application of purgatives. Complete recovery was recorded on day

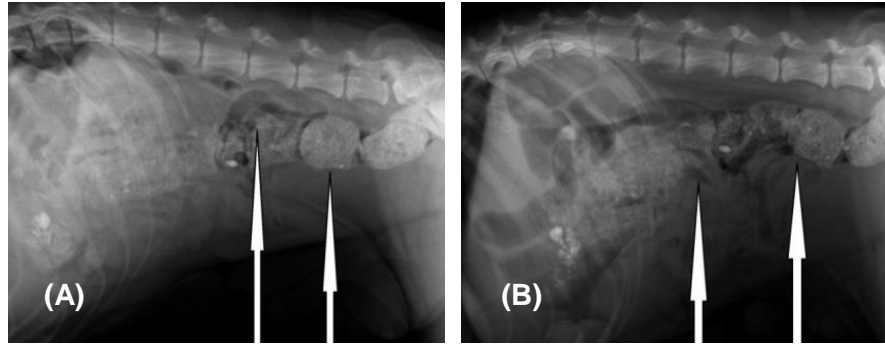


Figure 1. Left lateral views of large intestinal tracts taken from Labrador (A) and Doberman (B). White arrows indicate the colon and cecum impacted with fecoliths.

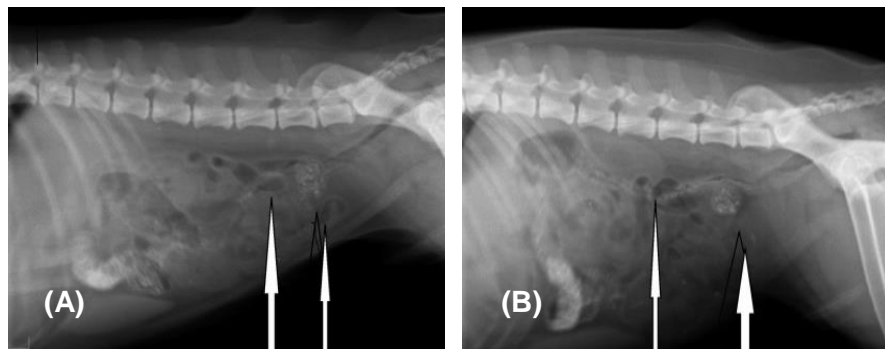


Figure 2. Disintegration of the radiopaque material (arrows in the figures) on subsequent days of the treatment in Labrador (A) and Doberman (B), respectively.

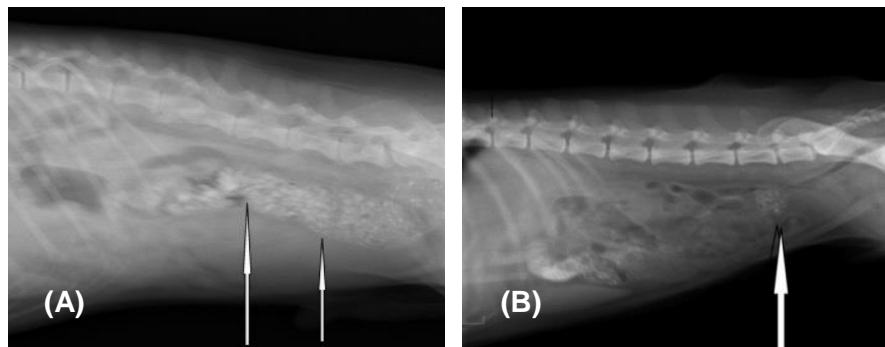


Figure 3. Cases showing evacuation of the semi hard stool (arrows in the figures). Complete recovery was recorded after 11 days treatment in Labrador (A) and Doberman (B), respectively.

11th post medication (Figure 3). of the semi hard stool after application of purgatives. Complete recovery was recorded on 11th day (Figure 3).

DISCUSSION

Cessation of feces in dogs is relatively common. It may be due to functional obstruction or cessation of peristaltic movements of gastrointestinal tract. Obstruction may be partial or complete. Mechanical obstruction of the intestine occurs due to either

intraluminal mass or external compression of the intestinal wall. Intraluminal obstruction can occur due to some foreign body, fecolith, impacted ingesta and huge parasitic infestation (McCull, 2010). Various diagnostic modalities are used in diagnosis of intestinal obstructions such as ultrasonography and digital radiography (Guandalini, 2011).

The present study reports the incomplete obstruction of the intestine in two dogs, its successful medicinal treatment, monitored by a computed radiology system.

Despite considerable advances in diagnostic methods for small intestinal obstruction, plain radiography remains the basic one (Graham et al., 1998). However, survey radiography can be unremarkable in chronic partial obstruction and ileo-colic intussusception (Banerjee et al., 2010). Contrast radiography, with liquid contrast media or barium-impregnated polyethylene spheres, can assist in diagnosis but may not be appropriate in emergency cases and often does not give more information than plain radiography (Talbert et al., 2012). In our study, the lodgments of fecoliths were found in colon and cecum of the dogs.

The cases were managed successfully via medicinal approach (non-surgical) aided by radiology. It is suggested that radiological study could be an important tool for diagnosing fecolith condition in dogs and to monitor the progression of the condition with medical treatment (non-surgical management).

REFERENCES

- Graham K, Leonard KE, Room R, Wild C, Pihl RO, Bois C, Single E (1998). Current directions in research on understanding and preventing intoxicated aggression. *Addiction*, 93: 659-676.
- Guandalini S (2011). Probiotics for prevention and treatment of diarrhea. *Journal of Clinical Gastroenterology*, 45 (Suppl): S149-S153.
- Talbert A, Thuo N, Karisa J, Chesaro C, Ohuma E, Ignas J, Berkley JA, Toromo C, Atkinson S, Maitland K. (2012). Diarrhea complicating severe acute malnutrition in Kenyan children: a prospective descriptive study of risk factors and outcome. *PLoS One*, 7: e38321.
- Banerjee S, Cash BD, Dominitz JA, Baron TH, Anderson MA, Ben-Menachem T, Fisher L, Fukami N, Harrison ME, Ikenberry SO, Khan K, Krinsky ML, Maple J, Fanelli RD, Strohmeyer L (2010). The role of endoscopy in the management of patients with peptic ulcer disease. *Gastrointestinal Endoscopy*, 71: 663-668.
- McCull KEL (2010). *Helicobacter pylori* infection. *The New England Journal of Medicine*. 362: 1597-1604.
- Graham K, Leonard KE, Room R, Wild C, Pihl RO, Bois C, Single E (1998). Current directions in research on