

CLOSURE OF LARGE PATENT DUCTUS ARTERIOSUS BY AMPLATZER SEPTAL OCCLUDER (ASO): A CASE REPORT

Fatema NN¹

Abstract

A large patent ductus arteriosus (PDA) of 15 mm size with severe pulmonary hypertension was detected in an eighteen year old male. He was planned for device closure. After checking reversibility of pulmonary vascular bed, a 16 mm x 14 mm PDA device was deployed without releasing from delivery cable and haemodynamic response of patient was observed for one hour. As there was no hypertensive crisis, implantation of a device was planned. 16 mm device appeared small as there was some leakage of dye. So PDA device was taken out, an 18 mm Amplatzer septal occluder was then used for complete occlusion of huge PDA. Patient was discharged from hospital next morning. Echocardiography before discharge showed no residual shunt, left pulmonary artery stenosis or coarctation of aorta.

Key Words: Closure of patent ductus arteriosus (PDA closure), Amplatzer septal occluder (ASO).

Introduction

PDA is the fifth or sixth most common congenital cardiac defect observed in most surveys carried out in different centres of the world¹. The incidence of isolated PDA has been estimated at 1:2000 to 1:5000 births which is about 10 to 12 percent of all varieties of congenital heart disease^{1, 2}. Surgical closure of PDA though long been established, but number reducing gradually as device closure has achieved popularity amongst patient and paediatric cardiologist as a safe and effective procedure. A variety of techniques have been used since 1967 to achieve non surgical closure of PDA, at present all the paediatric cardiac centers prefer use of Amplatzer Ductus Occluder (ADO) as the safe and effective one³⁻¹⁰. Catheter Intervention of PDA has now become routine in many centers and can be offered to most of the children and with an isolated ductus as "First choice therapy". Amplatzer Ductus Occluder is similar in principal to atrial septal defect (ASD) and ventricular septal defect (VSD) devices¹¹. Ductus occluder is used for moderate and large PDAs and detachable coil for small PDAs at the reported centre as PDA coil are less expensive and effective in small ones¹². In this case a huge PDA was closed with a non traditional device (ASD occluder) for the first time without any complications which lead to writing this report.

Case history

An 18 year old male was diagnosed as a case of PDA incidentally when he reported to a family physician for fever 2 years ago. As he was asymptomatic from cardiac point of view, he never visited any cardiologist for treatment of PDA. For last 03 months, he was experiencing palpitation and effort intolerance. His physician referred him this time to a paediatric cardiologist for proper management. On examination, loud 2nd heart sound and ejection systolic murmur was noticed. His chest X-ray showed prominent pulmonary conus and ECG showed biventricular hypertrophy. He had no clubbing and his SaO₂ was 96%. So paediatric cardiologist planned for device closure of PDA immediately.

Procedure

Patient was sedated with Injection Midazolam and Injection Ketamine and was draped properly. A 5 French (Fr) sheath was introduced to right femoral artery (RFA) and a 6 Fr sheath was introduced to right femoral vein (RFV). An Aortogram was done first to locate PDA and to measure its size. Pulmonary wedge angio showed minimally affected vascular bed. His pulmonary artery pressure was 166/90(70) mm Hg and pulmonary vascular resistance was 7.5 wood units. Patient was heparinized with 100 u/kg heparin and introducer sheath was forwarded to descending aorta through right atrium, right ventricle, pulmonary artery and PDA with the help of GL catheter and exchange wire. A 16 mm x 14 mm size PDA device was deployed in PDA. Aortogram showed residual shunt. Patient was kept on waiting in the table for one hour to look for any haemodynamic change resulting from pulmonary hypertensive crisis. No changes was noticed. The PDA device was then taken out through sheath. An 18 mm ASD occluder was then loaded to the loader and introduced through delivery sheath. Left atrial disc was delivered to aorta and whole system was withdrawn to pulmonary artery. Right atrial disc was released to pulmonary artery. Device was then deployed by unscrewing. Patient was observed for another half an hour in the table. He was then shifted to coronary care unit (CCU) and discharged on next morning. Echocardiography on next morning showed no residual shunt. Systolic pulmonary artery pressure was calculated as 45 mm Hg. No evidence of left pulmonary artery

1. Lt Col Nurun Nahar Fatema, FCPS, Pediatric Interventional Cardiologist, Combined Military Hospital (CMH) Dhaka.

stenosis or coarctation of aorta noticed resulting from mechanical obstruction by left or right atrial disc. Injection Ceftriaxone 1 gm was given intravenously at 12 hour interval for 24 hours. Follow-up appointment schedule was given to the patient at 1, 3, 6, 9, 12, 18, 24 months and yearly thereafter for 3 years.




Fig-1: Showing instruments used for PDA closure with septal occluder.

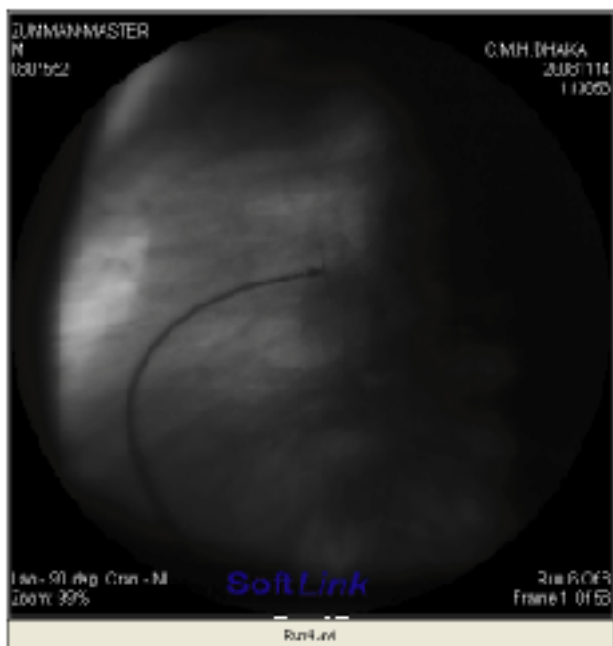


Fig-2: Showing amplatzer septal occluder in position of PDA.

Discussion

The Amplatzer septal occluder is a percutaneous, transcatheter, atrial septal defect closure device intended for the occlusion of Atrial Septal Defects (ASD) in secundum position or patients who required closure of fenestration after a fenestrated Fontan procedure. It is a self expandable double disc device made from a nitinol-wire mesh. Two disc are linked together by a short connecting waist corresponding to size of ASD. In the present case, this idea was taken to place the waist of the septal occluder to PDA and to close its aortic and pulmonary end by left and right atrial disc respectively.

Many options for trans catheter closure of PDA have been introduced over last 35 years. The earlier devices have been replaced by a range of newer and technically superior ones. For PDA closure following options are available³ :

1. Gianturco coil
2. Detachable coil
3. Riedel coil
4. Grifca bag
5. Amplatzer PDA occluder
6. Cardioseal
7. Amplatzer Septal Occluder (ASO)

For ductus closure, most widely used options at present time are coils and Amplatzer devices. Since the concept of PDA coil occlusion in 1992, several investigators have reported larger series using different techniques with variable results. In 1994, Sommer et al¹³ introduced the novel approach of "Snare assistance" in 12 children having PDAs of diameter <3 mm. This technique included introducing the coil into the aortic end of ductus via a retrograde femoral arterial approach and snaring the coil within the main pulmonary artery. To overcome the drawback of various types of devices, both detachable coil (cook) and Amplatzer ductus occluder (ADO) were used in university children Hospital Slovenia and 53 (98%) out of 54 patients had complete closure of the duct¹⁴. Amplatzer ductus occluder is gaining popularity specially for larger ductus now a day¹⁵⁻¹⁸. But there are some ductus which are large in size, tubular and cannot be closed by ductus occluder. Present case was such a case where largest size PDA occluder failed to close the PDA completely and ASD occluder was used as an alternative option. Acute intravascular haemolysis after coil implantation was experienced in four cases in this series¹⁹. Coil embolization was experienced in 3 cases in reported center which were removed with snare catheter and ductus occluder were implanted later on the same sitting.

Conclusion

Coils are primarily applicable for ductus upto 4 mm. But simultaneous use of multiple coils with the help of endocardial biopsy forcep would allow coil occlusion of upto 5-6 mm PDA. For larger ductus, grifca bag, Amplatzer PDA, ASD and VSD (muscular) occluder, cardio seal may be used. Even tubular PDA can be closed with ASD Occluder. It is now standard practice in many center to recommend non surgical closure as the first choice for most children with PDA. Reported center we prefer catheter closure over surgical ligation and for last two years no case of PDA has been referred for surgical ligation. Present case was a challenging case with a huge PDA and severe pulmonary hypertension, where PDA was closed successfully with Amplatzer Septal Occluder.

References

1. Micheal M, Brook MD, Micheal M, Heyman MD. Patent Ductus Arteriosus. In: Moss Adams Heart disease in Infants, children and Adolescents. 5th ed. Baltimore: William and wilkins, 1995.p. 746-764.

2. Fyler DC. Patent Ductus Arteriosus. In: Nadas Paediatric Cardiology. St Louis: Hanley and Belfus, 1992.p.525-34.
3. James L. Wilkinson. Interventional Pediatric Cardiology: Device closures. Indian Journal of Pediatrics 2000; 67: 507-513.
4. Rashkind WJ, Causo CC. Transcatheter closure of a patent ductus arteriosus: Successful use in a 3 kg infant. Pediatric cardiology 1979; 1: 3-7.
5. Rashkind WJ, Mulins CE, Hellenbrand WE, Tait MA. Monsurgical closure of patent ductus arteriosus with PDA occluder systems. Circulation 1987; 75: 583-592.
6. Hills LC. Closure of patent ductus arteriosus using the Rashkind PDA occluder system. Radiogram Today 1989; 55: 20-23.
7. Sievert H, Ensslen R, fach at el. Trans catheter closure of patent ductus arteriosus with the Rashkind occluder. Acute results and Angiographic follow up in adults. Eur Heart J 1997; 128: 1014-1018.
8. Bulbul ZR, Fhey JT, Doyle TP, Hijaji ZM. Transcatheter closure of the patent ductus arteriosus: Comparison between the Rashkind occluding coils and the Rashkind umbrella device. Cathet Cardiovasc Diagn 1996; 39: 355-363.
9. Galal O, D Moor M, al Fadley, Hijaji ZM. Transcatheter closure of the patent ductus arteriosus: Comparison between the Rashkind occluder device and the anterograde Gianturco coil technique. Aust Heart J 1996; 131: 368-373.
10. Arora R, Kalra GS, Nigam M, Khalilullah M, Transcatheter occlusion of patent ductus arteriosus by Rashkind umbrella device: follow up results. Amer Heart J 1994; 128; 539-541.
11. Masura J, Walsh Kp, Thanopoulous B, Chan C, Bass J. Catheter closure of moderate to large sized patent ductus arteriosus using the new Amplatzer duct occluder: Immediate and short term results. J Am Coll Cardiol 1998; 31: 878-882.
12. Howard S. weber MD, Stephen F, Cyran MD. Transvenous "Snare-Assisted" coil occlusion of Patent Ductus Arteriosus. The Americal Journal of Cardiology 1998; 82 : 248-251.
13. Sommer RJ, Gutierrez A, Laiww, parness IA. Use of preformed nitinol snare can improve transcatheter coil delivery in occlusion of patent ductus arteriosus. Am J Cardiol 1994; 74 : 436-839.
14. Podnar T, Gavora P, Masura J. Percutaneous closure of patent ductus arteriosus: Complementary use of detachable cook patent ductus arteriosus coils and Amplatzer duct occluders. Eur J Pediatr 2000; 159 (4): 293-6.
15. Lee CH, Leung XL, Chow WH. Transcatheter closure of the patent ductus arteriosus using an Amplatzer duct occluder in adults. Jpn Heart J 2001; 42: 533-7.
16. Salibaz, Aggoum X, Hqusse 'A', Acar P, Bonnet D, Fraisee A, et al. Percutaneous closure of patent ductus arteriosus with Amplatzer duct occluder. Arch Mal Coeur Vaiss 2000; 93: 533-8.
17. Marwah A, Radhakrishnan S, Shrivastavas S. Immediate and early results of closure of moderate to large patent ductus arteriosus using the new Amplatzer devices. Cardiol Young 2000; 10:208.
18. Thanopoulos B.D, Hakim FA, Hiari A, Goussous Y, Basta E, Zarayelyan AA. Further experience with transcatheter closure of the ductus arteriosus using the Amplatzer duct occluder. J Am Coll Cardiol 2000; 35: 1016-21.
19. Begum NNF, Ahmed AU. Acute Intravascular haemolysis after coil occlusion of patent ductus arteriosus. J Bangladesh Coll Phy Surg 2003; 21: 151-153.
20. Begum NNF, Rahman H, Razzaque AKM, Ahmed S. Coil occlusion of patent ductus arteriosus: Report on nine cases. Chest and Heart Journal 2002; 26: 21-25.