

# Clinical Characteristics of Patients Underwent Frozen Section Biopsy of Ovarian Masses in BSMMU, Dhaka, Bangladesh

Ismat Sultana<sup>1\*</sup> Salma Akhter<sup>2</sup> Shamim Ara Begum<sup>3</sup>  
Syeda Humaira Begum<sup>4</sup> Mohammad Azizul Haque<sup>5</sup> Ayesha Begum<sup>6</sup>

## ABSTRACT

**Background:** Women with suspected early-stage ovarian cancer need surgical staging which involves taking samples from areas within the abdominal cavity and retroperitoneal lymph nodes in order to inform further treatment. Frozen section is an important and helpful adjunct in the intraoperative diagnosis of ovarian tumors. The aim of the study was to evaluate the clinical characteristics of patients undergoing frozen section biopsy in the diagnosis of ovarian malignancies.

**Materials and methods:** This prospective observational study included 30 cases of ovarian masses from the Department of Obstetrics and Gynecology, Bangabandhu Sheikh Mujib Medical University (BSMMU) from March 2014 to August 2014. Clinical feature, sonographic evaluation, CA-125, CA-19-9 and frozen section biopsy report were collected.

**Results:** The mean age was 35.6±12.4 years with range from 14 to 70 years. Frozen section biopsy was true positive in 6 cases and no false positive, 1 false negative and true negative in 23 cases compared to histopathology. Frozen section biopsy has sensitivity, specificity, accuracy, positive predictive and negative predictive values were respectively, 85.7%, 100.0%, 96.7%, 100.0% and 95.8% in evaluation of ovarian masses.

**Conclusion:** The histopathological diagnosis of the present study significantly correlated well with frozen section biopsy findings and the validity tests are almost identical as observed by many investigators.

**Key words:** Frozen section Biopsy; Ovarian masses; Retroperitoneal.

## Introduction

According to Globocan 2018, Ovarian cancers are the 7<sup>th</sup> most common cancers in females worldwide but have the highest mortality rates among all gynaecological cancers.<sup>1</sup> Ovarian cancer is an alarming health problem in Bangladesh with an estimated incidence of 3 122 in 2020, with mortality of 2096 cases.<sup>2,3</sup>

Patients with ovarian masses are presenting a persistent agonizing problem due to their inconsistent clinical presentation, difficulties in early diagnosis and wide variations in histological architecture. During laparotomy for an ovarian swelling, a situation may arise when the surgeon, depending on the gross appearance of the mass, cannot decide with high degree of accuracy about the benignity of the ovarian mass. The need for an instant answer during the operation is an indispensable requisite.<sup>4</sup>

Fine needle aspiration cytology in the preoperative investigation of ovarian tumours has been discouraged since the puncture of the cystic carcinoma might cause intraperitoneal seeding. But frozen section biopsy would provide a rapid diagnosis without the fear of dissemination in case of ovarian cancers.<sup>5</sup> Frozen section biopsy is a valuable tool to help in decision making during operation.<sup>4</sup> Preoperative evaluation of patients with an ovarian mass is usually made by imaging studies and determination of serum levels of tumor markers. Since these methods have limited value for the recognition of ovarian cancer, the diagnosis and the course of the surgery are usually determined by frozen section examination during the operation.<sup>6,7</sup> Despite its limitations, frozen section diagnosis is an important and reliable tool in the clinical management of patients with ovarian tumors. The recommended utilization ratio of frozen section in general surgical practice is between 5% and 15%.<sup>8,9</sup>

1. Medical Officer,  
Chittagong Medical College Hospital, Chattogram.
2. Assistant Professor of Obstetrics & Gynaecology  
Chattogram Maa-O-Shishu Medical College Hospital, Chattogram.
3. Assistant Professor of Obstetrics & Gynaecology  
Cox's Bazar Medical College, Cox's Bazar.
4. Consultant of Obstetrics & Gynaecology  
Fouad Al Khatib Hospital, Cox's Bazar.
5. Assistant Professor of Anaesthesiology & ICU  
Chittagong Medical College, Chattogram.
6. Assistant Professor of Paediatrics  
Chittagong Medical College, Chattogram.

\*Correspondence : **Dr. Ismat Sultana**  
Cell : +88 01819 28 91 79  
Email : dr.ismatsultana@gmail.com

Date of Submission : 10th November 2021  
Date of Acceptance : 26th November 2021

This study was carried out with an aim to assess the socio-demographic status, clinical features of the patients having ovarian masses and to find out the diagnostic accuracy of frozen section biopsy for the diagnosis of ovarian masses.

### Materials and methods

This was a prospective observational study conducted at the Department of Obstetrics and Gynecology, Bangabandhu Sheikh Mujib Medical University (BSMMU) Dhaka, Bangladesh during the period from March 2014 to August 2014. The study was approved by the institutional ethical committee. Written informed consent was obtained from the patients.

Thirty cases of ovarian masses was included using convenient sampling. The patients underwent laparotomy for ovarian masses were finally included. Provisional diagnosis was made on the basis of clinical features and standard biochemical tests. Main variables of interest were clinical feature, sonographic evaluation, CA-125, CA-19-9 and frozen section biopsy report. Other necessary investigations were done if clinically indicated and to prepare the patient for anesthesia.

Histopathological finding was taken as the gold standard. The frozen section diagnosis was compared with the final paraffin section diagnosis in terms of whether it was a non-neoplastic lesion or a benign, borderline and malignant tumor. Data were analyzed by SPSS version 16. Quantitative observations were indicated by frequencies and percentages. For the validity of study outcome, sensitivity, specificity, accuracy, Positive Predictive Value (PPV) and Negative Predictive Value (NPV) of frozen section biopsy in the evaluation of ovarian masses were calculated. The results were presented in tables.

### Results

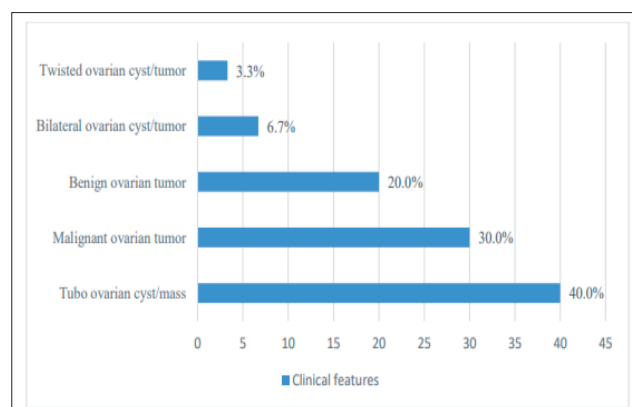
In the studied patients, it was observed that almost one third (30.0%) patients age belonged to 21-30 years. The mean age was  $35.6 \pm 12.4$  years with range from 14 to 70 years. Regarding the educational status, it was observed that more than half (53.3%) patients had completed secondary education followed by 8(26.7%) patients had completed primary and 4(13.3%) patients had completed graduation. Majority (70.0%) of the patients were from lower middle class, followed by 8(26.7%) patients come from lower class and 1(3.3%) patient from upper middle class (Table I).

**Table I** Age distribution and socio-demographic status of the study population (n=30)

Attributes	Frequency	Percentage (%)
Age		
14-20 Years	4	13.3
21-30 Years	9	30.0
31-40 Years	5	16.7
41-50 Years	8	26.7
51-70 Years	4	13.3
Mean $\pm$ SD Years	35.6 $\pm$ 12.4	
Range (Years)	14-70	
Education Status		
Primary	8	26.7
Secondary	16	53.3
Graduate	4	13.3
Illiterate	2	6.7
Socio-economic status		
Lower Class	8	26.7
Lower Middle class	21	70.0
Upper Middle class	1	3.3

Figure 1 shows the clinical features of the study subjects. It was observed that majority (40.0%) of the study subjects were diagnosed as tubo-ovarian cyst/mass followed by 30.0% suspected as malignant ovarian tumor, 20.0% as benign ovarian tumor, 6.7% were bilateral ovarian cyst/tumor and 3.3% were twisted ovarian cyst/tumor.

It was observed that majority (70.0%) of the patients had normal CA-125 ( $\leq 35$  IU/ml) and only 9(30.0%) patients had raised CA-125 ( $>35$  U/ml) (Table II).



**Figure I** Distribution of the study patients according to clinical features (n=30)

**Table II** Distribution of the study patients according to CA-125(n=30)

CA 125 (u/ml)	Frequency	Percentage
$\leq 35$ (Normal)	21	70
$>35$	9	30
Total	30	100.00

The majority (11/30, 36.7%) of the patient had adnexal mass followed by 8(26.7%) patients had ovarian cyst/tumor, 8(26.7%) patients had ovarian solid mass, 2(6.7%) patients had bilateral ovarian tumor solid and/ cystic and 1(3.3%) patients had ovarian thick walled cyst/mass on ultrasonography (Table III).

**Table III** Distribution of the study patients according to ultrasonographic evaluation (n=30)

Ultrasonographic findings	Frequency	Percentage
Adnexal mass	11	36.7
Ovarian cyst/tumor	8	26.7
Ovarian solid mass	8	26.7
Bilateral ovarian tumor solid and/ cystic	2	6.7
Ovarian thick walled cyst/mass	1	3.3
Total	30	100.00

Table IV shows the Frozen section of the ovarian tumor revealed benign in 24 (80.0%) cases and malignant in 6 (20.0%) cases.

**Table IV** Diagnosis of ovarian masses by frozen section (n=30)

Frozen section	n=30	%
Benign	24	80.0
Malignant	6	20.0
Total	30	100.00

Six cases were malignant on frozen section for evaluation of ovarian masses, out of which true positive 6 cases and no false positive cases evaluated by histopathology. A total of 24 cases were benign, that was evaluated by frozen section, among them 1 case false negative and 23 cases true negative identified by histopathology (Table V).

**Table V** Comparison between histopathological diagnosis and frozen section biopsy report of ovarian masses (n=30)

Frozen section	Histopathological diagnosis	
	Malignant (n=7)	Benign (n=23)
Malignant (n=6)	6 (True positive)	0 False positive)
Benign (n=24)	1 (False negative)	23 True negative)

The sensitivity, specificity, accuracy, positive predictive and negative predictive values of frozen section biopsy were respectively, 85.7%, 100.0%, 96.7%, 100.0% and 95.8% in evaluation of ovarian masses (Table VI).

**Table VI** sensitivity, specificity, accuracy, positive and negative predictive frozen section biopsy report in malignant lesions among the ovarian masses (n=30)

Test of validity	Frozen section
Sensitivity	85.7
Specificity	100.0
Accuracy	96.7
Positive predictive value	100.0
Negative predictive value	95.8

## Discussion

A total of 30 patients with clinical features and ultrasonographic findings suggestive of ovarian mass were enrolled in their study. In this present study the mean was found 35.6±12.4 years with range from 14 to 70 years. Schrecengost et al have shown in their study that 85.0% of the benign ovarian tumors were in the age up 20-44 years.<sup>5</sup> Malignant ovarian tumors were more than 45 years of age. In the study of Gol et al it was observed the median age of patients with benign or borderline tumors were relatively compared with patients who had malignant ovarian tumours.<sup>10</sup>

CA-125 is elevated in most cases of ovarian cancer that present clinically. However a review of 14 studies revealed that only 44% of 128 women with stage 1 ovarian cancer had CA-125 levels greater than 35 IU/ml. In the current study it was observed that majority (70.0%) had normal CA-125 level (≤35 IU/ml) and 9(30.0%) had >35 IU/ml. Reviewing all the studies, it appears that the inability of CA-125 to pick up early stage ovarian tumors makes it unsuitable for screening.<sup>11</sup> Only 50% of stage I and II patients shows elevated level of CA-125.<sup>12</sup>

In this present study it was observed that more than three fourth (80.0%) cases were benign and 20.0% cases were malignant in frozen section findings. Ilker et al showed the results of frozen sections were 88.3% benign, 4.2% borderline and 7.5% malignant.<sup>13</sup> Ilvan et al found that benign tumor 56.1%, borderline tumor 6.2% and malignant tumor 19.4% identified by Frozen section.<sup>14</sup> Wootipoom et al. studied 229 cases of ovarian masses in which frozen section diagnosed 54.1% as benign, 30.6% as malignant and 7% suspicious cases.<sup>15</sup> Therefore, the study case showed the similar diagnosis pattern offered by present study in frozen section technique.

Frozen section done for evaluation of ovarian masses in this current series and it was observed that 6 cases were malignant, out of which true positive were 6 cases and no false positive cases evaluated by histopathology. A total of 24 cases were benign, that was evaluated by frozen section, among them 1 case false negative and 23 cases true negative identified by histopathology. Frozen section detected 62(73.8%) cases as benign, 17(20.2%) cases as malignant and 5(6.0%) cases as suspicious. In subsequent histopathological findings, 65(77.4%) cases were confirmed as benign, 17(20.2%) cases as malignant and only 2(2.4%) cases as borderline. Similar results were found in other studies. Ilvan et al. found 6.3 % suspicious and Wootipoom et al. revealed 7% suspicious cases in frozen section.<sup>14,15</sup> The validity of frozen section as histopathological diagnosis in evaluation of malignant lesions and ovarian

masses cases in this study it was observed that sensitivity 85.7%, specificity 100.0%, accuracy 96.7%, positive predictive value 100.0% and negative predictive value 95.8%.

### Limitations

The present study was conducted in a very short period due to time constraints and funding limitations. The small sample size was also a limitation of the present study.

### Conclusion

In conclusion, the histopathological diagnosis of the present study significantly correlated well with frozen section biopsy findings, and the validity tests are almost identical as observed by other studies. Thus clinical characteristics of ovarian masses can help the gynecologists in the rational approach of patient management by keeping the facility of frozen section biopsy in the operation theatre.

### Recommendation

This study can serve as a pilot to a much larger research involving multiple centers that can provide a nationwide picture, validate regression models proposed in this study for future use and emphasize points to ensure better management and adherence.

### Disclosure

All the authors declared no competing interest.

### References

1. Bray F, Ferlay J, Soerjomataram I, Siegel RL, Torre L A, Jemal A. Global cancer statistics 2018: GLOBOCAN estimates of incidence and mortality worldwide for 36 cancers in 185 countries. *CA Cancer J Clin.* 2018;68(6):394-424.
2. Cancer registry 2018, National Institute of Cancer Research and Hospital (NICRH), Dhaka, Bangladesh. [http://whobangladesh.healthrepository.org/bitstream/123456789/282/1/Publication\\_Cancer\\_Registry\\_Report.pdf](http://whobangladesh.healthrepository.org/bitstream/123456789/282/1/Publication_Cancer_Registry_Report.pdf).
3. Globocon. 2020. Bangladesh. <https://gco.iarc.fr/today/data/factsheets/populations/50-bangladesh-fact-sheets.pdf>.
4. Souka S, Kamel M, Rocca M, El-Assi M, Hebeishy, Sheir SH. The combined use of cytological imprint and frozen section in the intraoperative diagnosis of ovarian tumors. *Int J GynecolObstet.* 1990; 31:43-46.
5. Schrecengost A. Ovarian mass-benign or malignant? *ARON Journal.* 2002; 78:610-629.
6. Wakahara F, Kikkawa F, Nawa A, Tamakoshi K, Ino K, Maeda O et al. Diagnostic efficacy of tumor markers, sonography and intraoperative frozen section for ovarian tumors. *GynecolObstet Invest.* 2001; 52:147-152.
7. Lim FK, Yeoh CL, Chong SM, Arulkumaran S. Pre and intraoperative diagnosis of ovarian tumours: How accurate are we? *Aust NZ J ObstetGynaecol.* 1997;37:223-227.
8. Kern WH. Frozen sections. Letter to the editor. *JA-MA.* 1985; 253:512.
9. Kindschi GW. Frozen sections. Their use and abuse. *JAMA.* 1984;251:2559-2560.
10. Gol M, Baloglu A, Yigit S, Dogan M, Aydin C, Yensel U. Accuracy of frozen section diagnosis in ovarian tumors: Is there a change in the course of time?. *Int J Gynecol Cancer.* 2003;13:593-597.
11. Andolf E, Jorgensen C. Simple Adnexal Cysts Diagnosed By Ultrasound In Postmenopausal Women. *J Clin Ultrasound.* 1988; 16:301-303.
12. Rassool R, Shah ZA, Salahuddin M, Bashir M. CA-125 Tumor Marker For Ovarian Malignancies. *JK Practitioner.* 2003;224-225.
13. Ilker A, Aykut B, Muge H, Ibrahim HM, Ulku OB, Sener G, Suna S. Accuracy of intra-operative frozen section in the diagnosis of ovarian tumours. *Tumours, Zonguldak, JPMA.* 2011; 61:856.
14. Kayikcioglu F, Pata O, Cengiz S, Tulunay G, Boran N, Yalvaç S, Köse MF. Accuracy of frozen section diagnosis in borderline ovarian malignancy. *GynecolObstet Invest.* 2000; 49(3):187-189.
15. Wootipoom V, Dechsukhum C, Hanprasertpong J, Lim A. Accuracy of Intraoperative frozen section in diagnosis of ovarian tumors. *J Med Assoc Thai.* 2006;89(5):577-582.