



# ECTOPIC PANCREAS PRESENTING AS A GASTRIC SUBMUCOSAL MASS WITH DIAGNOSTIC DILEMMA – A CASE REPORT

Mohammed S<sup>1</sup>, Ullah AKMA<sup>2</sup>, Shawon GM<sup>3</sup>, Rahman MA<sup>4</sup>, Sarder MNI<sup>5</sup>

## Article History:

Received: 8 February 2026

Accepted: 1<sup>st</sup> March 2026

## Keywords:

*Ectopic Pancreas, Pancreatic ectopia, Pancreatic heterotopia, Accessory Pancreas, Aberrant Pancreas.*

## Abstract:

*Pancreatic ectopia is the presence of the pancreatic tissue in a location that is not typical for pancreas. This type of congenital anomaly presents with varied degrees on presentations but those do not initially rise the clinical suspicion of this anomaly. We present such a case in a 31-year-old man who presented to our East West Medical College Hospital with features of gastritis. He underwent lower partial gastrectomy, and the histopathological examination revealed it was an ectopic pancreas. Post-operatively he experienced bile reflux gastritis which was managed conservatively.*

*EWM CJ Vol. 14, No. 2, July 2026: 251-255*

## Introduction

Pancreatic ectopic a relatively uncommon congenital anomaly where the pancreatic tissue is located in atypical locations.<sup>1</sup> The incidence is from 0.55 to 13.7%.<sup>2,3,4</sup> This ectopic pancreatic tissue has no direct communication with the main pancreas and has separate blood and nerve supplies.<sup>5</sup> Some other congenital anomalies includes pancreatic divisum, annular pancreas pancreatic dysplasia also have been documented.<sup>6,7</sup> pancreatic ectopia has been located in stomach, duodenum, jejunum, ileum, liver, biliary channel, fallopian tube etc. Among them, gastric antrum is more frequent, specially within 6 cm from the greater curvature in the pylorus.<sup>8-10</sup> It is usually found in the submucosal layer or in the muscularis propria.<sup>11</sup> The cause of such condition is not quiet identified rather some hypotheses are being developed.<sup>12</sup> It can be asymptomatic or present with a broad spectrum of clinical features like dyspepsia,

epigastric fullness, hematemesis and melena, intestinal obstruction and perforations.<sup>3,4,13-15</sup>

## Case Report

A 31-year-old gentleman, a remittance worker in Abu Dhabi, came to East West Medical College Hospital with repeated attacks of burning sensation in his epigastric region for 2 years. It occurred every 2 to 3 months interval with normal intervening episodes, aggravated by ingestion of spicy and oily food and partially relieved by antacids associated with regurgitation and nausea. With these complaints he repeatedly visited doctors and hospitals, received oral and even injectable medications. After that he would be okay for few weeks, but the problems recurred. His day-to-day life and work life were severely hampered. His bowel and bladder habits were normal and there was no history of significant weight loss. He was heavy coffee drinker. He had no comorbidities.

1. Dr. Saad Mohammed, Associate Professor and Head, Department of Surgery, East-West Medical College and Hospital (EWMCH), Nishat Nagar, Turag, Dhaka, Bangladesh.
2. Dr. A.K.M. Ahsan Ullah, Professor and Head, Department of Surgery, Northern Medical College Hospital, Dhanmondi, Dhaka, Bangladesh.
3. Dr. Galib Mohammad Shawon, Associate Professor, Department of Surgery, East-West Medical College and Hospital (EWMCH), Nishat Nagar, Turag, Dhaka.
4. Dr. Md. Atiar Rahman, Professor, Department of Surgery, Bangladesh Medical University, Shahabag, Dhaka, Bangladesh.
5. Dr. Md. Nazrul Islam Sarder, Associate Professor, Department of Anesthesiology, East-West Medical College and Hospital, Nishat Nagar, Turag, Dhaka

**Address of Correspondence:** Dr. Saad Mohammed, Associate Professor and Head, Department of Surgery, East-West Medical College and Hospital (EWMCH), Nishat Nagar, Turag, Dhaka, Bangladesh. Phone: +8801534531420. E-mail address: [saadsmsh@gmail.com](mailto:saadsmsh@gmail.com)

About a month ago he underwent upper GI endoscopy which revealed reflux esophagitis, mild antral gastritis with well-defined submucosal lesion (Figure 1) in the antrum and erosions in first part of duodenum, no biopsy was obtained. He was advised for further investigations and possible need of surgical intervention. He came back to Bangladesh on his own account to stay beside his family members and receive further treatment.

During clinical examination we found him asymptomatic. BMI was 27, non-anaemic and vitals were within normal limits. Abdominal and respiratory systems revealed no abnormalities. CBC, serum creatinine, serum electrolytes, ECG, Echocardiography, random blood sugar, serum TSH and serum albumin were within normal limits. Urea breath test came out negative. We did a repeat Upper GI endoscopy and found Grade A reflux esophagitis at lower end of esophagus, a small submucosal swelling with normal overlying mucosa seen at the antrum (Figure 2) and multiple erosions seen at the body. Duodenum was normal. Biopsy was taken from the swelling. The comment in the report was GIST or lipoma of the stomach with reflux esophagitis with erosive gastritis. Histopathology of the biopsied tissue revealed chronic gastritis. A Contrast CT scan of abdomen was done which revealed mild wall thickening around the gastric antrum with maximum thickness measuring about 8-10 mm but no definite soft tissue mass lesion nor abnormal enhancement seen.

With these findings we opted for Endoluminal Sonography (EUS) of stomach which reported a small heteroechoic submucosal lesion, about 6 mm X 12 mm in size in the antrum. The lesion was free from the muscularis propria and no blood vessels nor necrosis was seen within the lesion. No surrounding lymphadenopathy seen (Figure 3 and 4). The impression was lipoma or GIST.

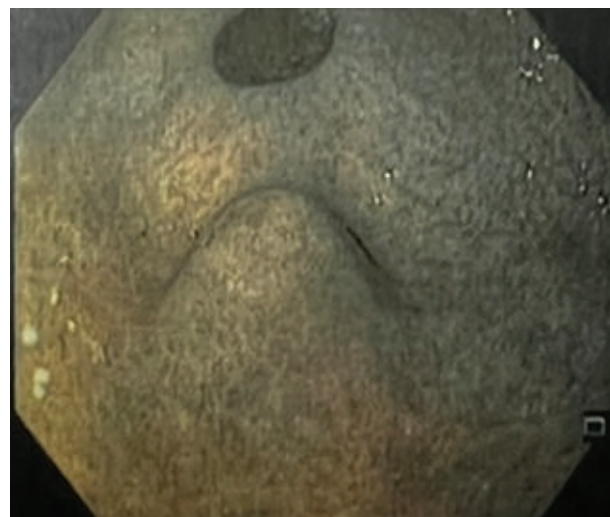
With these findings we devised a tumor board and planned for Endoscopic Submucosal Dissection. Despite adequate counselling the patient and the patient party strongly refused any more upper GI endoscopic procedures due to fearful experiences with previous two occasions. So, we planned for open procedure.

After adequate preparation, we did the laparotomy under general anesthesia with upper midline incision.

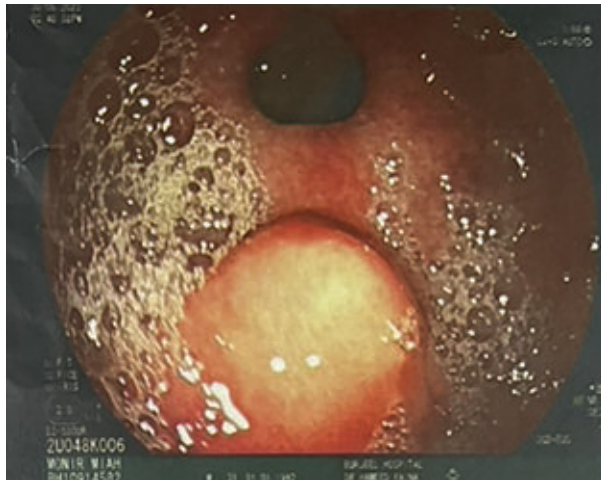
Per-operative findings were: firm to hard partially mobile lesion in the pylorus near greater curvature, about 1 cm proximal to prepyloric vein. Rest of the gut, liver and other organs appeared normal. There was no lymphadenopathy. After taking in consideration of the consistency, we opted for lower partial gastrectomy with retrocolic loop gastrojejunostomy. The specimen was sent for histopathology with adequate labelling.

In the histopathological report, the microscopic examination revealed heterotrophic pancreatic tissue in the submucosa of the lower part of stomach, no malignancy seen.

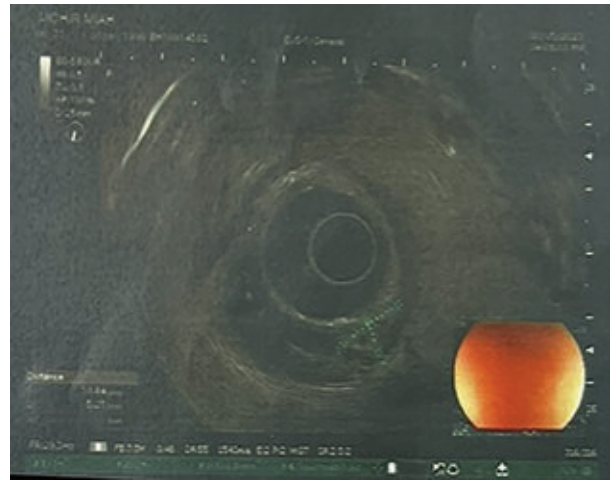His initial post-operative period was uneventful. He was put on diet from the 4<sup>th</sup> post-operative day. But on 7<sup>th</sup> post-operative day he started vigorous vomiting after meals with was bilious but non bloody. He also started experiencing regurgitations. It was diagnosed as bile reflux gastritis and he was again put on nothing per oral, 2 hourly nasogastric suction, intravenous fluid, medications, especially sucralfate and famotidine and nutritional support. A gastrograffin contrast swallow and meal X-rays were done which revealed there was passage of dye through the stoma with well-maintained afferent and efferent loops. slight mucosal thickening near the stomal site was suspected. With these treatments he recovered completely, and his abdominal stitches were removed on 13<sup>th</sup> post operative day and he was discharged on 14<sup>th</sup> post operative day.



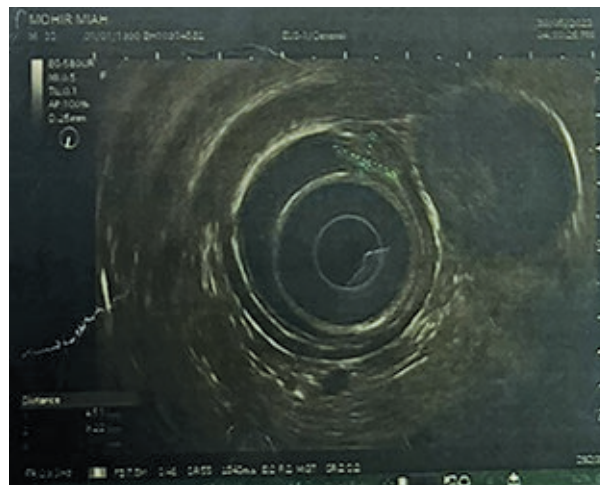
**Figure 1:** First Upper GI Endoscopy showing well-defined submucosal lesion in the antrum.



**Figure 2:** Second Upper GI Endoscopy showing nodular protrusion in the pylorus.



**Figure 3:** Endoluminal Sonography (EUS) of stomach which reported a small heteroechoic submucosal lesion



**Figure 4:** The lesion was free from the muscularis propria and no blood vessels nor necrosis was seen within the lesion.

**Table-I**

*Histological classification of ectopic pancreas*

Classification	Heinrich's classification	Fuentes's classification
I	All components of normal pancreatic tissue, including acini, ducts, and pancreatic islet cells	All components of normal pancreatic tissue, including acini, ducts, and pancreatic islet cells
II	Composed of acini and ducts, without pancreatic islet cells	Composed of ducts
III	Composed of ducts	Composed of acini (exocrine)
IV		Composed of pancreatic islet cells (endocrine)

**Discussion**

In 1727, Jean Schultz first described ectopic pancreas.<sup>16</sup> Klob et al. first described its histological

pattern.<sup>17</sup> Ectopic pancreas is the presence of pancreatic tissue in a location that has no anatomical, vascular or neural connections to the pancreas itself.<sup>18</sup>

The aetiology is still unknown but there are a few hypotheses. Retention of duodenal diverticula participating in pancreatic organogenesis during embryogenesis, metaplastic transformation and later differentiating of endodermal tissues within the gastric mucosa, loss of function of GATA4 gene which is responsible for regulation of cellular differentiation and determination of fate in embryogenesis are postulated.<sup>19,20</sup>

The location of the ectopic pancreas varies from stomach (26-38%), duodenum (28-36%), jejunum (16%), ileum, Meckel's diverticulum, gallbladder, ampulla of Vater, umbilicus and even in middle ear and brain. Among these, gastric submucosa near the pylorus is the commonest site.<sup>21-26</sup>

Most cases are asymptomatic, incidentally diagnosed during histopathological examinations.<sup>27</sup> Symptomatic cases are presented with dyspepsia and early satiety, abdominal pain, regurgitation, nausea, vomiting, hematemesis and melena.<sup>3,4,28</sup> Some cases with acute intestinal obstruction and intestinal perforations also have been documented.<sup>13-15</sup>

Clinical diagnosis of ectopic pancreas is somewhat difficult. During upper GI endoscopy mucosal protrusion or bulging can be observed like in our case but the endoscopic conventional biopsies are bound to fail as the lesion is submucosal or even beneath.<sup>20,29,30</sup> In CT scans, it appears as round or oval mass in the stomach wall, contrast enhancement is similar to that of pancreas.<sup>31,32</sup> Endoluminal Ultrasonography (EUS) can visualize morphological character of pancreatic ectopica and can find out the exact location. A fine needle aspiration through EUS can help in preoperative diagnosis.<sup>33-36</sup> However, leiomyoma, lipoma, GIST, carcinoids can be the differentials. The histopathological features were first documented by Klob in 1859.<sup>17</sup> In 1909, Heinrich described a histological classification with 3 types but in 1973, Fuentes included a fourth type.<sup>23,37</sup> [Table 1]

Endoscopic treatment is widely practiced in such ectopic pancreas treatment for the submucosal types. Endoscopic submucosal dissection, submucosal tunnel endoscopic resection, endoscopic high frequency resection, mucosal resection and full thickness resection techniques have been described.<sup>38-40</sup> But if it is in the muscularis layer, involving full thickness wall, growth is not accessible through endoscopy then local surgical excision is an

option. And if malignancy is suspected, aggressive surgical resection is advised.<sup>41-42</sup>

### Conclusions

Despite rare incidence, upper GI symptoms with Upper GI endoscopy showing mucosal protrusion in the stomach and duodenum with normal overlying mucosa and endoscopic biopsy revealing normal or gastritis histology, the differential diagnosis of ectopic pancreas is to be kept in mind. Endoluminal Ultrasonography (EUS) can provide information of great value. Endoscopic treatment is the best treatment of choice.

### Acknowledgements

We acknowledge our respected patient and his relatives who consented to write and publish this case report and provide us with necessary information.

### Conflict of interest:

Nothing to declare.

### References:

- Mundackal N, Arslan ME, Decker C, Lee H, Nigam A. The removal of ectopic pancreas to prevent carcinoma development. *Am J Surg* 2021;222:1196-1197.
- Thoeni RF, Gedgudas RK. Ectopic pancreas: usual and unusual features. *Gastrointest Radiol* 1980;5(1):37e42.
- Pang LC. Pancreatic heterotopia: a reappraisal and clinicopathologic analysis of 32 cases. *South Med J* 1988;81:1264e75.
- Marshall SF, Curtiss FM. Aberrant pancreas in stomach wall. *Surg Clin North Am* 1952;32:867e75.
- Hashimoto R, Matsuda T. Jejunal Ectopic Pancreas. *Clin Gastroenterol Hepatol* 2019;17:A43.
- Borghei P, Sokhandon F, Shirkhoda A, Morgan DE. Anomalies, anatomic variants, and sources of diagnostic pitfalls in pancreatic imaging. *Radiology* 2013;266:28-36.
- Breunig M, Merkle J, Wagner M, Melzer MK, Barth TFE, Engleitner T et al. Modeling plasticity and dysplasia of pancreatic ductal organoids derived from human pluripotent stem cells. *Cell Stem Cell* 2021;28:1105-1124.e19
- Liu X, Wu X, Tuo B, Wu H. Ectopic pancreas appearing as a giant gastric cyst mimicking gastric lymphangioma: a case report and a brief review. *BMC Gastroenterol* 2021; 21:151.
- Matsumoto T, Tanaka N, Nagai M, Koike D, Sakuraoaka Y, Kubota K. A case of gastric heterotopic pancreatitis resected by laparoscopic surgery. *Int Surg* 2015; 100: 678-682.
- Qian L, Yang J, Zhang J. Gastric ectopic pancreas adenocarcinoma: A case report and literature review. *Saudi Med J* 2023; 44:1174-1179.

11. Ourô S, Taré F, Moniz L. [Pancreatic ectopia]. *Acta Med Port* 2011; 24: 361-366.
12. Jiang LX, Xu J, Wang XW, Zhou FR, Gao W, Yu GH, Lv ZC, Zheng HT. Gastric outlet obstruction caused by heterotopic pancreas: A case report and a quick review. *World J Gastroenterol* 2008; 14:6757-6759
13. Fragoso AC, Correia-Pinto J, Carvalho JL, et al. Ectopic pancreas and foveolar hyperplasia in a newborn: a unifying etiopathogenesis for gastric outlet obstruction. *J Pediatr Gastroenterol Nutr* 2003;39:92e4.
14. Joo YE, Kim HS, Choi SK, et al. Massive gastrointestinal bleeding caused by ectopic pancreas mimicking jejunal tumor. *Digestion* 2001;64:133e6.
15. Mulholland K, Wallace W, Epanomeritakis E, et al. Pseudocyst in gastric ectopic pancreas. *JOP* 2004;5:498e501.
16. Tang, X.-B.; Liao, M.-Y.; Wang, W.-L.; Bai, Y.-Z. Mesenteric Heterotopic Pancreas in a Pediatric Patient: A Case Report and Review of Literature. *World J. Clin. Cases* 2018,6:847–853.
17. Lee, M.J.; Hyuck Chang, J.; Maeng, H.; Young Park, J.; Sun Im, Y.; Ho Kim, T.; Han, S.W.; Sang Lee, D. Ectopic Pancreas Bleeding in the Jejunum Revealed by Capsule Endoscopy. *Clin. Endosc.* 2012, 45:194–197.
18. Kim, J.Y.; Lee, J.M.; Kim, K.W.; Park, H.S.; Choi, J.Y.; Kim, S.H.; Kim, M.A.; Lee, J.Y.; Han, J.K.; Choi, B.I. Ectopic Pancreas: CT Findings with Emphasis on Differentiation from Small Gastrointestinal Stromal Tumor and Leiomyoma. *Radiology* 2009, 252:92–100.
19. Chandan, V.S.; Wang, W. Pancreatic Heterotopia in the Gastric Antrum. *Arch. Pathol. Lab. Med.* 2004, 128:111–112.
20. Subramanian, M.; Wee, E.; Desai, V.; Peh, W.C.G. Clinics in Diagnostic Imaging (158). Duodenal Ectopic Pancreas. *Singap. Med. J.* 2014, 55:629–634.
21. Sathyanarayana, S.; Deutsch, G.; Bajaj, J.; Friedman, B.; Bansal, R.; Molmenti, E.; Nicastro, J.; Coppa, G. Ectopic Pancreas: A Diagnostic Dilemma. *Int. J. Angiol.* 2012;21:177–180.
22. O'Malley, R.B.; Maturen, K.E.; Al-Hawary, M.M.; Mathur, A.K. Case of the Season: Ectopic Pancreas. *Semin. Roentgenol.* 2013;48:188–191.
23. Trifan A.; Târcoveanu E.; Danciu M.; Hu tana su C.; Cojocariu C.; Stanciu C. Gastric Heterotopic Pancreas: An Unusual Case and Review of the Literature—PubMed. Available online: <https://pubmed.ncbi.nlm.nih.gov/22720312>
24. Abdelgabar, A.; Wojciechowski, M.; Van de Vijver, E.; Ruppert, M.; Hubens, G.; Balliu, L.; Creytens, D.; Vaneerdeweg, W. Ectopic Pancreatic Tissue at the Umbilicus in Childhood: A Case Report and Review of the Literature. *Acta Chir. Belg.* 2013;113:452–454.
25. Heller, R.S.; Tsugu, H.; Nabeshima, K.; Madsen, O.D. Intracranial Ectopic Pancreatic Tissue. *Islets* 2010;2:65–71.
26. Lu, X.; Tong, Y.; Bi, R.; Sun, Q.; Ding, J. Heterotopic Pancreas in Middle Ear: A Case Report. *J. Int. Adv. Otol.* 2022;18:537–540.
27. Ogata, H.; Oshio, T.; Ishibashi, H.; Takano, S.; Yagi, M. Heterotopic Pancreas in Children: Review of the Literature and Report of 12 Cases. *Pediatr. Surg. Int.* 2008;24:271–275.
28. Henderson, L.; Nour, S.; Dagash, H. Heterotopic Pancreas: A Rare Cause of Gastrointestinal Bleeding in Children. *Dig. Dis. Sci.* 2018;63:1363–1365.
29. Wei R, Wang QB, Chen QH, Liu JS, Zhang B. Upper gastrointestinal tract heterotopic pancreas: findings from CT and endoscopic imaging with histopathologic correlation. *Clin Imaging* 2011;35:353-359.

©2026 Mohammed S et al.; This is an Open Access article distributed under the terms of the Creative Common Attribution License (<http://creativecommons.org/licenses/by/4.0>), which permits unrestricted use, distribution, and reproduction in any medium, provided the original work is properly cited.

#### Peer-Review History:

The peer review history for this paper can be accessed here: <https://ewmch.com/review/>