

Morphometrical and Topographical Anatomy of Position of Nutrient Foramen on Fully Ossified Left Femur

Md. Shahajahan Chowdhury¹, Humaira Naushaba², Jahanara Begum³, Shameem Ahmed⁴,
Laila Farjana khan⁵, Tanvir Hossain Parash⁶, Rubina Qashem⁷

Abstract

Background: The femur is the typical long bone of lower limb which extends from the pelvis to the knee. It forms the skeleton of the thigh, bears body weight, supports movement of legs; provide attachment to muscles, form blood cells and acts as a store house for calcium and phosphate. The nutrient foramina are cavities that conduct the nutrient arteries and the peripheral nerves. The majority blood supply for femur originates from the nutrient arteries, mainly during the growing period and during the early phase of ossification. In bone grafts the nutrient blood supply is crucial and it should be preserved in order to promote the fracture healing. **Objective:** The anatomy of nutrient foramen of femur is very essential for orthopedic & vascular surgeons as well as to radiologists for planning of treatment. **Materials and method:** This cross sectional study was carried out in the department of Anatomy, Sir Salimullah Medical College, Dhaka, Bangladesh from July 2011 to June 2012. The study comprised 199 fully ossified left sided dry femur of both sex (n=89 male, n=110 female). Sampling technique was purposive. Morphometric and topographic study was carried out on all samples by direct physical and photographic methods. **Results:** The most common position of nutrient foramen on the shaft of femur was found on the middle 1/5th in both male and female femur (50.78% in male and 56.86% in female respectively). **Conclusion:** The anatomical knowledge about this study might be useful in certain surgical procedures as well as micro vascular bone transfer to preserve the circulation.

Keywords: Nutrient foramen, morphometry, topography.

Delta Med Col J. Jan 2013;1(1):13-15

1. Assistant professor, Department of Anatomy, Delta Medical College, Dhaka, Bangladesh.
2. Professor & Head, Department of Anatomy, Sir Salimullah Medical College, Dhaka, Bangladesh.
3. Professor & Head, Department of Anatomy, Delta Medical College, Dhaka, Bangladesh.
4. Associate Professor, Department of Anatomy, Delta Medical College, Dhaka, Bangladesh.
5. Assistant Professor, Department of Anatomy, Dhaka National Medical College, Dhaka, Bangladesh
6. Assistant professor, Department of Anatomy, Shatkhira Medical College, Shatkhira, Bangladesh.
7. Assistant professor, Department of Anatomy, East West Medical College, Dhaka, Bangladesh.

Correspondence: Dr. Md. Shahajahan Chowdhury. e-mail: shahajahan001@yahoo.com

Introduction

The femur is supplied by nutrient artery which enters the bone obliquely through the nutrient foramen, which is directed away from the growing end. Henderson reported that the position of nutrient foramen are variable and may alter during the growth.¹ It is important that the arterial supply be preserved in free vascularized bone grafts, so that the osteoblasts and

osteocytes survive. When the bone graft is taken, the vascularization of the remaining bones has to be considered. Since there are few reports available about the position of nutrient foramen of the femur, the aim of the present study was to find out the topographic anatomy and morphometry of position of nutrient foramen of fully ossified left femur which may help the

orthopedic and vascular surgeons as well as radiologist for planning of treatment. Femur is ossified completely by the age of twenty-five years. So it achieves its adult form and fixed measurement after this age.² According to reported observation, left lower limb is functionally dominant in majority of human beings.³ On this basis left sided adult femur was considered as sample.

Materials and method

This cross sectional study was conducted in the department of Anatomy in Sir Salimullah Medical College, Dhaka, Bangladesh from July 2011 to June 2012 on 199 fully ossified left sided dry femur. Among those 89 were of male and 110 were of female skeleton. The position of nutrient foramen on the shaft of left femur was measured directly using digital slide calipers and scale, and indirect photographic measurement was done by digital camera and computer. All measurements were recorded in metric unit-centimeters (cm). Data were recorded and expressed as proportions.

Procedure for identifying the position of nutrient foramen on shaft of femur

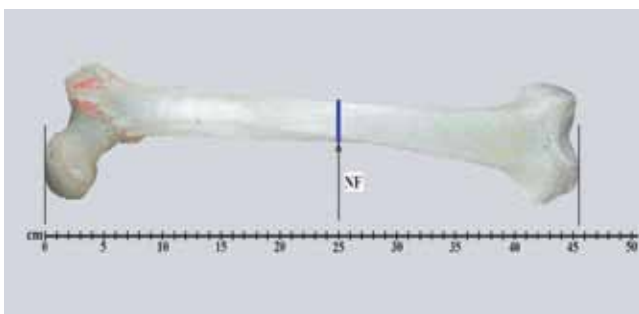


Fig1: Procedure for identifying the position of nutrient foramen (NF).

Only diaphyseal nutrient foramens were observed in all the bones. The shaft of the femur was divided into five equal parts. An elastic rubber band was applied around the proximal end of the nutrient foramen and photograph was taken with digital camera. The positions of nutrient foramens were observed physically and topographically.⁴

Results

Table I shows the distribution of position of nutrient foramen between male and female. It was found that the most common position was on the middle 1/5th both in male and female femur (50.78% male and 56.86% female) followed by upper 1/5th and the lowest proportion on lower-most 1/5th in both sex.

Table I: Position of nutrient foramen in male and female femur

Position of nutrient foramen	Sex	
	Male (n=89)	Female (n=110)
Upper-most 1/5 th	8 (7.82%)	10 (9.80%)
Upper 1/5 th	27 (27.34%)	15 (14.71%)
Middle 1/5 th	49 (50.78%)	58 (56.86%)
Lower 1/5 th	11 (11.72%)	14 (13.73%)
Lower-most 1/5 th	2 (2.34%)	05 (4.90%)

Discussion

The diaphysis of femur is irrigated by one or more nutrient arteries that pierce the compact bone and divide in the medullary cavity into ascending and descending branches while accompanied by the terminal branches of numerous metaphyseal and epiphyseal arteries.⁵ The transplant of the femoral diaphysis can use, the deep femoral artery, if the lateral circumflex femoral artery is protected.⁶ According to another researcher it was observed the position of nutrient foramen on the shaft of fully ossified left femur on the upper most 1/5th in 10.60% male, 9.60% female, on the upper 1/5th in 25.40% male, 26.40% female, on the middle 1/5th in 50.10% male, 51.10% female samples, on the lower 1/5th in 8.90% male, 6.90% female samples, on the lower most 1/5th in 5.00% male and 6.00% female samples.⁷ Above report is similar to our study. In another study they observed the position of nutrient foramen on shaft of male femur on the upper most 1/5th in 20.20% male, 21.60% female samples, on the upper 1/5th in 33.80% male, 32.40% female samples, on the middle 1/5th in 25.50% male, 20.30% female samples, on the lower 1/5th in 18.50% male, 22.70% female samples and the lower most 1/5th

in 2.00% male and 3.00% female samples.⁸ This observation is not consistent with ours. These discrepancies may be due to influence of genetic factor and food habit on growth pattern of the femur of study populations.⁹

The present study was conducted with an attempt to find out the position of nutrient foramen of left femur which might help the anatomist, orthopedic surgeon and vascular surgeon for planning of treatment in Bangladeshi population. Further large scale research with larger sample size, wider age group and radiographic study is recommended.

References

1. Henderson RG. The position of nutrient foramen in the growing tibia and femur of rat. *J Anat.* 1978;125(3):593-99.
2. Mahadevan V. Ankle and foot. In: Standing S, Borley NR, Healy JC, Collins P, Johnson D, Crossman AR, et al., editors. *Gray's Anatomy the Anatomical basis of clinical practice.* 40th ed. Spain: Churchill Livingstone Elsevier; 2008.p.1429-62.
3. Dogra SJ. Asymmetry in bone weight in human lower limb. *Journal Anatomy.* 1971;128:278-80.
4. Murlimanju BV, Prashanth KU, Prabhu LV, Saralaya VV, Pai MM, Rai R. Morphological and topographical anatomy of nutrient foramina in human upper limb long bones and their surgical importance. *Rom J Morphol Embryol.* 2011; 52(3):859-62.
5. Krischner J, Hennerbichler A, Gaber O, Hofman GO. Importance of arterial blood to the femur and tibia for transplantation of vascularized femoral diaphyses and knee joint. *World J Surg.* 1998; 22:845-52.
6. Collipal E. Diaphyseal nutrient foramina in the femur, tibia and fibula bones. *International Journal Morphologiacl.* 2007;25(2):305-8.
7. Kizilkanat E, Boyan N, Ozsahin ET, Soames R, Oguz O. Location, number and clinical significance of nutrient foramen in human long bones. *Ann Anat.* 2007;189(1):87-95.
8. Forrl CF, Gomez L, Gianonati M, Fernandez R. A study of nutrient foramina in human long bones. *Surg Radiol Anat.* 1987;9(3):251-55.
9. Srivastava R, Saini V, Rai RK, Pandey S, Tripathi SK. A study of sexual dimorphism in the femur among North Indians, *Journal of Forensic Sciences.* 2012;57(1):19-23.