

Myocardial Perfusion Imaging (MPI), An Overview

A Azam¹, WA Jahan², M Rahman², MA Kauser³, Noor F⁴

¹Department of Nuclear Cardiology, NICVD, ²Department of Radiology, NICVD, ³NCCRF&HD,

⁴Department of Pharmacology, Dhaka Dental College

Keywords:

Myocardial
Perfusion
Imaging (MPI).
Myocardial
viability,
Radiophar-
maceutical

Abstract:

The clinical utility of radiotracer study of heart in nuclear cardiology must always be considered in the context of other cardiac diagnostic procedures, including ECG, Echo, ETT, CAG and cardiac enzymes or serum cardiac protein. So one should not be a hop cardiologist.

Two modalities in Nuclear Cardiology:

1). Radionuclide Angiography (RNA) or Radionuclide Ventriculography.

2). Myocardial Perfusion Imaging (MPI).

Radionuclide Angiography (RNA) or Radionuclide Ventriculography: This procedure is designed to provide measurement of LVEF in patient of coronary artery disease, valvular heart disease or cardiomyopathy. In our setting we determine EF from MPI, so Radionuclide Angiography routinely not do in many centre of world including NICVD, Dhaka.

Myocardial Perfusion Imaging (MPI): MPI, more specifically myocardial perfusion single photon emission computed tomography (SPECT) is a nice tool for the noninvasive assessment of myocardial perfusion, ejection fraction, wall motion, and wall thickness.

Why not perform cardiac catheterization and coronary angiography in all patients suspected of having coronary artery diseases?

The contrast coronary angiogram displays the anatomic extent of epicardial coronary artery disease, the severity of luminal narrowing, and the number of diseased vessels. Stress radionuclide myocardial perfusion imaging, on the other hand, displays the downstream functional consequences of epicardial coronary artery disease in the myocardium. It also may visualize the regional effects of microvascular endothelial dysfunction and impairment of regional coronary flow reserve.

Application of MPI: The diagnosis of coronary artery disease remain common application of MPI, but it is increasingly being used for the diagnosis of acute MI, risk stratification after infarction, and assessment of viable myocardium versus scar in patients in chronic coronary artery disease.

(*Cardiovasc. j.* 2010; 3(1) : 55-65)

Introduction:

Over the past three decades myocardial perfusion single photon emission computed tomography (SPECT) has emerged as a robust tool for the noninvasive assessment of both myocardial perfusion and function. Since its inception in the 1970s, many advances have been made that have enhanced the diagnostic and prognostic strength of this modality, including development of new, technetium 99m (^{99m}Tc)-based Isotopes, implementation of SPECT, multidetector cameras, computerized quantification,

attenuation correction, and electrocardiographic (ECG) gating for the assessment of left ventricular (LV) function. These advances allow for very high diagnostic sensitivity and specificity. In addition, there is a wealth of data supporting the strength of this technique as a prognostic tool, not only in the general population, but also in many very important patient subgroups, such as women, patients with diabetes mellitus, in post revascularization patients, and as a preoperative assessment prior to noncardiac surgery.

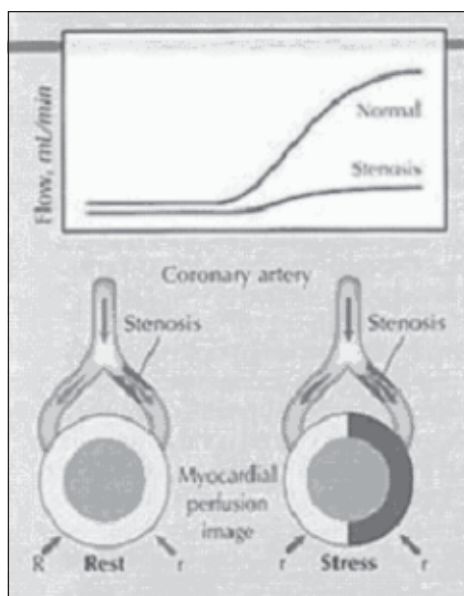


Fig-1: Pathophysiology underlying radionuclide myocardial perfusion imaging. Coronary blood flow in each of the coronary artery branches at rest and during stress is shown in graph. (From: *Atlas of Nuclear Cardiology*.)

Gating of MPI:

(i) Gating is a very simple way of making the MPI data synchronized with cardiac cycle, so that we get a MPI record in systole and diastole in discipline manner for easy interpretation.

(ii) Gating can be achieved by attaching gating monitor with patient through three limb leads. Virtually it is similar to synchronization during DC shock.

Methods:

Single photon emission computed tomography has emerged as the standard clinical method of performing nuclear cardiology studies. Compared with its predecessor, planar imaging, it improves image contrast and resolution. SPECT imaging is based on the theory that a three-dimensional image of the heart can be created from two-dimensional planar images acquired at 30 to 64 projections around the patient's chest over a 180° arc. Following data acquisition, the images are filtered and reconstructed. Finally the trans-axial images are reoriented into short axis images and the images are then displayed.

Initially, myocardial perfusion studies were performed using planar imaging. However, planar

imaging is hampered by the overlap of normal and abnormal myocardium as well as adjacent soft tissue, interfering with accurate localization and assessment of defect size and severity. Unlike planar imaging, SPECT is technically demanding and requires strict attention to quality control.

Gated SPECT myocardial perfusion imaging (MPI) was introduced in the early 1990s and has become a standard part of myocardial perfusion SPECT imaging. Around the same time came the development of multidetector gamma cameras. With the increasing use of dual-detector cameras (with heads mounted at 90°) cardiac studies could be acquired in half of the time required using a single-detector system, reducing patient discomfort and motion, as well as increasing laboratory throughput.¹

Radiopharmaceuticals

Thallium 201 (²⁰¹Tl) was the first clinically useful radio-isotope to assess regional myocardial blood flow. Its initial distribution is proportional to myocardial blood flow, thus imaging early (within the first hour) after its injection shows deficits in regions where blood flow is relatively reduced. Over time, ²⁰¹Tl undergoes redistribution as it attains concentration equilibrium between the extracellular and intra-cellular compartments. The redistribution of ²⁰¹Tl results in the "wash in" or normalization of its concentration in the initially underperfused regions. Generally, this can be demonstrated 3 to 4 hours after the injection of ²⁰¹Tl; however, in severely hypoperfused segments this may require imaging 24 to 48 hours later.

Currently there are two ^{99m}Tc-based radiopharmaceuticals approved for myocardial perfusion SPECT: ^{99m}Tc sestamibi and ^{99m}Tc tetrofosmin. The shorter half-life of ^{99m}Tc (6 hours) compared with ²⁰¹Tl (73 hours) allows the administration of a larger dose of the technetium agents: eight to 10 times that of ²⁰¹Tl. ^{99m}Tc also has the advantage of having a higher photopeak energy, resulting in improved counting statistics and less soft tissue attenuation, therefore offering enhanced image quality. There is good correlation of ²⁰¹Tl and ^{99m}Tc-based radiopharmaceuticals with myocardial blood flow over its normal physiologic range. However, there is an underestimation of flow at higher flow rates for

both of the ^{99m}Tc tracers. Further-more, ^{99m}Tc -based agents have clinically insignificant washout, thus requiring separate injections at rest and stress to assess blood flow under these two different physiologic states.

Positron imaging tracers currently used include oxygen 15 ($t_{1/2}$, 2 min), nitrogen 13 ($t_{1/2}$, 10 min), carbon 11 ($t_{1/2}$, 20 min), and fluorine 18 fluorodeoxyglucose (^{18}F FDG) ($t_{1/2}$, 110 min). These tracers require a cyclotron for production. Rubidium 82 ($t_{1/2}$, 5 sec) does not require a cyclotron and can be delivered directly by an on-site generator. Tracers used to assess myocardial perfusion are rubidium 82, nitrogen 13 ammonia, and oxygen 15 water. Metabolic tracers include ^{18}F FDG, carbon 11-labeled fatty acids, and carbon 11 acetate.

Acquisition Protocols

Several different protocols have been described using ^{201}Tl (especially for myocardial viability assessment), ^{99m}Tc -labeled agents, and both ^{201}Tl and ^{99m}Tc -labeled agents. At the present time, approximately 20% of myocardial perfusion SPECT studies are performed with ^{201}Tl alone, 40% with ^{99m}Tc -sestamibi alone, 20% with rest ^{201}Tl /stress ^{99m}Tc sestamibi, and 20% using ^{99m}Tc tetrofosmin either alone or in combination with ^{201}Tl .²

When ^{201}Tl is used alone, the most common acquisition protocol uses some combination of stress with redistribution and/or reinjection imaging. The latter involves obtaining an additional image in patients with nonreversible (fixed) perfusion defects following injection of 50% of the dose used at stress, with imaging performed 15 to 30 minutes thereafter.³ This protocol has been shown to improve the ability to detect viable myocardium over standard stress/4-hour redistribution imaging.⁴ An alternate protocol that is gaining popularity is to give sublingual nitroglycerin prior to reinjection with ^{201}Tl .⁵ From a practical standpoint, ^{201}Tl offers the advantage of use of a single injection of the isotope to demonstrate ischemia and to evaluate for hibernating but viable myocardium.⁶

Due to the absence of significant redistribution, separate rest and stress injections are standard with ^{99m}Tc -based isotopes. A variety of protocols can be used with this agent, including 2-day stress-

rest, same-day rest-stress, same-day stress-rest, and dual isotope. From the stand-point of defect contrast and optimal image quality, the 2-day imaging protocol is ideal. The principal drawback of this protocol is its requirement of two imaging days. Although, the same-day low-dose rest/high-dose stress is the most commonly employed ^{99m}Tc -based protocol, it has the disadvantage of potentially causing a reduction in stress defect contrast (< 15%) because some of the radio-activity observed on stress images comes from the activity from the resting myocardial perfusion study (performed only hours before).⁷ Of note, recent work has shown this to be of minor clinical significance, and with proper dosing of the rest and stress images there is excellent identification of ischemic defects. The same-day low-dose stress/high-dose rest sequence has less than ideal counts rate for the stress image set, and making it difficult to accurately assess defect reversibility.^{8,9}

Regarding the assessment of myocardial viability, all stress/rest or rest/stress ^{99m}Tc -based isotopes have limitations in separating severely hibernating myocardium from infarction. Based on the limitations of ^{99m}Tc -based isotope protocols, a rest ^{201}Tl and/stress ^{99m}Tc -based isotope dual-isotope SPECT protocol has gained wide popularity. The sensitivity and specificity of these protocols have been shown to be approximately 90%.^{10,11}

Stress Modalities

Treadmill and bicycle exercise are the most common types of stress used in conjunction with MPI. In general, the performance of myocardial perfusion SPECT with exercise stress is preferable for prognostic purposes. Important prognostic variables associated with exercise ECG testing include exercise capacity,^{12,13} exercise-inducible chest pain, hypotension, and the ECG response to exercise. These variables cannot be assessed with pharmacologic stress testing. However, a significant number of patients are unable to adequately exercise. In these patients, pharmacologic stress testing is an effective substitute for exercise in conjunction with MPI.

Adenosine and dipyridamole are coronary vasodilators that increase myocardial blood flow four- to fivefold in myocardial region that are supplied by normal coronary arteries. In contrast,

there is an attenuated hyperemic response in myocardial regions supplied by diseased coronary arteries.^{14,15} Thus, regional flow heterogeneity, which usually occurs without ischemia, produces the reversible perfusion defect on the myocardial perfusion SPECT studies. Adenosine is a direct coronary vasodilator and activates the adenosine A₂ receptors in the coronary arterial wall, leading to coronary vasodilatation. Dipyridamole exerts its effect by raising endogenous adenosine levels by blocking of the cellular reuptake of adenosine.

The clinical indications for adenosine/dipyridamole are inability to exercise (*eg*, stroke, arthritis, peripheral vascular disease, disabling diseases, amputation); inability to achieve at least 85% of maximum predicted heart rate (*eg*, chronotropic incompetence, β -blocker); left bundle branch block (LBBB), ventricular-paced rhythm, and early post-myocardial infarction (MI) or unstable angina patients. There are several contraindications to the use of pharmacologic stress with adenosine and dipyridamole: asthma, active bronchospasm, severe chronic obstructive pulmonary disease with home O₂, advanced atrioventricular block, sick sinus syndrome, sinus bradycardia (< 40 beats/min), hypotension (systolic blood pressure < 90 mm Hg), fewer than 2 days post-MI, and recent use (< 24 hours) of theophylline or caffeine.

A modification to the adenosine protocol, using low-level exercise, has recently gained much acceptance. Adding a low-level treadmill exercise to the adenosine infusion results in decreased side effects, decreased symptomatic hypotension and bradycardia, and an increased target to background ratio, allowing for immediate imaging, as would be done with exercise.¹⁶ This protocol can also be applied to dipyridamole. It should be noted that one should not add low-level exercise to patients with LBBB or ventricular-paced rhythm, as they are susceptible to the same false positive findings in the interventricular septum as would be seen with exercise.

The performance of myocardial perfusion SPECT with pharmacologic stress, either dipyridamole or adenosine, has essentially the same sensitivity and specificity for detecting coronary artery disease (CAD) and incremental prognostic value for predicting cardiac death and MI as does exercise myocardial perfusion scintigraphy.^{17,18}

Myocardial perfusion scintigraphy can be also performed with dobutamine stress, but is generally reserved for patients who either cannot adequately exercise or have a contraindication to vasodilator stress. Briefly, dobutamine is a synthetic catecholamine that directly stimulates both β_1 and β_2 receptors that increased heart rate and myocardial contractility in a dose-related fashion. Thus, dobutamine increases coronary blood flow by increasing myocardial oxygen demand, and the myocardial perfusion abnormalities are induced by the development of regional myocardial ischemia.¹⁹⁻²¹

Image acquisition and processing

SPECT imaging camera had configuration. With SPECT, a series of planar images are obtained in an orbit around the patient. The images can be obtained over a full orbit of 360 degrees or over half of that (180 degrees). The asymmetric position of the heart in the thorax means that 180-degree orbits can suffice in most clinical instances. However, a 180-degree orbit may sometimes result in artifacts. With the use of multi head detectors, data are acquired at various projections of the heart simultaneously, thereby shortening the time of image acquisition of improving image count density. Imaging with dual- and triple-head detectors can be completed in half or one third of the time taken by a single-head detector. With dual-head cameras, the detectors can be arranged parallel to each other or at right angles to each other. The latter configuration is preferable if simultaneous attenuation correction is applied.

Myocardial perfusion single photon emission computed tomography (SPECT) is a widely utilized noninvasive imaging modality for the diagnosis, prognosis, and risk stratification of coronary artery disease. It is clearly superior to the traditional planar technique in terms of imaging contrast and consequent diagnostic and prognostic yield. The strength of SPECT images is largely derived from the three-dimensional, volumetric nature of its image. Thus, this modality permits three-dimensional assessment and quantitation of the perfused myocardium and functional assessment through electrocardiographic gating of the perfusion images.

Processing of images or Re-slicing or Oblique reorientation or Filtering of SPECT images

MPI images are viewed in standard format, consisting of short-axis, horizontal long axis, and vertical long axis slices. Generation of these standard sections from the original trans-axial images is done through automatic processing, by locating LV axis in processing computer, thereby LV isolation, reconstruction, and reorientation can be achieved.

The acquired row images are somewhat noisy, and so filtering is required to eliminate or reduce the noise. There are several ways of filtering out the noise. The most common way is by Fourier transformation of the row images, in which the row image data are transformed into a series of frequencies. The relevant data are present in the low- frequency range, whereas noise is present in the high- frequency range.

- A. low pass filter allows the low frequencies to be retained unaltered and eliminates completely the high frequencies the above the cut- off range. The frequencies in the intermediate range are altered by a function depicted by the slope of the cut- off curve. If too much filtering is used, even the useful data may be lost. T
- B. he high- pass filter retains the high frequencies and eliminates the low frequencies. This filter is used primarily for edge enhancement.
- C. A patient example in which low- pass filter (Butterworth filter) is applied to transaxial images of the heart is shown. The unfiltered images (top) are of poor quality and very noisy. The background noise is eliminated in the properly filtered images (center). However, over filtering results in distortion of the myocardial contour (bottom).

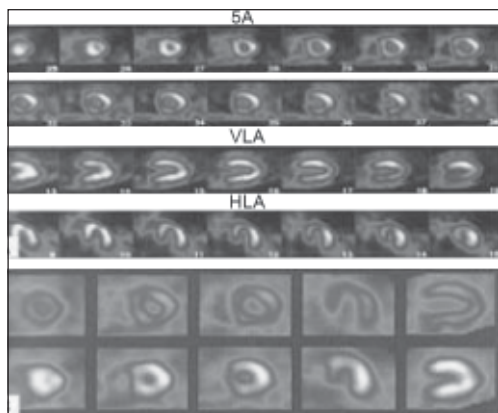


Fig.-2: Normal gated SPECT image.

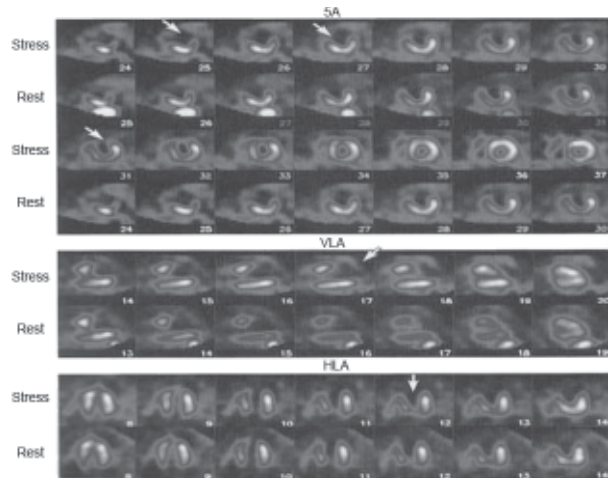
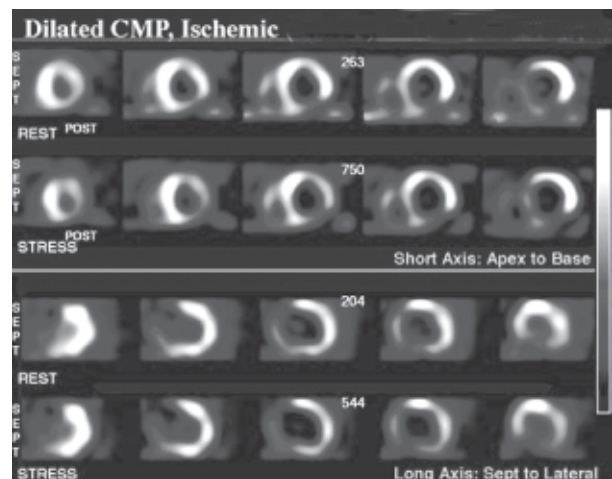
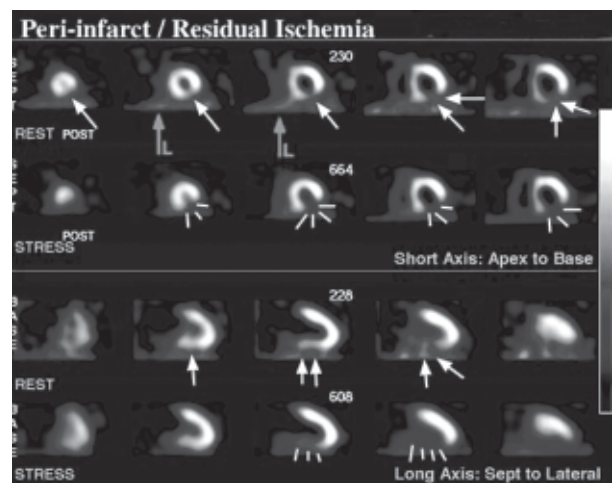


Figure: Anterior & apical fixed (irreversible) MPI result.



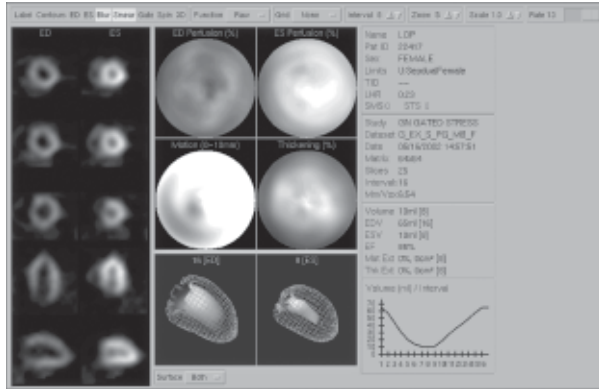


Image analysis:

-Visual examination of circumferential profile.

- By circumferential analysis program, in which the counts in each sector of the left ventricular myocardium are compared stress and rest images.

Image Interpretation:

After final processing of acquired images, they should be displayed in short axis from apex to base, vertical long axis and horizontal long axis in parallel row of rest and stress images. A number of approaches to quantitative analysis are being applied to gated SPECT study, such as:

- a) Visual comparison of immediate post stress studies and the resting immediate images to characterized perfusion defect as normal, reversible perfusion defect or fixed (irreversible) defect. After initial assessment of the presence or absence of defects, a complete evaluation of the MPI result includes assessment of size, location, severity, and likely vascular distribution of the visualized abnormalities. In deciding whether a given abnormality is a true perfusion defect the interpreter's confidence goes up if defect is seen on more than one view. In addition to the location, severity, and size of perfusion abnormalities other abnormalities should be assessed, such as stress induced dilatation of LV cavity is readily detected by comparing the images immediately after exercise with the delayed rest images. Dilatation is a secondary indication of ventricular dysfunction and indicates significant CAD. It is referred to as transient ischemic dilatation.
- b) Measures of regional perfusion at end-diastole and end-systole and estimates of wall thickening

are calculated from regions of interest placed systematically around the myocardium. Estimate of ejection fraction (EF) can be obtained by measuring the size of the LV cavity through a cardiac cycle.

- c) In another approach a polar map is created from the short axis SPECT images. The circumferential profiles are presented in 2-dimensional "Bull eye" display. The circumferential profiles obtained from the short SPECT views, starting at the apex.
- d) Quantitative analysis of gated SPECT myocardial perfusion imaging has been extended to 3-dimensional reconstructions of the data.

Both semi quantitative and quantitative systems are used for the interpretation of myocardial perfusion SPECT. These methods assess the extent and the severity of myo-cardial perfusion defects; the extent is related to the amount of myocardium involved, whereas the severity is the degree of perfusion abnormality.

The use of a semi quantitative scoring system in which 17 segments are scored according to a five-point scheme provides an approach to interpretation more systematic and reproducible than simple qualitative evaluation.²² Each segment is scored from 0 (normal perfusion) to 4 (absence of radioactive uptake).

In addition to reviewing LV perfusion, the complete interpretation of MPI should include consideration of the lung uptake, LV size, transient ischemic dilatation, and right ventricular size and perfusion.²³

Cardiovascular nuclear medicine techniques are inherently quantitative. Assessment of cardiac performance is markedly enhanced by a quantitative description of the specific physiologic parameters evaluated by scintigraphic images. Quantification enables objective comparison and assessment of cardiac status in a single patient over time or as result of intervention. The clinical utility of the quantitative analysis of myocardial perfusion SPECT is as a second expert opinion for an experienced observer, a teaching tool for a less experienced observer, and an accurate, reproducible assessment of the extent, severity, and reversibility of hypoperfusion, with a potential

use in risk stratification useful for evaluating interval changes in myocardial perfusion.

Clinical Applications

The principal applications of gated MPI are related to its superior diagnostic and prognostic performance. Gated MPI is used as a diagnostic tool in the evaluation patients with suspected CAD who have a pretest intermediate to high risk of CAD. The clinical incremental prognostic value of MPI in patients with no known history of CAD has been demonstrated with both ^{201}Tl and $^{99\text{m}}\text{Tc}$ sestamibi whether the patient undergoes a standard treadmill stress test or a pharmacologic stress test (similar data are currently lacking for $^{99\text{m}}\text{Tc}$ tetrofosmin).

Myocardial perfusion imaging is also gaining a role in the emergent setting as a tool to diagnose acute MI when the clinical assessment and other laboratory testing, including the ECG and cardiac enzymes, are normal or inconclusive. In this setting, a normal MPI in patients injected with a $^{99\text{m}}\text{Tc}$ isotope during or shortly after the spontaneous resolution of symptoms indicates a very low likelihood of an acute unstable coronary syndrome. In fact, a recent review demonstrated that a normal MPI in this setting had a 99% negative predictive value.

The remaining indications for MPI relate to its prognostic abilities. Risk assessment is based on the ability to identify patients who are at risk of cardiac death, which exceeds the risk of death from an intervention. Thus, identification of those patients who are at a higher risk of cardiac death allows for the appropriate utilization of revascularization procedures. MPI can also be used to identify patients with ischemia but who are at a low risk of cardiac death. Conventional wisdom is that these patients would be better served by medical management of their disease versus undergoing the riskier treatment of revascularization. MPI has been shown to be a potent prognostic tool for both men and women, diabetic patients, the elderly, after revascularization, after MI, and as part of a preoperative assessment prior to non-cardiac surgery.

Risk Stratification and Patient Management

MPI for risk stratification after myocardial infarction: Another important application of stress

MPI is in the management and risk stratification of patients after AMI. In some medical centers post-MI are routinely studied before hospital discharge. In major situation pharmacological stress perfusion are done within 3 months after AMI but treadmill stress MPI can perform 3 months after AMI and in old MI. Decision for further treatment should be taken in following order:

- I. If post infarction MPI result shows single fixed defect or no defect and no ECG evidence of after adequate exercise, that patient/s can treat conservatively with conventional medical therapy.
- II. If the post infarction MPI study demonstrates a reversible perfusion defect contiguous to the site of infarction (fixed defect), indicates residual ischemia consider for further work up with CAG and revascularization.
- III. If the post infarction MPI study demonstrates a reversible perfusion defect contiguous to the site of infarction (fixed defect), and a reversible or fixed defect remote from the infarct, residual ischemia and multivessels disease is highly likely. Patients with these findings are at much greater risk for subsequent cardiac events and death and warrant more aggressive management with PCI or CABG.
- IV. Post infarction MPI study and prognosis after myocardial infarction: The long term prognosis of patients after MI has been a subject of intense interest clinically. Traditional evaluation has included assessment Killip classification, location of infarction, presence of congestive heart failure, H/O prior infarction, and LVEF. The size of the defect as demonstrated by MPI is now well established as a predictor of patient outcome. This confirms the links that would be expected between infarct size, left ventricular function, and long term prognosis.

The most rapidly growing area of application of myocardial perfusion SPECT is risk stratification based on increased acceptance of a new paradigm in patient management. What is optimal risk stratification? Based on published guidelines and expert consensus, there are two requirements for optimal risk stratification by a non-invasive test.

First/ a negative study should be associated with a very low risk of adverse outcomes, as measured by the observed event rate in the population with normal studies. The event rate should be less than 1%. To this end, a pooled analysis of 20,963 patients, from 16 studies/ with a normal myocardial perfusion had an event rate (death and MI) of 0.7% per year. Second, the event rate associated with an abnormal scan should not only be greater than that associated with a normal scan, but the relative risk and its associated confidence interval with an abnormal scan relative to a normal scan should be greater than 1. Finally, the majority of the events (> 80%-90%) should occur in those patients with an abnormal study. MPS has been shown to enhance risk stratification in a population already stratified by pronuclear testing data, including stratification by clinical data, exercise treadmill testing (ETT) data, and clinical plus ETT data. In all case MPS enhanced risk stratification with respect to risk of cardiac death or nonfatal infarction.²⁴

In a series of 5183 patients undergoing myocardial perfusion SPECT, Hachamovitch *et al*²⁵ examined risk stratification with regard to the risks of cardiac death and nonfatal MI. Although significant increases in cardiac death and MI occurred as a function of worsening scan results, patients with mildly abnormal myocardial perfusion SPECT were at intermediate risk of MI (2.7% per year) but at low risk of cardiac death (0.8%). This suggests that a mildly abnormal myocardial perfusion study may identify patients with significant CAD that can be treated with medical management and aggressive risk factor modification. On the other hand, a patient with a more severely abnormal myocardial perfusion study is at high risk of MI (2.9% per year) and cardiac death (4.2% per year). Thus, these patients should be considered for catheterization with consideration of revascularization.

Assessment of result and patency after CABG or PCI by follow up MPI test:

Follow-up stress MPI after CABG or PCI provide an objective assessment of therapeutic effect on the coronary circulation. Successful surgery or angioplasty result in elimination of reversible defects caused by exercise induced ischemia. CABG and PCI have no effect on scarred areas, and fixed defect should appear unchanged.

If a patient has an infarction as a result of the therapeutic intervention, a previously reversible defect may be converted into a fixed defect or an entirely new defect may occur as a result of the injury. Imaging should be delayed 6 weeks or more because some preintervention defects may persist if the scan is done too soon.

When symptoms recur, as they do in a significant percentage of patients, the early post therapy study serves as a useful baseline. The development of new or recurrent disease is readily detected on repeat stress imaging.

Assessment of thrombolytic therapy by MPI:

In patients undergoing thrombolysis, myocardial perfusion studies are performed under resting condition. After recovery, stress imaging is useful to determine outcome and detect any areas of residual exercise or stress induced ischemia.

An initial dose of Tc^{99m} tetrofosmin may be given the time of patient arrives at the hospital, but imaging can be delayed until the patient is stabilized or even until after thrombolytic therapy is given. The initial dose is then used to document the amount of myocardium at risk. A second dose is then used to determine the effectiveness of therapy. Reduction in defect size correlates with vessel patency and better prognosis after MI.

Gated Myocardial Perfusion Single Photon Emission Computed Tomography

With the advent of ECC-gated myocardial perfusion SPECT, LV function is now routinely assessed in patients undergoing stress perfusion imaging. A gated study is acquired by temporally organizing the image data acquired from the patient. Specifically, the R-R interval is divided into equal frames, typically eight or 16, and image data are binned according to the frame in which they were acquired. The data are then processed and can be displayed in cinematic format.

The gated portion of a myocardial perfusion SPECT is acquired simultaneously with the acquisition of perfusion. In addition to allowing for the visual assessment of LV function, gated SPECT' allows for the evaluation of LV wall motion and thickening.

Furthermore, quantitative methods have been developed to automatically measure LV ejection

fraction (LVEF) and volumes. The most recent versions of the systems use a three-dimensional approach to map the endocardial and epicardial surfaces.^{26,27} These methods have been shown to be both accurate and precise. Accuracy has been assessed by comparing the results of gated SPECT with first-pass left ventriculography, two-dimensional echo-cardiography, magnetic resonance imaging, thermodilution, contrast ventriculography, and electron beam CT, using a variety of different radiopharmaceuticals. The Pearson r-value for LVEF and volume ranges from 0.7 to 0.99.^{26,28} Precision has been assessed by repeating the measurement of LV function over time with very strong correlation (r-values range from 0.86-0.98).²⁹⁻³¹

In addition to validity of the measurements, quantitative gated SPECT is an objective process; in general, the LV surfaces are automatically defined without guidance from the operator. Figure 2 is an example of one such approach, from the Quantitative Gated SPECT program (General Electric Medical Systems, Waukesha, WI).

The addition of functional information to myocardial perfusion SPECT adds clinical value in diagnosis, risk stratification as well as the assessment of myocardial viability. From a diagnostic perspective, gated SPECT has proven most useful in differentiating infarction from artifact. Specifically, when there is a defect on both rest and stress perfusion, the presence of normal LV wall motion and thickening would be indicative of this defect being an artifact (as infarcted myocardium would not have normal wall motion and thickening). This results in fewer false-positive studies and higher overall test specificity without comprising the sensitivity of the study. This was shown very nicely by Taillefer *et al*³² who found that the specificity for detecting significant coronary artery stenosis was 68% for ²⁰¹Tl SPECT and 92% with ^{99m}Tc sestamibi-gated SPECT (P = 0.0004), whereas the sensitivity was 84% for ²⁰¹Tl and 80% for ^{99m}Tc-sestamibi.

In addition, evaluation of post-stress-gated SPECT can offer insight into the severity of coronary artery stenosis in patients with stress-induced ischemia. It has been shown that the development of new wall motion abnormalities on post-stress-gated SPECT (either not present on a rest-gated SPECT

or in a region of normal resting perfusion, with presumed normal function) is indicative of severe (> 90%) stenosis in the artery subtending the ischemic myocardium; this phenomenon is due to persistent post-stress stunning. Furthermore, Sharireta³³ have shown such that new wall motion abnormalities on post-stress-gated SPECT are a better predictor of the severity of coronary artery stenosis than the severity of the stress-induced perfusion defect.

Gated SPECT can also offer insight as to the etiology of a patient's LV dysfunction. Specifically, the combination of perfusion and function can broadly differentiate ischemic from non ischemic cardiomyopathy. Thus, patients with normal perfusion and reduced LV systolic function can be recognized as having a non ischemic cardiomyopathy and be worked up accordingly, whereas those with significant perfusion abnormalities and LV systolic dysfunction can be categorized as having an ischemic cardiomyopathy. Moreover, patients with relatively small perfusion abnormalities with disproportionate LV systolic dysfunction can be categorized as having a mixed cardiomyopathy. Finally, in patients with clinical congestive heart failure who have normal perfusion and normal LV systolic function by gated myocardial perfusion SPECT, the diagnosis of diastolic dysfunction should be considered.

From a prognostic standpoint, it has long been established that LV systolic function is a potent tool for assessing the likelihood of cardiac mortality. This has been best demonstrated in the post-MI patient group. The Thrombolysis In Myocardial Infarction II³⁴ and Mullicenter Post Myocardial Infarction Research Group³⁵ studies have both shown that LV systolic function is a very important prognostic index and that mortality is inversely related to LVEF.

Similar findings have been made for LVEF obtained by gated SPECT. A recent study examining the outcomes of 2686 patients undergoing myocardial perfusion-gated SPECT, found that LVEF by post-stress-gated SPECT was the best predictor of cardiac death, even after adjusting for perfusion.³⁶ Furthermore, they showed the same inverse, exponential relationship between EF and mortality.

Gated SPECT has also been evaluated as a tool for assessing myocardial viability; in this application the combination of perfusion and LV function is used to assess the viability. There have been several reports utilizing this technique for assessing myocardial viability with conflicting results. Two of these studies have shown that this technique underestimates the extent of myocardial viability compared with rest/redistribution ^{201}Tl SPECT.^{37,38} However, there have been three studies that have demonstrated equivalent results for gated $^{99\text{m}}\text{Tc}$ and rest/redistribution ^{201}Tl SPECT.^{39,40} Most recently, Duncan *et al.*⁴⁰ evaluated 30 patients scheduled to undergo coronary artery bypass surgery with pre- and post revascularization-gated $^{99\text{m}}\text{Tc}$ and rest/redistribution ^{201}Tl SPECT. They found no difference in the sensitivity, specificity positive or negative predictive value, or predictive accuracy for the detection of viability between these two methods.

Conclusions:

Over the past two decades gated myocardial perfusion SPECT has developed into a widely accepted noninvasive tool for evaluating patients with known or suspected coronary artery disease. It offers superior diagnostic accuracy in virtually all patient populations. In addition, there is vast literature supporting its ability to risk stratify patients into low- and high-risk groups. Furthermore, recent data support a prognostic approach to the management of patients with coronary artery disease based on the results of gated myocardial perfusion SPECT imaging. The assessment of LV function adds further to the diagnostic and prognostic significance of this imaging modality. The future development of enhancements, such as attenuation correction, stand to further foster the clinical utility of gated myocardial perfusion SPECT.⁴¹

References:

- Garcia HV, Nichols K, Gaitj, *et al.*: Instrumentation, quality assurance and performance. In imaging guidelines for nuclear cardiology procedures, part 1. *J Nucl Cardiol* 1996; 3:G5-G10.
- Berman DS, Germano G: Myocardial single photon approaches in *Imaging in Cardiovascular Disease*, Edited by Pohost GE. Philadelphia: Lippincott Williams & Wilkins; 2002: 159-194.
- Dilsizian V, Rocco TP, Freedman NM, *et al.*: Enhanced detection of ischemic but viable myocardium by the reinjection of thallium after stress-redistribution imaging. *N Engl J Med* 1990; 323:141-146.
- Dilsizian V, Smeltzer WR, Freedman NM, *et al.*: Thallium reinjection after stress-redistribution imaging. Does 24-hour delayed imaging after reinjection enhance detection of viable myocardium? *Circulation* 1991; 83:1247-1255.
- Ba.su S, senior R, Raval U, *et al.*: Superiority of nitrate-enhanced ^{201}Tl over conventional redistribution ^{201}Tl imaging for prognostic evaluation after myocardial infarction and thrombolysis. *Circulation* 1997; 96:2932-2937.
- Ragosta M, Beller GA: The noninvasive assessment of myocardial viability. *Clin Cardiol* 1993; 16:531-538.
- N Berman DS, Hayes SW, Gernano G: In *Cardiac Spect Imagmg*. Edited by De Puey EG, Garcia EV, Berman DS. Philadelphia: / Lippincott Williams & Wilkins; 2000:179-210.
- Heo J, Keget J, Iskandrian AS, *et al.*: Comparison of same-day protocol using technetium-99-m-sestambi myocardial imaging, *J Nucl Med* 1992;33:186-191.
- Taillefer R, Gagnon A Laflamrne L, *et al.*: Same day injections of Tc-99-m-methoxy isobutyl isonitrile (hexamibi) for myocardial tomographic imaging: comparison between rest-stress and stress-rest injection sequences. *Bur J Nucl Med* 1989; 15:113-117.
- Bernnan DS, Kiat H, Friedman JD, *et al.*: Separate acquisition of rest thallium-201/ stress technetium-99-m-sestambi dual-isotope myocardial single photon emission computed tomography: a clinical validation study. *J Am Coll Cardiol* 1993; 22:1455-1464.
- Kiat H, Gernano G, Friedman JD, *et al.*: Comparative feasibility of separate or simultaneous rest thallium-201/stress technetium-99-m-sestambi dual-isotope myocardial SPECT. *J Nucl Med* 1994; 35:542-548.
- Weiner DA, Me Cabe CH, Ryan TJ: Prognostic assessment of patients with coronary artery disease by exercise testing. *Am Heart J* 1983; 105:749-755.
- Mc Neer F, Margolis JR, Lee KL, *et al.*: the role of exercise test-ing in the evaluation of patients for ischemic heart disease. *Circulation* 1978; 57:64-70.
- Gould LK, Westcott R, Albro P, *et al.*: Noninvasive assessment of coronary artery stenosis by myocardial imaging during pharmacologic coronary vasodilation. II. Clinical methodology and feasibility. *Am J Cardiol* 1978; 41:279.
- ChanSY, Brunken RC, Czernin J, *et al.*: Comparison of myocardial blood flow during adenosine infusion with that of intravenous dipyridamole in normal men. *J Am Coll Cardiol* 1992;20:979-985.
- Thomas GS, Prill NV, Majmundar H, *et al.*: Treadmill exercise during adenosine infusion is safe, results in fewer adverse reactions, and improves myocardial perfusion image quality. *J Nucl Cardiol* 2000; 7:439-446.
- Gupta NC, Esterbrooks DJ, Hilleman DE, *et al.*: Comparison of adenosine and exercise thallium-201 single-photon emission computed tomography (SPECT) myocardial perfusion imaging. *J Am Coll Cardiol* 1992; 19:265-275.
- I lachamovitch R, Berrnan DS, Kiat H, *et al.*: incremental prognostic value of adenosine stress myocardial perfusion single photon emission computed tomography and impact on subsequent management

- in patients with or suspected of having myocardial ischemia. *J Am Coll Cardiol* 1997; 80:426-433.
19. Hays JT, Mahmorian JJ, Cochran AJ, *et al.*: Dobutamine thallium-201 tomography for evaluating patients with suspected coronary artery disease unable to undergo exercise or pharmacological stress testing. *J Am Coll Cardiol* 1993; 21:1583-1590.
 20. Kiat H, Iskandrian AS, ViJlegas BJ, *et al.*: Arbutamine stress thallium-201 single photon emission computed tomography using a computerized closed-loop delivery system: multi-center trial for evaluation of safety and diagnostic accuracy. *J Am Coll Cardiol* 1995; 26:1159-1167.
 21. Geleijnse ML, Elhendy A, Fioretti PM, Roelandt JR: Dobutamine stress myocardial perfusion imaging. *J Am Coll Cardiol* 2000;
 22. Cerqueira MD, Weissman NJ, Dilsizian V, *et al.*: Standardized myocardial segmentation and nomenclature for tomographic imaging of the heart: a statement for healthcare professionals from the Cardiac Imaging Committee of the Council on Clinical Cardiology of the American Heart Association. *J Nucl Cardiol* 2002; 9:240-245.
 23. Van Train, Garcia EV, Cooke DC, Arreda JS: Quantitative analysis of SPECT myocardial perfusion. In: *Cardiac SPECT Imaging*. Edited by De Puey EG, Garcia EV, Herman DS. Philadelphia: Lippincott Williams & Wilkins; 2000:41-64.
 24. Berman DS, Hachamovitch R, Kiat H, *et al.* : Incremental value of prognostic testing in patients with known or suspected ischemic heart disease: a basis for optimal utilization of exercise technetium-99m sestamibi myocardial perfusion single-photon emission computed tomography. *J Am Coll Cardiol* 1995; 26:639-647.
 25. Hachamovitch R, Herman DS, Shaw LJ, *et al.*: Incremental prognostic value of myocardial perfusion photon emission computed tomography for the prediction of cardiac death: differential stratification for risk of cardiac death and myocardial infarction. *Circulation* 1998, 97:535-543.
 26. Germano G, Kiat H, Kavanagh PB, *et al.*: Automatic quantification of ejection fraction from gated myocardial perfusion SPECT. *J Nucl Med* 1994; 35:1185-1192.
 27. Farber T, Cooke C, Folks R, *et al.*: Left ventricular function and perfusion from gated SPECT perfusion images: an integrated method. *J Nucl Med* 1999; 40:650-659.
 28. Vaduganathan P, He Z, Vick, *et al.*: Evaluation of left ventricular wall motion, volumes, and ejection fraction by gated myocardial tomography with technetium 99m-labeled tetrofosmin: a comparison with cine magnetic resonance imaging. *J Nucl Cardiol* 1999; 6:3-10.
 29. Johnson LL, Verdesca SA, Aude WY, *et al.*: Postischemic stunning can affect left ventricular ejection fraction and regional wall motion on post-stress gated technetium-99m-sestamibi SPECT. *J Am Coll Cardiol* 1997; 30:1641-1648.
 30. Berman D, Germano G, Lewin H, *et al.*: Comparison of post-stress ejection fraction and relative left ventricular volumes by automatic analysis of gated myocardial perfusion SPECT acquired in the supine and prone positions. *J Nucl Cardiol* .1998; 5:40-47.
 31. Lewin HC, Herman DS, Hayes SW, *et al.*: Clinical reproducibility of post-stress gated myocardial perfusion SPECT imaging. *J Nucl Med* 2000; 41:160P.
 32. Taillefer R, DePuey EG, Udelson E, *et al.*: Comparative diagnostic accuracy of Tl201 and 99mTc-sestamibi SPECT imaging (perfusion and ECG-gated SPECT) in detecting coronary artery disease in women. *J Am Coll Cardiol* 1997; 29:69-77.
 33. Sharir T, Bacher-Stier C, Dhar S, *et al.*: Identification of severe and extensive coronary artery disease by postexercise regional wall motion abnormalities in Tc-99m sestamibi gated single-photon emission computed tomography. *Am J Cardiol* 2000; 86:1171-1175.
 34. Zaret B, Wackers F, Terrin M, *et al.*: Value of radionuclide rest and exercise left ventricular ejection fraction to access survival of patients following thrombolytic therapy for acute myocardial infarction: results of the Thrombolysis in Myocardial Infarction (TIMI) phase II study. *J Am Coll Cardiol* 1995; 26:73.
 35. The Multicenter Post Myocardial Infarction Research Group: Risk stratification and survival after myocardial infarction. *N Engl J Med* 1983; 309:331.
 36. Sharir T, Germano G, Kavanagh PB, *et al.*: Incremental prognostic value of post-stress left ventricular ejection fraction and volume by gated myocardial perfusion single photon emission computed tomography. *Circulation* 1999; 100: 1035-1042.
 37. Cuocolo A, Pace L, Ricciardelli B, *et al.*: Identification of viable myocardium in patients with chronic coronary artery disease: comparison of Tl201 scintigraphy with reinjection and technetium-99m-methoxyisobutyl isonitrile. *J Nucl Med* 1992; 33:505-511.
 38. Marzullo P, Sambucetti G, Parodi O: The role of sestamibi scintigraphy in the radioisotopic assessment of myocardial viability. *J Nucl Med* 1992; 33:1925-1930.
 39. Udelson JE, Coleman JH, Metherall J, *et al.*: Predicting recovery of severe regional ventricular dysfunction: comparison of resting scintigraphy with Tl201 and 99mTc sestamibi. *Circulation* 1994; 89:2552-2561.
 40. Kauffman GJ, Boyne TS, Watson DD, *et al.*: Comparison of rest Tl201 imaging and rest Tc99m-sestamibi imaging for assessment of myocardial viability in patients with coronary artery disease and severe left ventricular dysfunction. *J Am Coll Cardiol* 1996; 27:1592-1597.
 41. Abdullah Al Shafi Majumder. Nuclear Cardiology: a promising technology. Editorial. *Journal of Dhaka Medical College*. April 1995 Number-1. Vol.4. Page:III-IV.