

## Case Report

# David Procedure for Valve-Sparing Aortic Root Replacement in a Marfan Syndrome Patient

Saikat Das Gupta<sup>1</sup>, Sharif Hasan<sup>2</sup>, Sarmistha Biswas<sup>3</sup>, Tanvir Ahmed<sup>1</sup>, Mozibul Haque<sup>2</sup>, PK Chanda<sup>1</sup>

<sup>1</sup>Department of Cardiac Surgery, Square Hospitals Limited, Dhaka, <sup>2</sup>Department of Cardiac Anesthesia, Square Hospitals Limited, Dhaka, <sup>3</sup>Department of Cardiology, Square Hospitals Limited, Dhaka

### Abstract:

**Key Words :**  
Aortic valve,  
aortic aneurysm,  
David procedure

*Valve-sparing aortic root replacement (VSRR) is an established treatment method for aortic root dilatation and aortic valve insufficiency (AI). It was developed to restore the aortic valve functions in patients of aortic root aneurysms with morphologically normal aortic valve. We hereby present a case of 67 years, male, with aortic root aneurysm and severe aortic regurgitation who was treated successfully by David's procedure for valve sparing aortic root replacement technique.*

*(Cardiovasc j 2022; 14(2): 185-190)*

### Introduction:

Among all the patients undergoing aortic root replacement, approximately 30% have a morphologically normal or only mildly diseased aortic valve.<sup>1</sup> The use of composite valve grafts containing a mechanical valve will necessitate long-term anticoagulation therapy with associated risks of thromboembolic and hemorrhagic complications.<sup>2</sup> Sir Magdi Yacoub, in the late 1970s, introduced a “remodeling” operation that preserves the native aortic valve but does not protect the aortic annulus from dilatation.<sup>3</sup> Later, Dr. Tirone David introduced the “re-implantation” technique where an adequately sized Dacron graft is anastomosed below the aortic annulus, protecting both the valve leaflets and the annulus.<sup>4-6</sup> This surgical approach of the VSRR technique by Yacoub (remodeling) and David (re-implantation) has gained wide acceptance as an alternative to composite graft replacement after its introduction. This important difference makes the re-implantation operation long-lasting by preventing aortic insufficiency caused by annular dilation or primary valve leaflet dysfunction. For patients with connective tissue disorders, the re-implantation procedure is more suitable than the remodeling

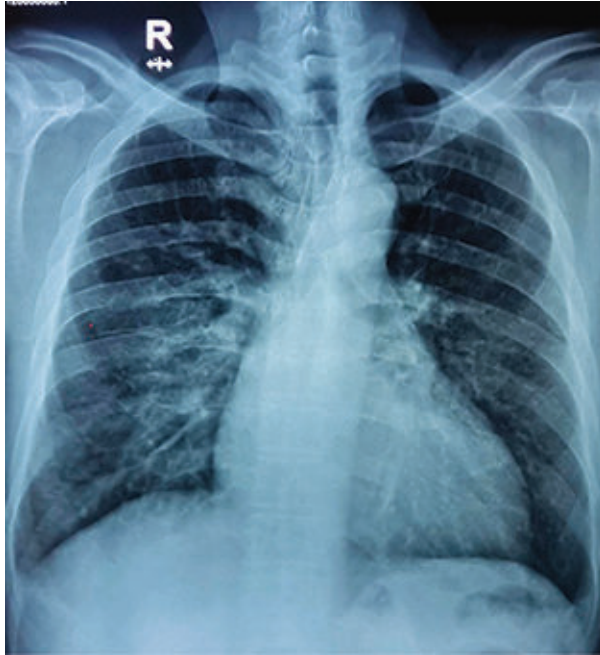
procedure because the aortic valve annulus is more prone to dilate in these patients. Dr. David's excellent study supports this, in which a high proportion of patients (38%) were of Marfan syndrome.<sup>6</sup> Consequently, Dr. David's technique has evolved over the last couple of decades in the hands of the inventor himself, and many others have made modifications too.<sup>7</sup> We hereby present a case of a male, senior citizen (67 Years), having severe aortic regurgitation with aortic root aneurysm, who was treated successfully by David's procedure of valve sparing aortic root replacement technique.

### Case Report:

Mr. X, 67 years of age, hypertensive, a non-diabetic gentleman got admitted to Square Hospitals Ltd as a known patient of the aortic root and ascending aortic aneurysm with severe aortic regurgitation (AR). He had complaints of exertional chest discomfort and breathlessness for the last one year. The discomfort and breathlessness were not relieved by rest, postural change, or drugs. The patient has no history of Chronic Kidney Disease, Cerebrovascular Disease, Chronic Obstructive Pulmonary Disease, Bronchial Asthma, or any major surgery.

**Address of Correspondence:** Dr. Saikat Das Gupta, Department of Cardiac Surgery, Square Hospitals Limited, Dhaka, Bangladesh. Email- [saikatdasgupta@gmail.com](mailto:saikatdasgupta@gmail.com)

© 2022 authors; licensed and published by International Society of Cardiovascular Ultrasound, Bangladesh Chapter and Bangladesh Society of Geriatric Cardiology. This is an Open Access article distributed under the terms of the CC BY NC 4.0 (<https://creativecommons.org/licenses/by-nc/4.0>)

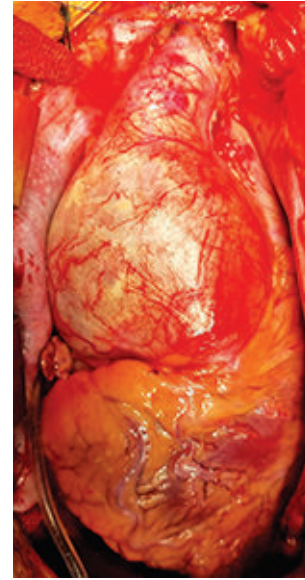


**Fig.-1:** X-ray chest PA view in the erect posture

His pre-operative BP was 110/80 mm of Hg and his heart rate was 90b/min. All his pre-operative biochemical reports were normal. His serum creatinine was 1.1 mg/dl, BSA was 1.8 m<sup>2</sup>, and his Euroscore II for in-hospital mortality was 2.84%. The patient's pre-operative color Doppler echocardiogram showed severe aortic regurgitation (eccentric jet) due to grossly dilated aortic root and ascending aorta. His AV annulus was 24 mm, sinotubular junction 56 mm, and ascending aorta was 66 mm. Good RV systolic function and global LV hypokinesia was also seen. His LVIDd/IDs were 80/64 mm with moderate LV systolic dysfunction (EF-40%) and PASP-was 40 mm of Hg. No pericardial effusion or intracardiac thrombus was seen. Coronary angiogram showed non-critical coronary artery disease (20-30% plaque) at mid LAD.

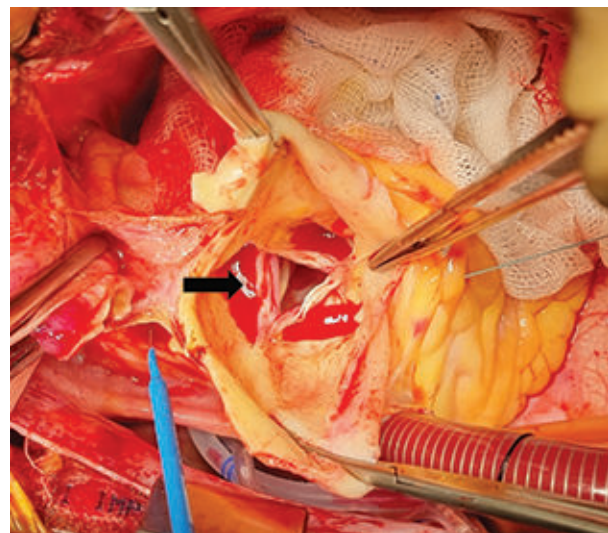
### Surgery:

The patient was operated under all aseptic precaution after optimizing his physical condition on October 2021. Central venous line (Right, jugular), right radial and left femoral arterial lines, rectal and nasopharyngeal temperature probes along with NIRS (near-infrared spectroscopy) were established. After median sternotomy, the thymus was dissected. Pericardiotomy was done and after heparinization and proper ACT, CPB was



**Fig 2:** Grossly dilated aortic root with the healthy distal aorta

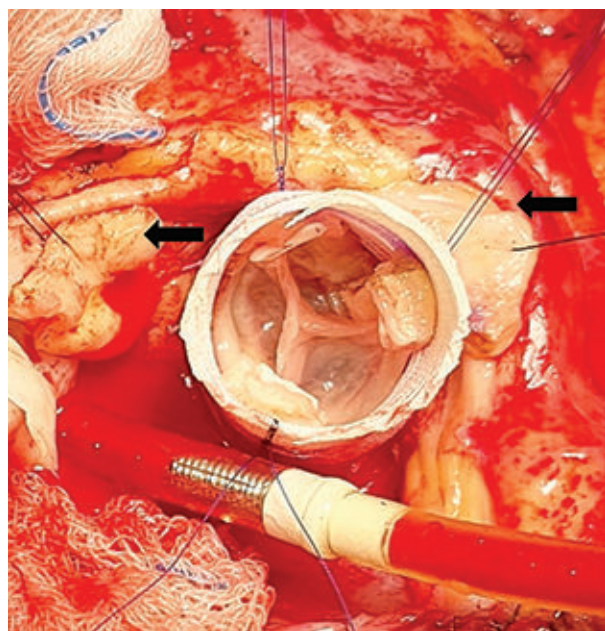
established with distal aortic arch and RA cannulation. The patient was cooled to 28 °C. An Aortic X clamp was applied at the distal ascending aorta and a horizontal aortotomy was done 1 cm above the STJ, followed by delivery of selective antegrade del-Nido cardioplegia. The heart was arrested at diastole. Left Ventricular (LV) venting was done through the right superior pulmonary vein. The aortic root and ascending aorta were found grossly dilated and the tricuspid aortic valve was found severely incompetent. During dissection



**Fig.-3:** Gross non-coaptation of aortic valve cusps (arrow) seen through the transected aorta

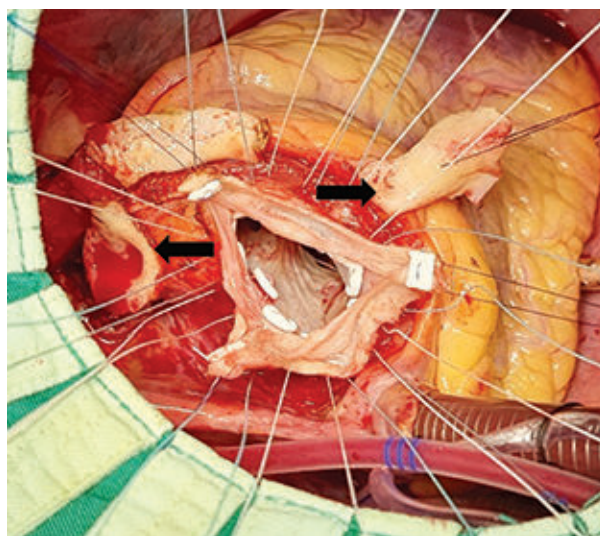
special care was taken not to injure RCA ostium as it may occasionally be misplaced cranially. Three traction stitches with 4-0 pledgeted polypropylene were placed at 3 commissures. Careful dissection of aortic root was done as low as possible starting from non-coronary sinus. Finally, two coronary buttons were harvested leaving 5-8 mm aortic tissue. Sizing of the graft was done with a valve sizer. The proximal anastomosis was completed with a 26 mm straight tube graft with 12 pledgeted 3-0 polyester stitches. The suture lines as well as the re-implanted valve were checked. Later on, both the coronary buttons were re-implanted and bio-glue was applied at the proximal suture line. The distal aortic anastomosis was done and the aortic cross-clamp was released after proper de-airing. Heart weaned from CPB at normal sinus rhythm. Total CPB time was 212 minutes and ACC time was 156 minutes. TEE showed a competent aortic valve. De-cannulation done. After achieving hemostasis chest wound was closed in layers keeping chest drain tubes and RV pacing wire in situ.

The patient was shifted to ICU with minimum inotrope support and was extubated on the subsequent morning. His postoperative chest drainage was minimum. The patient's in-hospital course was eventless, except once a mild decrease

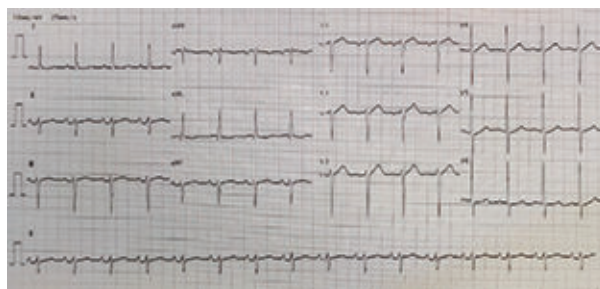


**Fig.-4:** Post repair aortic valve along with both the coronary buttons (arrows) to be anastomosed

of platelet counts on the 2nd postoperative day which came back to normal on the 5th postoperative day. His postoperative color Doppler echocardiogram showed a normally functioning aortic valve and the normal laminar flow inside the aortic conduit (MPG 05mm of Hg). No valvular or paravalvular leakage was seen. Good RV systolic function, global LV hypokinesia was seen along with moderate LV systolic dysfunction (EF-40%), Concentric LVH, PASP-30 mm of Hg. No pericardial effusion or intracardiac thrombus was seen. The patient was discharged on the 8th postoperative day with 75 mg clopidogrel and aspirin.



**Fig.-5:** Commissures suspended with stays along with both the coronary buttons (arrows)



**Fig 6:** Post-procedure ECG

#### Discussions:

One important worry is that when the aortic cusps are placed inside a cylindrical structure without aortic sinuses, the annulus becomes rigid, which may lead to increased stress on the aortic cusps and a higher risk of late valve failure.<sup>8</sup> Thus, many

surgeons' aimed to re-establish natural root geometry as far as possible as described by Pacini et al.<sup>9</sup> and later further optimized by de Kerchove et al.<sup>10,11</sup> Some surgeons advocate restoration of cusp coaptation well above the annular plane and to maintain a minimum of 7 mm of coaptation length. Schäfer's group clearly demonstrated the concept of effective coaptation height and its importance concerning the late outcome.<sup>12</sup> Moreover, the use of Schäfer's caliper to measure effective coaptation height for achieving and predicting the desired operative result has shown promising results. Lansac group has done extensive work for the standardization of the procedure.<sup>1</sup> The creation of the neo-sinuses has been simplified by the use of Valsalva prosthesis (Gelweave Valsalva™ by Sultzer Vascutek, Renfrewshire, Scotland). The exact measurements in the longitudinal direction are more detailed with the Valsalva prosthesis because it has no longitudinal stretch at the aortic root level.<sup>13</sup> But Valsalva grafts are costly, and to reduce the cost of surgery we are using straight tube grafts (thanks to Dr. Malakh Shreshtha for his excellent support to develop this technique). Short-term outcomes in our patients are encouraging with the straight tube grafts.

The primary indication for VSRR in all patients was aneurysm of the aortic root. Based on the ESC guidelines; thresholds for surgery were 50 mm root diameter at the sinus level in patients with connective tissue disease and 45 mm if risk factors like family history of aortic dissection, progressive dilatation (>2 mm/year), severe AR, or mitral valve regurgitation and desire for pregnancy.<sup>14</sup> For patients with bicuspid aortic valves, the threshold recently changed from 50 to 55 mm in the absence of other risk factors according to the latest ESC guidelines on valvular heart disease (version 2012).<sup>15</sup> Aortic root dimension > 55mm, has been suggested as a risk factor for late valve dysfunction after VSRR.<sup>16</sup> Extended indications include patients with acute aortic dissections (ADs), previous surgery for congenital heart disease (CHD), and connective tissue disorders (CTD), with published durable mid-term results.<sup>17</sup>

It has been demonstrated that aortic annular dilatation (aortic annulus >25 mm) is a risk factor for early and late failure.<sup>1</sup> Therefore, there is a

frequent need to reduce the aortic annulus. Sub-commissural annuloplasty described by Fraser and Cosgrove<sup>18</sup> is frequently used in aortic valve-sparing root replacement techniques. Clearly, it increases the area of cusp coaptation, and it is helpful to prevent or treat small residual leaks, especially if the exact mechanism is not completely clear. Abnormal cusp motion and restriction is one limitation of this technique, especially in the commissural area, which may induce an outflow gradient across the valve.

The re-implantation procedure has some clear benefits, such as the two suture lines (the sub-annular and the internal aortic), typically causing far superior hemostasis than with the remodeling procedure having only one suture line (often to the diseased aorta, which is more likely to bleed). The complete root of the aorta is reconstructed with this procedure, so in the future, if the spared valve becomes stenotic or incompetent to the extent of valve replacement, the reoperation includes removal and replacement of the native aortic valve instead of a full root re-replacement.<sup>19</sup> Infrequently, there is one young patient requiring aortic root replacement whose valve technically cannot be spared or who has contraindications for mechanical valve replacement or warfarin administration. In this scenario, the re-implantation procedure can be performed to reconstruct the aortic root, followed by excision of the native valve and replacement with a stented bio-prosthesis like a conventional aortic valve replacement (modified bio-Bentall's). Moreover, only a re-operative aortic valve replacement would be required when the bio-prosthesis fails. The re-implantation procedure can be beneficial, in cases of acute or chronic type A aortic dissection, where the aortic root is destroyed or dilated. It's because the dissection barely crosses the aortic annulus, and as a result permits the suture line to be placed in the so-called "normal" un-dissected sub-annular tissue.<sup>5</sup>

Preservation of the native aortic valve resulting in improved hemodynamics and the avoidance of lifelong systemic anticoagulation, especially in young patients are the clear benefits of this method.<sup>20</sup> Risk factors associated with long-term valve durability and requirements of reoperation are presently baffling. Bicuspid valve aortopathy,

aortic leaflet repair, and aortic root diameter have been associated with late aortic regurgitation and reoperations after VSRR.<sup>17</sup> Concerns are raised that preserving aortic valve leaflets in patients with CTD might be a risk factor for failed repair because of tissue weakness.<sup>20</sup> Yet, VSRR is accepted as the treatment of choice for aortic root dilatation and aortic valve regurgitation in patients with CTD. In a patient cohort, who included patients with BAV, severe aortic valve insufficiency, CHD, and type AAD, overall mid-term outcomes of VSRR in terms of survival, valve dysfunction, and reoperation rate were excellent.<sup>21</sup>

In our patient, the postoperative transthoracic color Doppler echocardiogram showed a normally functioning aortic valve and the normal flow inside the aortic conduit. We follow these patients with a transthoracic echocardiogram at six months and then yearly. At follow-up, after one month of surgery patient was doing satisfactory daily activities.

### Conclusion:

A properly performed operation reinstates the aortic root anatomy and it is almost indistinguishable from a normal aortic root on the echocardiogram. A definitive learning curve is required for mastering this technique like all other valve repair techniques. But we think many more surgeons should come forward as it's associated with lower mean aortic valve gradient, frequently seen after mechanical or biologic prosthesis replacement, and requires no anticoagulation.

---

### Conflict of Interest - None.

---

### References:

- Zehr K, Orszulak T, Mullany C et al. Surgery for aneurysms of the aortic root: a 30-year experience. *Circulation*. 2004;110(11):1364-1371. doi:10.1161/01.CIR.0000141593.05085.87
- Ikonomidis J, Kratz J, Crumbley A 3rd et al. Twenty-year experience with the St Jude Medical mechanical valve prosthesis. *J Thorac Cardiovasc Surg*. 2003;126(6):2022-2031. doi:10.1016/j.jtcvs.2003.07.005
- Birks E, Webb C, Child A, Radley-Smith R, Yacoub M. Early and long-term results of a valve-sparing operation for Marfan syndrome. *Circulation*. 1999;100(19 Suppl):II29-II35. doi:10.1161/01.cir.100.suppl\_2.ii-29
- David T, Feindel C, David C, Manlhiot C. A quarter of a century of experience with aortic valve-sparing operations. *J Thorac Cardiovasc Surg*. 2014;148(3):872-880. doi:10.1016/j.jtcvs.2014.04.048
- David T, Feindel C. An aortic valve-sparing operation for patients with aortic incompetence and aneurysm of the ascending aorta. *J Thorac Cardiovasc Surg*. 1992;103(4):617-622. doi:10.1016/s0022-5223(19)34942-6
- David T, Feindel C, Webb G, Colman J, Armstrong S, Maganti M. Aortic valve preservation in patients with aortic root aneurysm: results of the reimplantation technique. *Ann Thorac Surg*. 2007; 83(2):S732-S790. doi:10.1016/j.athoracsur.2006.10.080
- Lansac E, Di Centa I, Sleilaty G et al. An aortic ring: from physiologic reconstruction of the root to a standardized approach for aortic valve repair. *J Thorac Cardiovasc Surg*. 2010;140(6 Suppl):S28-S51. doi:10.1016/j.jtcvs.2010.08.004
- Leyh R, Schmidtke C, Sievers H, Yacoub M. Opening and closing characteristics of the aortic valve after different types of valve-preserving surgery. *Circulation*. 1999;100(21):2153-2160. doi:10.1161/01.cir.100.21.2153
- Pacini D, Settepani F, De Paulis R et al. Early Results of Valve-Sparing Reimplantation Procedure Using the Valsalva Conduit: A Multicenter Study. *Ann Thorac Surg*. 2006;82(3):865-872. doi:10.1016/j.athoracsur.2006.04.018
- Boodhwani M, de Kerchove L, Glineur D et al. Repair of regurgitant bicuspid aortic valves: a systematic approach. *J Thorac Cardiovasc Surg*. 2010; 140(2): 276-284.e1. doi:10.1016/j.jtcvs.2009.11.058
- de Kerchove L, Mosala Nezhad Z, Boodhwani M, El Khoury G. How to perform valve sparing reimplantation in a tricuspid aortic valve. *Ann Cardiothorac Surg*. 2013; 2(1):105-112. doi:10.3978/j.issn.2225-319X.2013.01.16
- Marom G, Haj-Ali R, Rosenfeld M, Schäfers HJ, Raanani E. Aortic root numeric model: annulus diameter prediction of effective height and coaptation in post-aortic valve repair. *J Thorac Cardiovasc Surg*. 2013; 145(2):406-411.e1. doi:10.1016/j.jtcvs.2012.01.080
- Koolbergen D, Manshanden J, Bouma B et al. Valve-sparing aortic root replacement†. *European Journal of Cardio-Thoracic Surgery*. 2014;47(2):348-354. doi:10.1093/ejcts/ezu167
- Groenink M, Lohuis T, Tijssen J et al. Survival and complication free survival in Marfan's syndrome: implications of current guidelines. *Heart*. 1999; 82(4): 499-504. doi:10.1136/hrt.82.4.499
- Vahanian A, Alfieri O, Andreotti F et al. Guidelines on the management of valvular heart disease (version 2012): the Joint Task Force on the Management of Valvular Heart Disease of the European Society of Cardiology (ESC) and the European Association for Cardio-Thoracic Surgery (EACTS). *Eur J Cardiothorac Surg*. 2012; 42(4):S1-S44. doi:10.1093/ejcts/ezs455
- Esaki J, Leshnower B, Binongo J et al. Risk Factors for Late Aortic Valve Dysfunction After the David V Valve-

- Sparing Root Replacement. *Ann Thorac Surg.* 2017; 104(5):1479-1487. doi:10.1016/j.athoracsur.2017.04.005
17. Valo J, Jokinen J, Kaarne M, Ihlberg L. Expanding indications for valve-sparing aortic root reconstruction: early and midterm results. *Ann Thorac Surg.* 2013; 95(2):579-585. doi:10.1016/j.athoracsur.2012.08.079
  18. Fraser CD Jr, Cosgrove DM 3rd. Surgical techniques for aortic valvuloplasty. *Tex Heart Inst J.* 1994; 21(4):305-309.
  19. Ikonomidis J, Miller D. Stentless bioprosthetic aortic valve replacement after valve-sparing aortic root replacement. *J Thorac Cardiovasc Surg.* 2002; 124(4):848-851. doi:10.1067/mtc.2002.124396
  20. Flynn C, Tian D, Wilson-Smith A et al. Systematic review and meta-analysis of surgical outcomes in Marfan patients undergoing aortic root surgery by composite-valve graft or valve sparing root replacement. *Ann Cardiothorac Surg.* 2017;6(6):570-581. doi:10.21037/acs.2017.11.06
  21. Huuskonen A, Valo J, Kaarne M et al. Outcome of valve sparing root replacement for diverse indications. *Scand Cardiovasc J.* 2021; 55(3):173-179. doi:10.1080/14017431.2020.1869298