

Histo morphometric evaluation of testes of Black Bengal goats

AB Siddique, KA Ferdous*, MNH Parvez, MS Islam, MA Hassan, M Kamruzzaman¹ and NR Sarker²

Department of Anatomy and Histology, Faculty of Veterinary and Animal Science, Hajee Mohammad Danesh Science and Technology University, Dinajpur-5200, Bangladesh

Abstract

This study was designed to explore the gross and microscopic structures of the testes of Black Bengal bucks (n = 14) with special emphasis on the seminiferous tubules. A quantitative comparison of the various cell types in the seminiferous tubules of the testes were done. Biometrical values of testes were recorded. The left testes were significantly larger than the right. The mean length, width, weight and circumference of the left testis were 6.7 ± 0.1 cm, 3.9 ± 0.0 cm, 66.9 ± 0.8 gm and 13.4 ± 0.2 cm, respectively. The mean length, width, weight and circumference of the right testis were 6.3 ± 0.0 cm, 3.8 ± 0.0 cm, 66.5 ± 0.8 gm and 13.1 ± 0.1 cm, respectively. For microscopic studies tissue samples were evaluated with quantitative techniques. The testis was encapsulated by tunica toward the mediastinum testis. The testicular parenchyma was divided into convoluted seminiferous tubules and Leydig cells, which were found in the intertubular spaces. (*Bangl. vet.* 2018. Vol. 35, No. 1 & 2, 40 – 46)

Introduction

The testes are responsible for the secondary male sex characters such as the development of accessory sex glands, elongation of penis and maintenance of voice of animals (Copenhaver *et al.*, 1978). The testicular parenchyma is composed of seminiferous tubules and the Leydig cells or interstitial cells. The Leydig cells secrete testosterone, responsible for male sexuality (Hafez, 2000; Dellman, 1992). Present study focuses on the shape, weight, length, width and circumference of testes, with histological study of the testes of Black Bengal bucks with special emphasis on the seminiferous tubules.

Materials and Methods

Sample collection

Fourteen adult sexually mature Black Bengal bucks (*Capra hircus*) aged 1.5 to 2 years were selected. All animals were examined for general health and the appearance of genitalia. The testes were palpated and observed for their size, shape, free movement and position in the scrotum. The scrotal skin was examined for any lesions. Each

¹Department of Dairy and Poultry Science and Hajee Mohammad Danesh Science and Technology University, Dinajpur-5200, Bangladesh

²Department of Genetics and Animal Breeding, Hajee Mohammad Danesh Science and Technology University, Dinajpur-5200, Bangladesh

*Corresponding author:- E-mail: azfat2017@gmail.com

testicle was taken in buffered neutral formalin solution immediately after slaughter. The extraneous material including the fat and fascia were removed. The epididymis and spermatic cord were dissected from the main testicular body.

Gross anatomical study

Scrotal circumference was measured by encircling the thickest portion of the testicle by a graduated tape. The length of each testis was measured along their long axis. The diameter was measured in the cranio-caudal plane at the greatest distance using Vernier calipers. The weights were measured by electric balance.

Histological study

Immediately after gross anatomical study, testis tissues were cut into small pieces for histological study from dorsal (part attached to the caput epididymis), middle and ventral part (attached to the cauda epididymis). The pieces were transferred to Bouin's fluid for 24 hours. The fixed tissues were then dehydrated by transferring through progressively more concentrated ethanol (80, 90, 95, 100, 100 and 100%) for 1 hour in each grade. It was then transferred to clearing agent, xylene, twice for 90 minutes to remove the ethanol. The tissues were then infiltrated with two changes in liquid paraffin in the oven for two hours, then placed in liquid paraffin for embedding, and sectioned at six μm thickness using microtome (Micom GmbH, type HM 325, Germany). The sections were floated in a water bath at 55°C then taken on cleaned slides using egg albumin and dried in slide warmer. The sectioned tissues were deparaffinized by transferring them through xylene twice for 15 minutes. Then these were transferred through descending grade of alcohol (100, 95, 90, 80 and 70%). Tissues were stained with haematoxylin and eosin (Gridly, 1960). The tissues then were dehydrated by transferring through baths of progressively more concentrated ethanol (70, 80, 90, 95 and 100%) and passed through xylene. After the staining, cover slips were placed on the slide and mounted with Canada balsam.

Microscopic observations

The stained tissues sections were studied under compound monocular microscope. The evaluation included tubular diameter and morphology and the germ cell type present in each tubular section, tunica albuginea and Leydig cells.

Photography

Images were captured from random areas.

Analysis of results

Statistical analysis of the data was done by paired *t*-test using SPSS program. The gross measurements of the left and right testis were compared by *t*-test.

Results and Discussion

Gross anatomy

The long axis was vertical in position but slightly caudally projected, consistent with Getty (1975); Hafez (2000).

The circumference of the left testis was 13.4 ± 0.2 cm and the right 13.1 ± 0.1 cm. (Table 1). Kridli *et al.* (2005) found the circumference of testis of adult buck as 13.3 ± 0.1 cm for left and right testis.

The testis was elongated with an oval outline (Fig. 1), in agreement with Getty (1975).

The length and width of the left testis were higher than those of the right (Fig. 2), similar to the finding of Getty (1975). The average length and width in buck for the left testis were 6.7 ± 0.1 cm and 3.9 ± 0.0 cm, respectively and the right testis was 6.3 ± 0.0 and 3.8 ± 0.0 cm (Table 1). The difference was significant.

The left testis weighed more than the right (Table 1), similar to Getty (1975). The left testis weighed 66.9 ± 0.8 gm and the right 66.5 ± 0.8 gm (Table 1).

Histology

The visceral layer of the tunica vaginalis consisted of a mesothelium and a connective-tissue layer that blends with the tunica albuginea, similar to the findings of Dellman (1992).

The tunica albuginea was a solid capsule of dense irregular connective tissue surrounding the testis, similar to Bache and Wood (1990); Dellmann (1992); Johnson *et al.* (1970); Copenhaver *et al.* (1978). In the tunica albuginea, there was a layer of interweaving, coarse collagenous fibres, a few elastic fibres and myofibroblasts, constituting most of the tunica albuginea. Copenhaver *et al.* (1978) and Dellmann (1992) made similar observations in human. In the inner part of this layer, the tunica vasculosa was composed of loose connective tissue and blood vessels. Similar report was given in human by Copenhaver *et al.* (1978).

The septula testis was inconspicuous connective tissue strands continued from the tunica albuginea towards the mediastinum testis. These divided the testicular parenchyma into lobules, which contained the seminiferous tubules. Dellmann (1992); Copenhaver *et al.* (1978); Stiles (1956) stated similar observations.

The seminiferous tubules constituted the major part of the testicular parenchyma. The seminiferous tubules were convoluted, tortuous, round or oblong, similar to findings of Dellmann (1992) and Hafez (2000). The tubular wall consisted of outer capsule, tunica propria, a basal lamina, basement membrane supported by connective tissue fibres and a lining of complex stratified epithelium, which consisted of sustentacular cells or Sertoli cells. Copenhaver *et al.* (1978) and Ham (1979) made similar reports.

The diameter of the seminiferous tubules varied significantly in different testes. Their nuclei were ovoid or pear-shaped, located at varying positions mostly in the broad

basal portion and some were located at a variable distance from the basal lamina (Fig. 3). Similar findings were reported by Dellmann (1992); Hafez (2000) and Copenhaver *et al.* (1978).

The spermatogenic cells were in an orderly manner between the Sertoli cells, with four to eight layers in the space between the basal lamina and the tubular lumen (Fig. 5), similar to the finding of Copenhaver *et al.* (1978). Spermatogonia, primary spermatocytes, secondary spermatocytes, spermatids and the spermatozoa were arranged in rows from the basement membrane of the seminiferous tubule towards the lumen, respectively (Fig. 5). Spermatogonia (primitive germ cells), from which all the spermatozoa were ultimately derived, were spherical or cuboidal in shape with spherical nucleus, similar to the observation by Lino (1972). The primary spermatocytes were larger cells with round nucleus, next to the spermatogonia on the side of the lumen of the seminiferous tubule. The secondary spermatocytes were smaller than the primary spermatocytes. From one primary spermatocyte two secondary spermatocytes were derived and they were located internal to the primary spermatocytes, similar to the report by Copenhaver *et al.* (1978).

Each secondary spermatocyte through the second meiotic division divided to form two spermatids, which remained in clusters. The clusters of developing spermatids were associated with Sertoli cells. The spermatids were round with pale nuclei and were found towards the lumen of the seminiferous tubule. The late spermatids had dark head and long tail, which were projected towards the lumen of the seminiferous tubules. These observations agree with Lino (1972). The spermatids underwent no further division and were transformed into the mature spermatozoa, located in the lumen of the seminiferous tubules. They had an oval head containing the nucleus and a long tail. In some seminiferous tubules, there were spermatids instead of spermatozoa, some contained spermatids and spermatozoa and in others a varying number of spermatozoa were present (Fig. 5). These observations agree with Copenhaver *et al.* (1978).

In the intertubular spaces, the stroma contained the interstitial cells, loose connective tissue, blood and lymph vessels, fibrocytes and free mononuclear cells (Fig. 4). The interstitial cells are large, with an eccentrically located large nucleus and ovoid or polygonal in shape (Fig. 4). These cells were mostly in cords or clusters of various sizes and sometimes as single cells, similar to the findings of Dellmann (1992); Fawcett *et al.* (1973) and Copenhaver *et al.* (1978).

Table 1: Length, width, weight and circumference of the testis of buck: (n=14) (mean \pm s.d.)

Testis	Length (cm)	Width (cm)	Weight (gm)	Circumference (cm)
Left	6.7 \pm 0.1	3.9 \pm 0.00	66.9 \pm 0.8	13.4 \pm 0.2
Right	6.3 \pm 0.0	3.8 \pm 0.0	66.5 \pm 0.8	13.1 \pm 0.1

Gross Anatomy of the testis of bucks

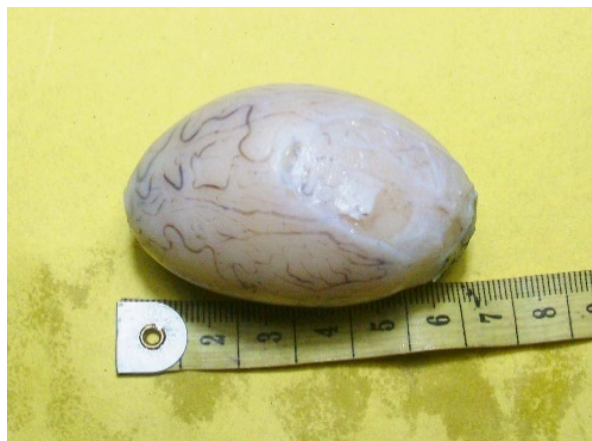

Fig. 1: Measurement of the length of the testis of bucks with scale and tape.



Fig. 2: Measurement of the weight of the testis of bucks with Digital weight Machine.

Microscopic observation of testis of buck

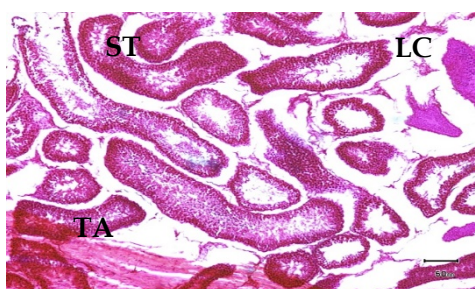


Fig. 3: Microphotograph showing the tunica albuginea (TA), seminiferous tubule (ST) and Leydig cell (LC). (H & E stain; x 10).

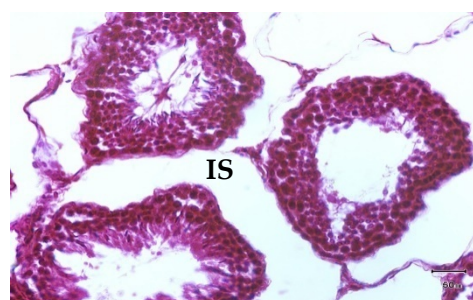

Fig. 4: Microphotograph showing interstitial space (IS). (H & E stain; x 40).

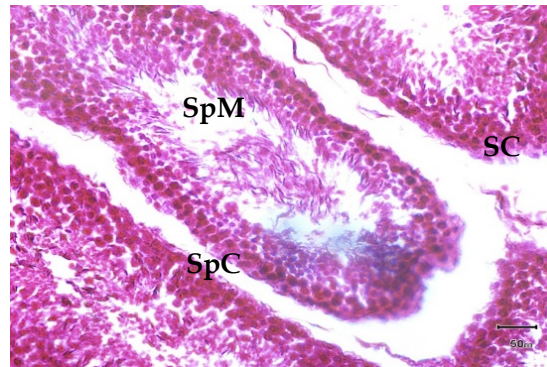


Fig. 5: Microphotographs showing the spermatogenic cells (SpC) including cluster of spermatozoa (SpM) and Sertoli cells (SC) (H & E stain; x 40).

Conclusions

The length, width, weight and circumference of the left testis were significantly greater than right testis. The testis was encapsulated by tunica albuginea, which was a layer of interweaving, coarse collagenous fibres, a few elastic fibres and myofibroblasts. Leydig cells or interstitial cells were located in the intertubular spaces. These cells were large with an eccentrically located large nucleus and ovoid or polygonal in shape. These were mostly in cords or clusters of various sizes and sometimes as single cells. The spermatogonia, primary spermatocytes, secondary spermatocytes, spermatids and the spermatozoa were arranged in an orderly manner in rows from the basement membrane of the seminiferous tubule towards the lumen.

References

- Bache WJ, LM Wood 1990: Colour Atlas of Veterinary Histology. Lea & Fibiger, Philadelphia, London.
- Copenhaver WM, Kelly DE, Wood RI 1978: Baileys Text book of Histology. 17th Edn, The Williams and Wilkinson Company, Baltimore.
- Dellman HD 1992: Text book of Veterinary Histology. 5th Ed., Philadelphia 306-11.
- Fawcett DS 1975: The ultra-structure and function of the Sertoli cell. In: Handbook of Physiology, Vol. 1 Male Reproduction (RO Greed and FW Hamilton), American physiological Society, Bethesda 21-55.
- Getty R 1975: The Sisson and Grossman's the Anatomy of the Domestic Animals. Vol. 1. 5th Edn, WB Saunders Company, Philadelphia. London, Toronto.
- Gridley MF 1960: Manual of Histological and special staining Technique 2nd Edn, McGraw- Hill Book Company.
- Gridley R 1957: The sis son and Grossman's the Animals. Vol. I, 5th End, WB Saunders Company Philadelphia London, Toronto.

- Hafez RSE 2000: *Reproduction in Farm Animals*. 7th Edna, Lea & Fibiger, Philadelphia.
- Ham AW 1979: *Histology*. 5th Edn. JB Lippincott Company. Philadelphia, New York. 273-289.
- Johnson AD, WR Gomes, NL and Vandermark 1970: *The testis*. 5th Edn, New York, *Academic Press*. 443-533.
- Kridli RT, Tabbaa MJ, Sawalha RM 2005: Comparative Study of Scrotal Circumference and Semen Characteristics of Mountain Black Goat and Its Crossbred with Damascus Goat as Affected by Different Factors. *Jordan Journal of Agricultural Sciences*. **1** 18-25.
- Lino BF. 1972. The output of spermatozoa in relationship to scrotal circumference testis weight and the number of spermatozoa in different parts of the urogenital tract. *Australian Journal of Biological Science*. **25** 359-366.
- Maloney SK, Bonomeli JM, Desouza J 2003: Scrotal heating stimulates panting and reduces body temperature similarly in febrile and non-febrile rams.
- Miller ME 1964: *Anatomy of the Dog*. 1st edition, WB Saunders Company Philadelphia, London.
- Stiles AK 1956: *Handbook of histology*, 4th Edn McGraw Hill Book Company.