

CASE REPORT

Pierson syndrome presenting as Alport syndrome: A case report

Samina Masud Santa, Tahmina Akter Diba, Abdullah Al Mamun, Afroza Begum, Syed Saimul Haque

Department of Paediatric Nephrology, Bangabandhu Sheikh Mujib Medical University, Dhaka, Bangladesh

Correspondence to: Samina Masud Santa, Email: santa023@yahoo.com

ABSTRACT

Pierson syndrome is an autosomal recessive disorder, characterised by congenital nephrotic syndrome and progressive renal failure. Patient of this syndrome may have some ocular abnormalities. We report a 46 month old girl with Pierson syndrome whose renal biopsy showed features suggestive of Alport syndrome. Genetic study report showed laminin β 2 (LAMB2) mutation which presents as nephrotic syndrome, type 5 with or without ocular abnormalities and Pierson syndrome, and tripartite motif containing 8 (TRIM8) mutation which presents with focal segmental glomerulosclerosis and neurodevelopmental syndrome. The patient was given supportive therapy.

Keywords: Pierson syndrome, Alport syndrome

INTRODUCTION

Pierson syndrome (OMIM 609049) is a rare autosomal recessive disorder described by Pierson et al. in 1963.¹ This syndrome comprises of 2 main components: congenital nephritic syndrome (CNS) with diffuse mesangial sclerosis and distinct ocular abnormality.² Pierson syndrome has been identified as the fourth most common cause of CNS.³ These patients with CNS usually rapidly progress to end-stage renal disease within 3 months of life and can be accompanied by extra-renal manifestations like microcoria and neurodevelopmental abnormalities. Genetic background is identified as the mutation in the (LAMB2) gene on chromosome 3p21. Here we report a patient of CNS with LAMB2 mutation for Pierson syndrome.

CASE DESCRIPTION

Maliha, a 46-month old girl, second issue of her consanguineous parents, hailing from Dhaka, Bangladesh got admitted into Bangabandhu Sheikh Mujib Medical University (BSMMU), Shahbag, Dhaka with the complaints of persisting proteinuria, persisting microscopic hematuria since her 8 months of age and abnormal eye movement since 6 months of age. Her mother is a diagnosed case of nephrotic syndrome since her 10 years of age, now in remission for last 20 years (renal biopsy showed stage 1 membranous

nephropathy). Mithila was diagnosed provisionally as familial glomerulonephritis with nystagmus. Her 1st attack was at the age of 8 months when she presented with facial puffiness, proteinuria, scanty micturition for 7 days and treated with oral prednisolone daily 60 mg/m²/day for 6 weeks and then 40 mg/m²/day for 6 weeks and responded well at that time. Subsequently she had recurrent episodes of relapses with microscopic hematuria without any swelling and treated with prednisolone and angiotensin converting enzymes inhibitor. She had no history of fever, rash, photosensitivity, joint pain, oral ulcer, gross hematuria, abdominal pain, headache, hearing difficulties. Due to persistent proteinuria she was treated with tacrolimus for 9 months.

She was lost to follow-up a while, but reported back to BSMMU. Then she had raised serum creatinine. Therefore, tacrolimus was switched to mycophenolate mofetil (MMF) but proteinuria was persisting. Then she was referred to Department of Paediatric Nephrology, BSMMU. On admission, she was vitally stable, nystagmus present, oedema and ascites were absent, bedside urine for albumin was +++ (+++ reaction is a white cloudiness with fine precipitate through which black printed lines are not visible and amounts to 300 to 1000 mg protein/dl). Laboratory workup showed mild microcytic hypochromic anaemia. Urine routine

LEARNING POINTS

1. Pierson syndrome is an autosomal recessive disorder which is usually presented as congenital nephrotic syndrome.
2. Genetic study is the confirmatory test for Pierson syndrome.

examination showed protein ++ (++ reaction is a white cloudiness through which black printed lines are visible but cannot be read and amounts to 100 to 299 mg protein/dl), a red blood cell and no growth in urine culture. Urinary spot protein creatinine ratio was 15.7. Serum creatinine was raised (0.7 mg/dl) with an estimated glomerular filtration rate of 53.8 ml/min/1.73 m².

CASE MANAGEMENT

Because the patient could not achieve remission with oral prednisolone, tacrolimus was tried. Unfortunately, after 9 months, tacrolimus had to be switched to MMF due to persistently raised serum creatinine. She did not achieve remission even after all these immunosuppressive drugs. Therefore, gradually all immunosuppressives were discontinued and only supportive management was given: normal diet, ramipril 0.05 mg/kg/day, calcium carbonate 45 mg/kg/day, colecalciferol 90 IU/kg/day, folic acid 0.4 mg/kg/day, and iron polymaltose complex 3 mg/kg/day.

TABLE 1 Likely compound heterozygous variants to be causative of the reported phenotypes were identified

Gene (Transcript)	Location	Variant	Zygosity	Disease (OMIM)	Inheritance	Classification
LAMB2(-) (ENST00000305544)	Intron 10	c.1405+1G>A (Splice variant)	Heterozygous	Nephrotic syndrome, type 5, with or without ocular abnormalities: Pierson syndrome	Autosomal recessive	Pathogenic
	Exon 4	c.397G>T (p.Val133Phe)	Heterozygous			Uncertain significance
ADDITIONAL FINDINGS: VARIANT(S) OF UNCERTAIN SIGNIFICANCE (VUS) DETECTED						
Gene (Transcript)	Location	Variant	Zygosity	Disease (OMIM)	Inheritance	Classification
TRIM8(+) (ENST00000643721.2)	Exon 1	c.173C>t (p.Ala58Val)	Heterozygous	Focal segmental glomerulosclerosis and neuro-developmental syndrome	Autosomal dominant	Uncertain significance

Her right eye was normal. Left eye had mild to moderate membrane line echogenic shadow in the vitreous cavity suggestive of rhegmatogenous retinal detachment. Hearing was normal. Ultrasonography revealed normal shape kidneys. The length of right kidney was 7.7 cm and left kidney was 7.1 cm. Cortical echogenicity was increased and cortico-medullary differentiation was maintained. These suggested bilateral renal parenchymal disease. Renal biopsy revealed interstitial foam cells, mild tubulointerstitial chronicity with 10-15% interstitial fibrosis and tubular atrophy, segmental mesangial hypercellularity, segmental glomerulosclerosis, irregular capillary wall thickening. Direct immunofluorescence examination revealed no deposition of any antibody. All the biopsy features were consistent with Alport syndrome. Genetic study (next generation sequencing) was performed which revealed a LAMB2 mutation which presents as nephrotic syndrome (type 5) and Pierson syndrome, and tripartite motif containing mutation⁸ which presents as focal segmental glomerulosclerosis and neuro-developmental syndrome.

DISCUSSION

The glomerular basement membrane (GBM) is an important component of the kidney's glomerular filtration barrier. GBM contains type IV collagen, laminin, nidogen, and heparan sulfate proteoglycan like any other basement membrane. Mutation in GBM's collagen $\alpha3\alpha4\alpha5(IV)$ components cause Alport syndrome and mutation in LAMB2 causes Pierson syndrome.⁴ Our patient clinically had persistent microscopic hematuria, positive family history of nephritic syndrome of mother which are the points in favour of Alport syndrome. Her renal biopsy showed findings indicative of Alport syndrome also. However, her infantile nephrotic syndrome, retinal detachment were suggestive of Pierson syndrome. Genetic study revealed LAMB2 mutation considered to be nephrotic syndrome, (type 5) and Pierson syndrome. TRIM8 mutation are considered to be FSGS and neuro-developmental syndrome. Although the patient was histologically diagnosed as Alport syndrome, her family history, presentation of CNS and the genetic study findings are consistent with the Pierson syndrome.

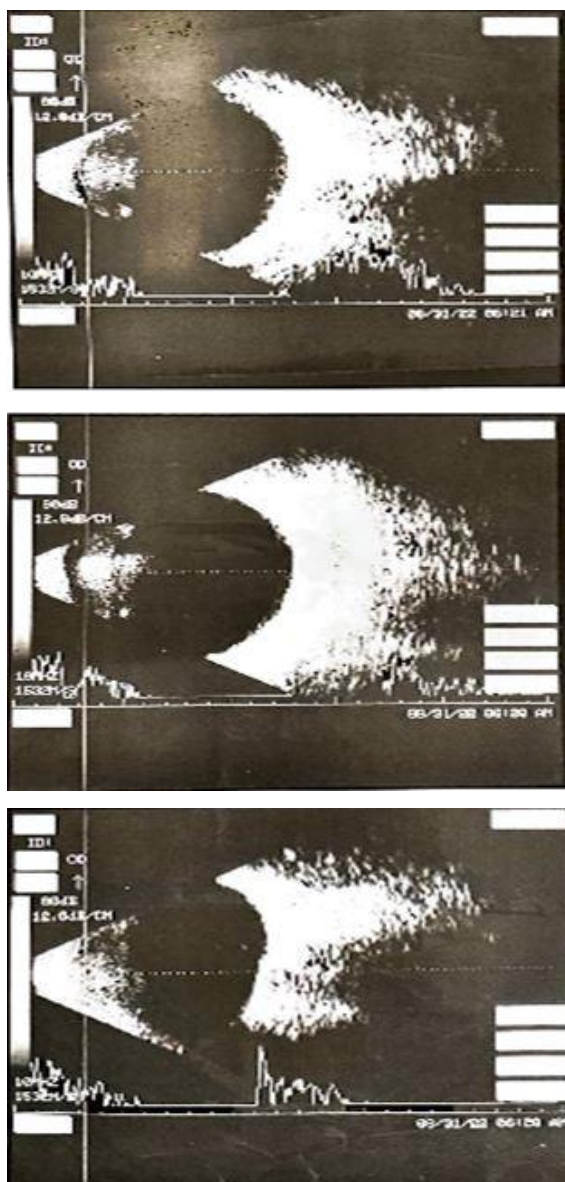


FIGURE 1 Photograph of B scan of both eyes

The distribution of laminin b2 matches the pattern of involvement seen in Pierson syndrome, which usually presents with characteristic ocular abnormalities in addition to CNS. Here, the glioblastoma multiforme is more severely and uniformly affected than other sites. This is supported by reports of patients with less severe LAMB2 mutations and partial expression of laminin b2 showing a spectrum of phenotypic manifestations but invariably presenting with renal dysfunction.^{3,5,6} Our patient did not have the characteristic ocular abnormality, but she had some extent of impaired renal function. Recent reports show that patients with

truncating mutations do not always present with severe features. Two Asian subjects with bi-allelic truncated mutations had a normal renal function until 3 and 6 years of age.^{7,8} Ocular involvement is also an important finding in Pierson syndrome and the most common ocular anomaly is microcoria. Although Maliha did not have the characteristic eye findings of Pierson syndrome, ophthalmological examination revealed rhegmatogenous retinal detachment which is a common posterior segment change for children with this syndrome.⁹

The Alport syndrome and Pierson syndrome have guarded prognosis. In case of untreated male patient with x-linked Alport syndrome, the probability of developing end-stage renal disease is 50% by age 25, 80% by age 40 and 100% by age of 60 years.¹⁰ The prognosis for patients with Pierson syndrome is guarded. Most patients progress to end-stage renal disease in infancy and most of them die before 2 years of age. Zenker et al mentioned that child with Pierson syndrome usually develops end-stage renal disease by a few weeks or months of age.¹¹ Treatment for Pierson syndrome is only supportive and aims at controlling the effects of renal failure and nephrotic syndrome.¹²

We conclude that a child's presentation mimicking Alport syndrome actually can be a case of Pierson syndrome. Use of LAMB2 genotyping would help establishing the diagnosis. Necessary alertness of the responsible physicians are warranted.

Acknowledgments

We acknowledge Prof. Arvind Bagga, Division of Pediatric Nephrology, All India Institute of Medical Sciences, Delhi, India for his support for diagnosis and management of the case and also the patient who participated in this study.

Author Contributions

Conception and design: SSH, SMS, TAD. Acquisition, analysis and interpretation of data: SSH, TAD, SMS. Manuscript drafting and revising it critically: SSH, SMS, TAK, AAM, AB. Approval of final version of manuscript: SSH, SMS, TAK, AAM, AB. Guarantor accuracy and integrity of the work: SSH, SMS, TAK, AAM, AB.

Funding

None.

Conflict of Interest

All authors has no conflict of interest.

Ethical Approval

Ethical approval was not needed for case report but informed consent was obtained from parent.

ORCID iD

Samina Masud Santa <https://orcid.org/0009-0007-1325-1406>

REFERENCES

- Pierson M, Cordier J, Hervouet F, Rauber G. Une curieuse association malformative congénitale et familiale atteignant l'oeil et le rein [an unusual congenital and familial congenital malformative combination involving the eye and kidney]. *J Genet Hum.* 1963 Dec;12:184-213. French. PMID: [14136829](https://pubmed.ncbi.nlm.nih.gov/14136829/).
- Zenker M, Aigner T, Wendler O, Tralau T, Müntefering H, Fenski R, Pitz S, Schumacher V, Royer-Pokora B, Wühl E, Cochat P, Bouvier R, Kraus C, Mark K, Madlon H, Dötsch J, Rascher W, Maruniak-Chudek I, Lennert T, Neumann LM, Reis A. Human laminin beta2 deficiency causes congenital nephrosis with mesangial sclerosis and distinct eye abnormalities. *Hum Mol Genet.* 2004 Nov 1;13(21):2625-2632. DOI: <https://doi.org/10.1093/hmg/ddh284>. Epub 2004 Sep 14.
- Kagan M, Cohen AH, Matejas V, Vlangos C, Zenker M. A milder variant of Pierson syndrome. *Pediatr Nephrol.* 2008;23:323-327. DOI: <https://doi.org/10.1007/s00467-007-0624-x>.
- Funk SD, Lin MH and Miner JH. Alport Syndrome and Pierson Syndrome: Disease of the Glomerular Basement Membrane. *HHS Public Access.* 2018;71-72: 250-261. DOI: <https://doi.org/10.1016/j.matbio.2018.04.008>.
- Choi HJ, Lee BH, Kang JH, Jeong HJ, Moon KC, Ha IS, Yu YS, Matejas V, Zenker M, Choi Y, Cheong HI. Variable phenotype of Pierson syndrome. *Pediatr Nephrol.* 2008 Jun;23(6):995-1000. DOI: <https://doi.org/10.1007/s00467-008-0748-7>.
- Kino J, Tsukaguchi H, Kimata T, Nguyen HT, Nakano Y, Miyake N, Matsumoto N, Kaneko K. Nephron development and extrarenal features in a child with congenital nephrotic syndrome caused by null LAMB2 mutations. *BMC Nephrol.* 2017 Jul 6;18(1):220. DOI: <https://doi.org/10.1186/s12882-017-0632-4>.
- Bredrup C, Matejas V, Barrow M, Bláhová K, Bockenbauer D, Fowler DJ, Gregson RM, Maruniak-Chudek I, Medeira A, Mendonça EL, Kagan M, Koenig J, Krastel H, Kroes HY, Saggari A, Sawyer T, Schittkowski M, Swietliński J, Thompson D, VanDeVoorde RG, Wittebol-Post D, Woodruff G, Zurowska A, Hennekam RC, Zenker M, Russell-Eggitt I. Ophthalmological aspects of Pierson syndrome. *Am J Ophthalmol.* 2008 Oct;146(4):602-611. DOI: <https://doi.org/10.1016/j.ajo.2008.05.039>.
- Zhao D, Ding J, Wang F, Fan Q, Guan N, Wang S, Zhang Y. The first Chinese Pierson syndrome with novel mutations in LAMB2. *Nephrol Dial Transplant.* 2010;25:776-778. DOI: <https://doi.org/10.1093/ndt/gfp563>.
- AlTaisan A, Magliyah M, Abouammoh MA, Taskintuna I, Alzahrani Y, Chang E, Alsulaiman SM. Posterior Segment Characterization in Children With Pierson Syndrome. *Ophthalmic Surg Lasers Imaging Retina.* 2020 Nov 1;51(11):618-627. DOI: <https://doi.org/10.3928/23258160-20201104-03>.
- Jais JP, Knebelmann B, Giatras I, Marchi M, Rizzoni G, Renieri A, Weber M, Gross O, Netzer KO, Flinter F, Pirson Y, Verellen C, Wieslander J, Persson U, Tryggvason K, Martin P, Hertz JM, Schröder C, Sanak M, Krejcova S, Carvalho MF, Saus J, Antignac C, Smeets H, Gubler MC. X-linked Alport syndrome: natural history in 195 families and genotype-phenotype correlations in males. *J Am Soc Nephrol.* 2000 Apr;11(4):649-657. DOI: <https://doi.org/10.1681/ASN.V114649>.
- Zenker M, Aigner T, Wendler O, Tralau T, Müntefering H, Fenski R, Pitz S, Schumacher V, Royer-Pokora B, Wühl E, Cochat P, Bouvier R, Kraus C, Mark K, Madlon H, Dötsch J, Rascher W, Maruniak-Chudek I, Lennert T, Neumann LM, Reis A. Human laminin beta2 deficiency causes congenital nephrosis with mesangial sclerosis and distinct eye abnormalities. *Hum Mol Genet.* 2004 Nov 1;13(21):2625-2632. DOI: <https://doi.org/10.1093/hmg/ddh284>.
- Hiser W, Thirumala V, Wang J, Gillespie R, Bedri B, Zhou XJ. Pierson Syndrome in an Infant With Congenital Nephrotic Syndrome and Unique Brain Pathology. *Kidney Int Rep.* 2020 Oct 1;5(12):2371-2374. DOI: <https://doi.org/10.1016/j.ekir.2020.09.023>.