

Ultrasound estimated bladder weight in the detection and post-operative follow-up of bladder outflow obstruction

Mohammad Shafiqur Rahman, Mohammad Khairuzzaman, Md. Saiful Islam, Muhammad Humayun Kabir and Faika Farah Ahmed

Article Info

Department of Urology, Faculty of Surgery, Bangabandhu Sheikh Mujib Medical University, Shahbag, Dhaka, Bangladesh

For Correspondence:

Mohammad Shafiqur Rahman
shafiqbsmmu@gmail.com

Received: 6 March 2018
Accepted: 24 May 2018
Available Online: 30 May 2018

ISSN: 2224-7750 (Online)
2074-2908 (Print)

DOI: 10.3329/bsmmuj.v11i2.35896

Keywords: Bladder neck hypertrophy; Bladder outflow obstruction; Bladder weight; Enlargement; Prostate; Ultrasound; Urethral stricture; Urinary bladder

Cite this article:

Rahman MS, Khairuzzaman M, Islam MS, Kabir MH, Ahmed FF. Ultrasound estimated bladder weight in the detection and post-operative follow-up of bladder outflow obstruction. Bangabandhu Sheikh Mujib Med Univ J. 2018; 11: 185-188.

Copyright:

The copyright of this article is retained by the author(s) [Attribution CC-BY 4.0]

Available at:

www.banglajol.info

Abstract

This study was performed to standardize the ultrasound estimated bladder weight as an additional non-invasive test for the measurement of the bladder outflow obstruction and to measure the therapeutic effects of bladder outflow obstruction in the follow-up after surgical correction of obstruction. This study was conducted from December 2012 to May 2014 where the sample size was 55 and sampling technique was purposive. In bladder outflow obstruction patient, trans-abdominal sonography was performed using a 7.5 MHz. probe. The anterior bladder wall thickness was measured in three points in the midline 1 cm apart and the average value was recorded. After that bladder volume was measured by ultrasonogram. In pre- and post-operative groups ultrasound estimated bladder weight was measured from bladder wall thickness and bladder volume. In this study, the mean \pm SD of age was 48.8 ± 15.0 years. In bladder outflow obstruction patient, the pre-operative ultrasound estimated bladder weight was 117 ± 45.1 g which was reduced to 53.9 ± 10.8 g three months after surgical correction of obstruction. The ultrasound estimated bladder weight is a non-invasive, cheap and easily available additional diagnostic tool for detecting bladder outflow obstruction as well as it can measure the therapeutic effects in post-operative period.

Introduction

Compensatory hypertrophy following infra-vesical obstruction leads to increase in blood perfusion to the urinary bladder wall muscles. The compensatory hypertrophy and blood flow decrease on relief of obstruction in the animal study.¹ For the diagnosis of bladder outflow obstruction the measurement of the pressure flow study is considered as gold stander but as it is an invasive procedure and limited availability, it replaced by ultrasound estimated bladder weight measurement non-invasively.²⁻⁴

The urinary bladder which is formed by three layers shows different echogenicity on the ultrasound imaging. The detrusor muscle layer shows by a hypoechogenic layer between two hyperechogenic layers the serosa and mucosa respectively.^{5,6} The measurement of different layers of urinary bladder varies investigator to investigator. Some measured the whole thickness of three layers together but others use the measurement of middle detrusor muscle only.^{7,8} The way of measurement of the wall also varies. Most of the investigator prefer to measure anterior bladder wall but the study by measurement of posterior bladder wall through

either by transrectal or by transvaginal ultrasound also there.⁹ There are no significant difference in the thickness of the different parts of urinary bladder wall measurement shown by different studies.^{10,11}

The present study was done with the aim to standardize ultrasound estimated bladder weight as an additional routine test to assess the bladder outflow obstruction and to observe the post-surgical effect.

Materials and Methods

This study done was done on 55 patients with bladder outflow obstruction from December 2012 to May 2014. Patients with benign enlargement of prostate, stricture urethra and bladder neck hypertrophy were included. But the pediatric patient, the patient with neurogenic bladder and cystitis were excluded. Uroflowmetry, anterior bladder wall thickness and post-void residue were measured both before and after the operation.

Data were collected by observation, interview, review of records and documents. Then history,



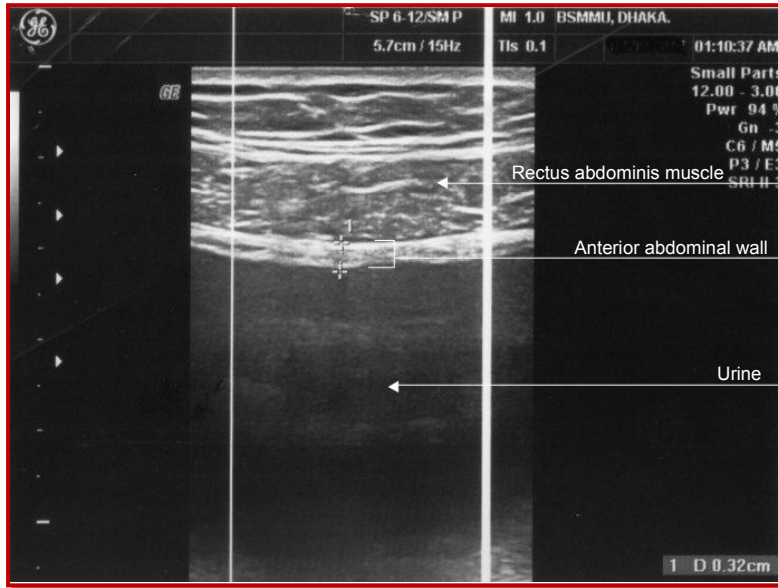


Figure 1: Ultrasonogram of the anterior wall of urinary bladder. Hyperechogenic adventitia, hypoechogenic detrusor and hyperechogenic mucosa with submucosa comprise bladder wall and it was measured as 0.31 cm in the photograph

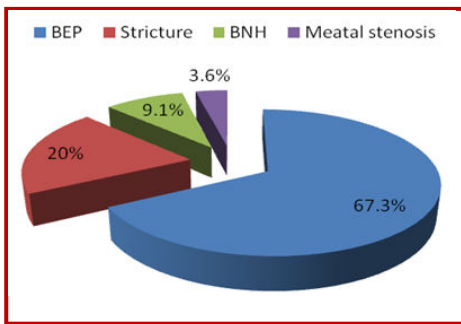


Figure 2: Distribution of diseases; BEP (benign enlargement of prostate, BNH (bladder neck hypertrophy)

physical examination and relevant investigations were done. Urinalysis and culture were done to exclude urinary tract infection; ultrasonography was done to see the maximum bladder capacity, post-void residual urine and bladder wall thickness and intravesical volume. Uroflowmetry was done to see the flow rate curve that gives differentiation between the static or dynamic obstruction. Transabdominal sonography was performed with the

patient in supine position. By ultrasonic image, a vertical section of the bladder was obtained in the midline of the lower abdomen above the pubic

symphysis using a 7.5 MHz. probe. The anterior bladder wall thickness was measured in the midline at 3 points approximately 1 cm. apart and the average value was recorded. Following that, the intravesical volume was measured by ultrasound and the bladder weight was calculated from the bladder wall thickness and intravesical volume, assuming that the bladder is a sphere (Figure 1).

Ultrasound estimated bladder weight was calculated by formula mentioned below

The urinary bladder resembles a sphere, and the internal diameter of the bladder was calculated from the volume of saline in the bladder (intravesical volume) from an outer diameter. The total bladder volume was calculated by subtracting the intravesical volume from the total vesical volume. Then, the spheric ultrasound estimated bladder weight was calculated by multiplying the volume of the bladder wall by the specific gravity.²

Results

The mean (± SD) age of the patients was 49 ± 15 years (age range: 21-73 years). About 29% were in the age group 51-60 years followed by 22% were in age group >60 years. Patients were either benign enlargement of the prostate (67.3%), urethral stricture 20%, or bladder neck hypertrophy (9.1%)(Figure 2).

The mean maximum urinary flow rate (Qmax) in pre-operative patients was 8.7 ± 3.6 mL/sec which was increased to 23.5 ± 6.5 mL/sec post-operatively. The lowest flow rate of urine was observed in case of stricture urethra pre-operatively which was increased after operation (Table I). Qmax was increased in all the cases after the operation.

The mean post-void residue in overall, benign enlargement of prostate and stricture urethra was ranged from 104-122 mL. Bladder neck hypertrophy showed higher amount post-void

Table I

Different parameters of urinary bladder ultrasonography in pre-operative and post-operative period

Group	Maximum urinary flow rate (Qmax) (mL/sec)		Post-void residue (mL)		Urinary bladder anterior wall thickness (cm)		Ultrasound estimated bladder weight (g)	
	Pre-operative	Post-operative	Pre-operative	Post-operative	Pre-operative	Post-operative	Pre-operative	Post-operative
Overall	8.7 ± 3.6	23.5 ± 6.5	112.0 ± 43.7	17.3 ± 10.6	0.5 ± 0.2	0.3 ± 0.1	117.8 ± 45.1	53.9 ± 10.8
Benign enlargement of prostate	10.2 ± 3.5	24.0 ± 6.0	107.2 ± 36.3	18.7 ± 10.6	0.5 ± 0.2	0.3 ± 0.3	120.8 ± 46.8	53.7 ± 10.8
Stricture urethra	5.4 ± 1.6	22.4 ± 8.3	104.0 ± 55.1	17.3 ± 11.5	0.5 ± 0.1	0.3 ± 0.0	113.4 ± 43.1	57.6 ± 9.4
Bladder neck hypertrophy	7.4 ± 1.2	22.8 ± 5.8	151.0 ± 58.3	9.8 ± 5.9	0.5 ± 0.1	0.3 ± 0.1	116.2 ± 50.7	48.8 ± 10.4

Data are mean ± SD

residue 151 mL. Post-operative findings show a significant reduction in all the cases (Table I). There was no change in the urinary bladder anterior wall thickness in all the cases. However, there was a significant decrease in the size after the operation.

The mean overall ultrasound estimated bladder weight in pre- and post-operative groups were 117.8 ± 45.1 and 53.9 ± 10.8 g respectively. The mean ultrasound estimated bladder weight of benign enlargement of the prostate for pre- and post-operative groups were 120.8 ± 46.8 and 54 ± 11 g respectively. In case of urethral stricture, it was 113 ± 43 and 58 ± 9 g for pre- and post-operative groups respectively (Table I).

Discussion

The present study shows that bladder outlet obstruction due to benign enlargement of prostate, stricture urethra, bladder neck hypertrophy or any other cause that decrease Qmax but increase the post-void residue. But after the relief of obstruction, this scenario reverses. The changes in Qmax and post-void residue that occur after intervention are statistically significant in the present study and the studies done by others.^{1,3,4}

Ultrasound estimated bladder weight increases in bladder outlet obstruction due to compensatory hypertrophy, increase in blood perfusion and fibrosis.¹ When outflow resistance decreases by treatment bladder wall thickness decreases with time. These changes are also statistically significant both in the present study and the studies done by the others.¹⁰⁻¹³

Parameters such as Qmax and post-void residue were used for the detection and follow-up of this group of patients. But for the Qmax study, a machine is required. The result depends on the patients' level of understanding and the amount of pre-void volume of urine. So, the result does not represent the real scenario. The post-void residue varies if a slight delay occurs in the examination or the patient forces the intake of a lot of water within a short period of time to see the maximum bladder capacity which is significant for interpreting the post-void residue.

The Ultrasound estimated bladder weight does not depend on the patient factor. It is also non-invasive, and easily available. So, this can be taken as a good parameter for detection and follow-up of patients with bladder outlet obstruction.

Conclusion

Ultrasound estimated bladder weight is promising

as an auxiliary technique for the diagnosis, prediction, monitoring and follow-up in therapeutic effects of bladder outflow obstruction.

References

1. Wani S, Hamid A, Kishore MG, Malviya V, Dwivedi US, Singh PB. Color doppler ultrasonography: Its role in detection and treatment outcome in infravesical obstruction. *Indian J Urol.* 2003; 19: 109-12.
2. Gilpin SA, Gosling JA, Barnard R J. Morphological and morphometric studies of the human obstructed, trabeculated urinary bladder. *Br J Urol.* 1985; 57: 525-29.
3. Akino H, Maekawa M, Nakai M, Shioyama R, Ishida H, Oyama N, Miwa Y, Yokoyama O. Ultrasound-estimated bladder weight predicts risk of surgery for benign prostatic hyperplasia in men using alpha-adrenoceptor blocker for LUTS. *Urology* 2008; 72: 817-20.
4. Paul DK, Bora V, Shukla RC, Dwivedi US, Singh PB. Ultrasound estimated bladder weight: Its role to detect and follow-up of bladder outflow obstruction. *Indian J Urol.* 2000; 16: 118-21.
5. Kojima M, Inui E, Ochiai A, Naya Y, Ukimura O, Watanabe H. Ultrasonic estimation of bladder weight as a measure of bladder hypertrophy in men with infravesical obstruction: A preliminary report. *Urology* 1996; 47: 942-47.
6. Housami F, Drake M, Abrams P. The use of ultrasound-estimated bladder weight in diagnosing bladder outlet obstruction and detrusor overactivity in men with lower urinary tract symptoms. *Indian J Urol.* 2009; 25: 105-09.
7. Oelke M, Wijkstra H. Ultrasound detrusor wall thickness measurements to diagnose bladder outlet obstruction in men. *Urologica* 2006; 16: 343-52.
8. Oelke M, Hofner K, Jonas U, Ubbink D, Rosette JDL, Wijkstra H. Ultrasound measurement of detrusor wall thickness in healthy adult. *Neurourol Urodyn.* 2006; 25: 308-17.
9. Kojima M, Inui E, Ochiai A, Naya Y, Ukimura O, Watanabe H. Noninvasive quantitative estimation of infravesical obstruction using ultrasonic measurement of bladder weight. *J Urol.* 1997; 157: 476-79.
10. Manieri C, Carter SS, Romano G, Trucchi A, Valenti M, Tubaro A. The diagnosis of bladder outlet obstruction in men by ultrasound measurement of bladder wall thickness. *J Urol.* 1998; 159: 761-65.
11. Oelke M, Hofner K, Jonas U, Ubbink D, de la RJ, Wijkstra H. Ultrasound measurement of detrusor wall thickness in healthy adults. *Neurourol Urodyn.* 2006; 25: 308-17.
12. Kojima M, Inui E, Ochiai A, Naya Y, Ukimura O,

- Watanabe H. Ultrasonic estimation of bladder weight as a measure of bladder hypertrophy in men with infravesical obstruction: A preliminary report. *Urology* 1996; 47: 942-47.
13. Kuzmic AC, Brkljacic B, Ivankovic D. Sonographic measurement of detrusor muscle thickness in healthy children. *Pediatr Nephrol.* 2001; 16: 1122-25.
-