

# Vascularized dorsal dartos flap to prevent fistula in tubularized incised plate urethroplasty for primary distal and mid shaft hypospadias

A. K. M. Zahid Hossain, Gazi Zahirul Hasan, Susankar Kumar Mondal, Md. Nooruzzaman, A. M. Shahinoor and Dinesh Prasad Koirala

## Article Info

Department of Pediatric Surgery, Bangabandhu Sheikh Mujib Medical University, Shahbag, Dhaka, Bangladesh

BSMMU J 2016; 9: 88-91

### For Correspondence:

A. K. M. Zahid Hossain  
drzahidps@gmail.com

Received: 12 February 2016

Accepted: 23 June 2016

Available Online: 18 August 2016

ISSN: 2074-2908

DOI: 10.3329/bsmmuj.v9i2.29047

### Available at:

www.banglajol.info

A Journal of Bangabandhu Sheikh Mujib Medical University, Dhaka, Bangladesh

## Abstract

The aim of the present study was to evaluate the importance of neourethral covering using vascularized dorsal flap for preventing fistula in tubularized incised plate (TIP) urethroplasty. The study included children with distal (n=44) and mid shaft (n=8) hypospadias. TIP urethroplasty was done followed by reconstruction of new surrounding urethral tissue. A longitudinal dartos flap was harvested from excessive dorsal preputial and penile hypospadiac skin and transposed to ventral side by a buttonhole maneuver. It was sutured to the glans wings and the neomeatus and to the corpora cavernosa over the neourethra. Thus, the new urethra was completely covered with well-vascularized subcutaneous tissue. After a mean follow-up of 18 months, the result was encouraging with no fistula or urethral stenosis, except 2 of the mid penile hypospadias. All patients had good functional and cosmetic results with straight penis and vertical slit shaped meatus at the tip of the penis. The 2 patients developed tiny fistula, which were closed spontaneously after meatal dilatation. In conclusion, urethral covering should be part of TIP urethroplasty. A dorsal well-vascularized dartos flap, button holed ventrally is a good choice for preventing fistula for distal and mid shaft hypospadias.

## Introduction

With the introduction of tubularized incised plate urethroplasty (TIPU) or Snodgrass procedure in 1994, it has gained wide spread acceptance and popularity because of its versatility, low complication rate, good cosmetic results, easy to do and reliability in creating a vertically oriented meatus as in a normal circumcised penis. The tubularized incised plate urethroplasty repair is the procedure of choice for distal and mid shaft hypospadias.<sup>1,4</sup> Post-operatively urethrocutaneous fistula is the most common complication that ranged from 2-20%.<sup>5,7</sup> Urethrocutaneous fistula usually result following loss of viability of tissues involved in hypospadias repair.<sup>8</sup> Necrosis of over lying skin and subcutaneous tissue leaves the neo-urethra and its scar exposed, thus resulting in either its total or partial disruption or fistula formation. Also, excessive back pressure due to distal obstruction can disrupt and reinforce repairs of good integrity for disruption. To decrease fistula rate, an additional tissue cover after neo-urethra, reconstruction have been described by many surgeons using transverse onlay dorsal subcutaneous flap, de-epithelialized skin flaps,<sup>2</sup> dorsal dartos flap,<sup>10</sup> ventral based dartos flap,<sup>11,12</sup> scrotal dartos,<sup>13</sup> spongioplasty,<sup>14</sup> or

tunica vaginalis flap

There is still no consensus over the ideal interposition tissue in TIPU. In the present study, the experience using a vascularized dartos flap after TIPU for distal and mid shaft hypospadias repair has been presented.

## Materials and Methods

Patients of primary distal (n=44) and mid (n=8) penile hypospadias (aged 2-10 years; mean 4.5 years) underwent repair using TIPU procedure from January 2012 to July 2015. All patients have a well developed urethral plate. The technique used was the TIPU, followed by neourethral covering by vascularized dorsal dartos flap.

### Surgical technique

A stay suture is place through the glans penis for traction. The penis is degloved with U shaped incision extending along the edges of the urethral plate to healthy skin 2 mm proximal to the meatus and the extended circumferentially around the corona (Figure 1). Penile degloving was done when required up to the root of the penis creating a plane at the level of Buck's



fascia. Gitte's test was carried out to evaluate the chordee after penile degloving when needed. Orthoplasty was performed if needed by mid line dorsal tunica albuginea placcation. Penile degloving includes creating the well-vascularized subcutaneous dartos tissue flap. A longitudinal dartos flap was harvested from preputial and dorsal penile shaft skin preserving blood supply (Figure 1), and then transposed to the ventral side by a buttonhole maneuver. Two parallel longitudinal incisions separated the distal urethral plate from glans wings. The glans wings were mobilized laterally. At this stage the urethral plate was a narrow epithelial strip running from the meatus to the glanular tip. The urethral plate was widened by a midline incision along its entire length, extending deeply to near the corpora cavernosa.

The urethral plate was then tubularized over a 7 or 8 French stent without tension in two-layer sub-epithelial running and interrupted 6/0 polygalactin suture. Distal urethral plate was not sutured too snugly to prevent meatal stenosis. Usually only 1 or 2 sutures beyond the mid glans level of the plate were needed, leaving the neo-meatus oval in configuration. The neourethra was covered with the harvested vascularized dartos flap. The neo-meatus was widely fashioned and everted to prevent subsequent meatal stenosis (Figure 1). Thus, all sutured lines were covered with well-vascularized onlay dorsal dartos flap that support the neourethra like spongiosal tissue. The glanular wings, mucosal collar and ventral shaft skin were then closed in

midline. Caution was needed during penile skin reconstruction to avoid damaging the blood supply of the dartos flap. The urethral stent was secured to the glans with 5/0 polypropylene suture. The dressing was applied with the penis in upright position to minimize post-operative bleeding and edema and changed after 3<sup>rd</sup> or 4<sup>th</sup> postoperative day. The urethral stent was kept in place for 7-10 days after surgery.

#### Treatment

Oral antibiotics and oxybutynin were used to prevent post-operative infection and bladder spasm. The follow-up was scheduled weekly for first month, then consecutive three months after surgery. The neourethra was calibrated monthly for first year and 3 monthly for the next year. The patients with meatal stenosis were treated by periodic dilatation. During follow-up, physical examination of the penis and neo-meatus were done. Voiding patterns (stream force and caliber) were assessed. Follow-up varied from 6 to 36 months with a mean of 18 months and the outcomes was evaluated for fistula formation and urethral stricture.

#### Results

After a mean follow up of 18 months (6-36 months), the result was successful with no fistula in all 52 children, except 2 of the mid-penile hypospadias in which the tiny fistula was formed. However both the fistulas closed spontaneously after meatal

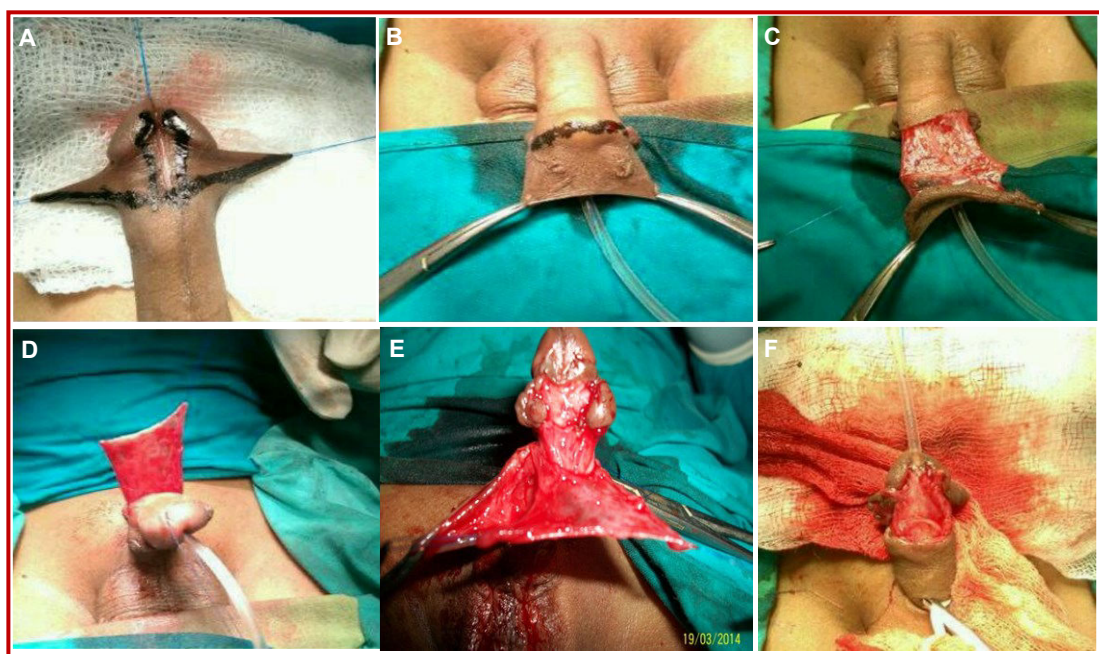


Figure 1: Surgical technique in steps

A) A transverse skin incision is made proximal to corona below hypospadiac preputial penile skin; B) De-epithelization of dorsal excessive penile skin . and harvesting in axial course of blood vessel; C) A redundant dorsal dartos flap is created. Vascularilazation is completely preserved; D) The flap is transposed ventrally by a button hole maneuver, followed by standard TIP urethroplasty; E) The flap is fixed to the glans around the neomatus and to the corporeal bodies up to normally developed urethra; F) Reconstruction of the glans and the penile body skin; aspect at the end of surgery

dilatation. All patients with straight penis and vertical slit shaped meatus with cosmetically normal looking circumcised penis (Figure 1). Meatal stenosis occurred in 4 patients (7%). These were treated successfully by periodic meatal dilatation during 3 months period. The neourethra was calibrated at 1, 2 and 3 months post-operatively.

---

## Discussion

Urethrocutaneous fistula is the most common complication. To prevent urethrocutaneous fistula interposition of well-vascularized tissue between the penile skin and neourethra is essential. Different techniques and tissues have been described to avoid this complication. Retik and Borer described covering the neourethra with asymmetrical rotational subcutaneous dartos tissue flap harvested from the dorsal preputial and shaft skin.<sup>15</sup> Yerkes et al<sup>16</sup> used a Y to I wrap of spongiosum for neourethral reinforcement and Shenberg et al<sup>8</sup> reported using TIP urethroplasty with on lateral based de-epithelialized flap in previous hypospadias families.

Asymmetric flaps harvested from subcutaneous tissue and rotated over the neourethra do not provide ideal support and can cause penile rotation. The spongiosal tissue provides good anatomical coverage of the neourethra but its use is limited, especially in midshaft hypospadias. Ventral based dartos flaps also have used for the urethral covering.<sup>11</sup> Ventral skin can be poorly developed, so it is not available for creating sufficient ventral dartos flap always. Tunica vaginalis flap has been reported as a reinforcing layer of the neo-urethra,<sup>17</sup> although the fistula rate was zero. However, it is more suitable for proximal hypospadias and it needs more dissection in the scrotum. Snodgrass<sup>11</sup> also used a dorsal dartos pedicle flap obtained from the dorsal prepuce, buttonholed and transposed to the ventrum for additional coverage of the neourethra.

Independently from Snodgrass, we started to create onlay dorsal dartos flap to minimize the urethrocutaneous fistula rate after TIP urethroplasty. Flaps harvested from dorsal hypospadias penile and preputial skin are abundant, well vascularized and follow the axial course of blood vessels is the best possible way.<sup>12</sup> The crucial point of the technique involves harvesting the flap. De-epithelialization starts at the dorsal region of normal penile skin below the hypospadias prepuce. Here, dissection of subcutaneous tissue is easy and can be continued distally up to the border between the outer and inner preputial layer, to create a redundant dorsal dartos flap with completely preserved vasculariza-

tion. De-epithelialization from distal to proximal is more difficult because of frequent preputial deformities (dorsal hump, dog-eyes, etc) and could result in a thin and reduced flap with a damaged blood supply.<sup>13</sup> The flap is transposed ventrally by a buttonhole maneuver and fixed to the glans wings around the neomeatus and laterally to the corpora cavernosa up to the normally developed urethra, providing complete and symmetrical covering to the neourethra. Redundancy and vascularization make it useful for distal, mid shaft hypospadias repair. This technique had a very good outcome in the patients compared with those of others results.<sup>6-9</sup>

The transposed flap completely covers the neourethra, giving additional support in fistula prevention. The flap's redundancy, excellent vascularity and always sufficient length make it very useful for distal and mid shaft hypospadias repairs with a well-developed urethral plate. Also penile rotation is avoided because of the longitudinal orientation of the flap. Use of this flap in our patients achieved very good outcome, compare with other reports.<sup>6-9</sup>

Deep dissection of the glans wings is recommended to obtain their good mobility for later closure. Incisions should be directly vertical to prevent injury to the penile arteries which run in to glans latero ventrally. There was no case in which covering of the urethra and glans closure was not possible.

The meatal stenosis is reported in this series (7%) is comparable to other series using Snodgrass technique for hypospadias repair that has been reported to be ranging from 3 to 17%.<sup>3-5,12,13</sup> Fashioning of a wide neo-meatus is the key for prevention of meatal stenosis.

Regular calibration of the meatus and urethra is important for early discovery of stenosis and dilatation in proper time.

---

## Conclusion

The neourethra covering should be used as part of the TIP urethroplasty for fistula prevention. A longitudinal well-vascularized dartos flap, harvested dorsally and button holed at its base for ventral transposition, represents a good choice for preventing fistula. Redundancy and excellent vascularization of the flap is essential and depends on the technique of its harvesting.

---

## Ethical Issue

A detailed explanation of the procedure was given by

the operating surgeon, and all guardians signed informed consent forms before undergoing the procedure.

---

## References

---

1. Snodgrass W. Tubularized incised plate urethroplasty for distal penile hypospadias. *J Urol.* 1994; 151: 464-65.
  2. Snodgrass WTF, Lorenzo A. Tubularized incised plate urethroplasty for proximal hypospadias. *BJU Int.* 2002; 89: 90-93.
  3. Snodgrass WT. Snodgrass technique for hypospadias repair. *BJU Int.* 2005; 95: 683.
  4. Snodgrass W, Koyle M, Manzoni G, Hurwitz R, Caldamone A, Erlich R. Tubularized incised plate hypospadias repair: Results of multicentre experience. *J Urol.* 1996; 156: 839-41.
  5. EL-Sherbing MT, Hafez AT, Dawabar MS, Shomba A, Borzeed MA. Comprehensive analysis of tubularized incised plate urethroplasty in primary reoperative hypospadias. *BJU Int.* 2004; 93: 1057-61.
  6. Borer JG, Bauer SB, Peters CA, Diamond DA, Atala A, Cilento BG, et al. Tubularized incised plate urethroplasty: Expanded use in primary and repeat surgery for hypospadias. *J Urol.* 2001; 165: 581-85.
  7. Cownor KM, Kiely EA. Lesson learned using Snodgrass hypospadias repair. *Int J Med Sci.* 2006; 175: 37-39.
  8. Singh RB, Pavithnam NM. Partially de epithelialized preputial flap (triangular soft tissue flap: An aid to correct urethrocutaneous fistula. *Paediatr Surg Int.* 2003; 19: 551-53.
  9. Ross JH, Kay R. Use of a de-epithelialized local skin flap in hypospadias repair accomplished by tubularized of the incised urethral plate. *Urology* 1997; 50: 110-12.
  10. Djordjevic ML, Provic SV, Slakovic Z, Djakovic N. Longitudinal dorsal dartos flap for prevention of fistula after Snodgrass hypospadias procedure. *Eur Urol.* 2006; 50: 53-57.
  11. Soygun T, Arıkan N, Zumurutbas AE, Culphirar O. Snodgrass hypospadias repair with ventral based dartos flap in combination with mucosal collar. *Eur Urol.* 2005; 47: 879.
  12. Furness 3<sup>rd</sup> PD, Hutcheson J. Successful hypospadias repair with ventral based dartos for urethral coverage. *J Urol.* 2003; 169: 1825-27.
  13. Hayashi Y, Kojima Y, Kurokawars, et al. Serodartos flap for prevention of urethrocutaneous fistula on hypospadias urethroplasty. *Int J Urol.* 2005; 12: 280-83.
  14. Bhat A, Sorbharwal K, Bhat M, Saran R. Outcome of tubularized incised plate urethroplasty with spongioplasty alone as additional tissue coverage: A prospective study. *Indian J Urol.* 2014; 30: 4
  15. Retik AB, Borer JC. Primary and reoperative hypospadias repair with Snodgrass technique. *World J Urol.* 1998; 16: 186-91.
  16. Yerkes EB, Adams MC, Miller DA, Pope JC 4<sup>th</sup>, Rink RC, Brock JW 3<sup>rd</sup>. Y-to-I wrap: Use of the distal spongiosum for hypospadias repair. *J Urol.* 2000; 163: 1536-38.
  17. Snow BW, Cartwright PC, Ungeb K. Tunical vaginalis blanket wrap TP prevent urethrocutaneous fistula. *J Urol.* 1995; 153: 472-73.
  18. Miruslav L, Perovic VS, Varkadinorvic MV. Dorsal datos flap for preventing fistula in the Snodgrass hypospadias repair. *BJU Int.* 2005; 95: 1303-09.
-