

## Dorsolateral onlay urethroplasty for long segment anterior urethral stricture: outcome of a new technique

Habib AKMK, Alam AKMK, Amanullah ATM, Rahman H, Hossain AKMS,  
Salam MA, Kibria SAMG

*Department of Urology, Bangabandhu Sheikh Mujib Medical University (BSMMU), Dhaka*

### Abstract

Conventional dorsal onlay urethroplasty requires circumferential mobilization of the urethra which might cause ischemia of the urethra. The present study was conducted to determine the feasibility and short term outcomes of applying dorsolateral free graft to treat anterior urethral stricture by unilateral urethral mobilization approach. This hospital based prospective interventional study was conducted in the Department of Urology, Bangabandhu Sheikh Mujib Medical University, Dhaka, from July, 2009 to December, 2010. Total 30 patients with long-segment anterior urethral strictures were selected and treated by a dorsolateral free buccal mucosa graft. The test statistics used to analyse the data were Chi-square ( $\chi^2$ ) test and Student's t-Test. For all analytical tests, the level of significance was set at 0.05 and  $p < 0.05$  was considered significant. After 6 months follow up results were prepared. Three (10%) patients developed wound infection. One (3.3%) patient developed urethrocutaneous fistula and one (3.3%) patient had chordee. Wound infections were treated conservatively. Twenty eight (93.3%) patients out of 30 had subjective improvement of urine flow after operation. All of these patients had postoperative Qmax  $> 10$  ml/sec. Postoperative Retrograde Urethrogram (RGU) of 28(93.3%) patients was free of stricture and 2(6.7%) patients showed stricture who had postoperative Qmax  $< 10$  ml/sec. Overall success rate was 93.3% at 3 to 12 months follow up. Unilateral urethral mobilization approach for dorsolateral free graft urethroplasty is feasible for long segment anterior urethral strictures with good short term success.

### Introduction

Urethral stricture is one of the oldest known urological diseases and remains a common problem with high morbidity. The conventional approach for management of long segment anterior urethral stricture is a two-stage Johanson repair along with the use of free grafts if required<sup>1-3</sup>. One-stage techniques are either dorsal onlay<sup>4</sup>, ventral sagittal urethrotomy with inlay patch<sup>5,6</sup> or dorsal onlay with separate grafting for the distal-most urethra by graft insertion through the meatus<sup>7</sup>.

A circumferential dissection of the whole anterior urethra risks the vascularity of the urethra, which may be more important if the meatus is also involved with disease and the distal-most urethra is extensively dissected. The Barbagli procedure with circumferential mobilization of the urethra for dorsal onlay patch has a success rate of 99% and 66% in the short- and long-term, respectively<sup>8</sup>.

Barbagli also described the lateral onlay procedure with results similar to dorsal and ventral onlay for bulbar urethral strictures<sup>9</sup>. In the pendulous urethra, ventral and lateral onlay grafts have the risk of diverticulum formation.

Asopa's procedure of inlay patch by ventrally incising the urethra is another option for anterior urethral strictures<sup>5</sup>. It preserves the lateral vascularity of the urethra. However, it has potential drawbacks. A wider graft may be difficult to be placed using this approach and the graft may likely get folded.

Recently, Singh et al<sup>10</sup> have shown the superiority of the Asopa procedure over the Barbagli procedure in terms of success and complications. This also supports the approach of restricting the mobilization of the urethra from its bed in patch urethroplasties for long segment anterior urethral strictures.

To maintain the urethral vascularity on one side of the urethra while keeping the graft in a

dorsolateral onlay fashion, the policy of limited urethral mobilization, i.e., from ventral midline to beyond dorsal midline can be adopted. In this procedure, the graft is eccentric toward one side on the ventral tunica of the corpora. Technically, it is as easy as the Barbagli procedure. It also preserves the one-sided bulbar artery in addition to maintaining the native lateral vascularity at the meatus and the distal urethra. By using this approach, at least the one-sided bulbospongiosus muscle remains intact along with ipsilateral vascularity to the urethra.

Using this approach, short-term results for long segment anterior urethral strictures was analyzed to draw a conclusion.

### Materials and Methods

This study was conducted in the department of Urology, Bangabandhu Sheikh Mujib Medical University from October, 2009 to November, 2010. Thirty male patients undergoing dorsolateral buccal mucosal graft onlay urethroplasty by a unilateral urethral mobilization approach for long segment anterior urethral strictures in Bangabandhu Sheikh Mujib Medical University and a Private hospital (Comfort Nursing Home Pvt. Ltd.) in Dhaka city was included in the study. Patients with posterior urethral stricture, complete blockade of urethral lumen and features of acute urethritis were excluded.

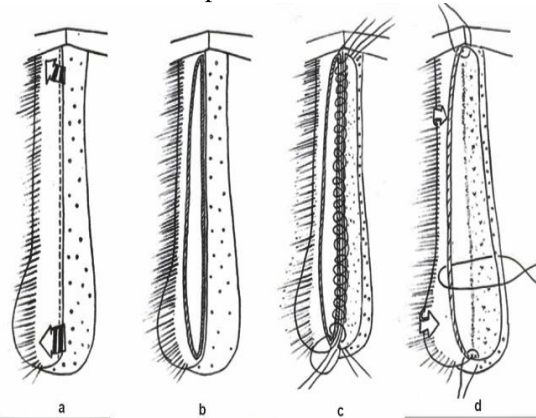
Urethroplasty was started by a midline perineal approach, with the patient in lithotomy position. The penis was everted through the perineal incision. The urethra was mobilized from the midline on the ventral aspect to beyond the midline on the dorsal aspect.

Fascia and vascular attachments on the other side of the urethra were left intact. The urethra was incised open in the midline dorsally. Buccal mucosal grafts (from one or both the cheeks) of required length and width were taken. The length of the area to be grafted was measured by the incised length of the urethra. Proximally, the graft was sutured to the open urethra by a few interrupted sutures at the apex and at the medial urethral margin. Then, one edge of the graft was sutured to the medial urethral margin, which was in place and fixed to the corpora. (Fig. 1)

This was performed by continuous suturing using 4/0 Vicryl until the distal apex. At the distal apex, few interrupted sutures were taken. Quilting sutures were applied to keep the graft

opposed to the tunica and to prevent buckling of the graft. A 14 Fr Foleys catheter was kept in the urethra. The other margin of the graft was sutured to the lateral margin of the urethra and the tunica of corpora.

These three tissues were taken together while approximating the lateral edge, thereby anchoring both graft and urethral margin to the tunica albuginea. During the entire procedure, care was taken to prevent stretching of the graft, which may result in chordee. A corrugated rubber drain was kept for 48 hours. The bulbospongiosus muscle was approximated in the midline. Subcutaneous tissues and skin were closed with interrupted absorbable sutures.



(a) Limited urethral mobilization from midline ventrally to beyond midline dorsally, (b) urethral incision at dorsal midline (12 O'clock), (c) graft sutured to medial (right) urethral margin, and (d) graft sutured to lateral (left) urethral margin.

**Fig.1** Dorsolateral onlay urethroplasty procedure

Each patient was followed up 3 months after operation with (1) history, (2) urine for routine microscopic examination and culture, (3) uroflowmetry, and (4) retrograde urethrogram. Further follow up was done at 6 months with (1) history, (2) urine for routine microscopic examination and culture, and (3) uroflowmetry. Retrograde urethrogram was performed when peak flow rate ( $Q_{max}$ ) was less than 10 ml/ sec.

*The results were classified into two outcomes -* Success was defined as a maximum flow rate of  $\geq 10$  ml/sec. and normal urethral imaging in retrograde urethrogram.

Failure was defined as the presence of obstructive urinary tract symptoms,  $Q_{max} < 10$  ml/sec., stricture diagnosed on retrograde urethrogram and the need for any postoperative urethral intervention, including dilatation, internal urethrotomy, or urethroplasty.

Data were processed and analyzed using SPSS (Statistical Package for Social Sciences)

software. The test statistics used to analyze the data were descriptive statistics, Chi-square ( $\chi^2$ ) test, and Student's t-Test. For all analytical tests, the level of significance was set at 0.05 and  $p < 0.05$  was considered significant.

## Results

Mean length of stricture was 34.5 mm and standard deviation 4.79. Nineteen patients (63.3%) was in 31- 40 mm group and 11 patients (36.7%) was in 21- 30 mm group. Most of the strictures (43.3%) were present in bulbar urethra. Nine (30%) patients had in both bulbar and penile urethra and eight (26.7%) patients had in penile urethra. During post operative follow up three (10%) patients developed wound infection. One (3.3%) patient developed urethrocutaneous fistula and one (3.3%) patient had chordee. Mean preoperative Qmax was 4.95 ml/sec and mean postoperative Qmax was 15.62 ml/sec. Paired t test was done and showed the difference was statistically significant (p value was  $< 0.001$ ).

**Table I:** Comparison between preoperative and postoperative uroflowmetry.

Duration of follow up	No. of patients	Preoperative uroflow (mean Qmax ml/sec)	Postoperative uroflow (mean Qmax ml/sec)	P value
3 months	30	4.95	15.97	
6 months	30	4.95	15.45	
Total	30	4.95	15.62	$< .001$

Improvement of urine flow after operation and appearance of postoperative RGU was compared with that before operation. Chi-Square Test was done. Twenty eight (93.3%) patients out of thirty had subjective improvement of urine flow after operation and all of these patients had postoperative Qmax  $> 10$  ml/sec. Postoperative RGU of twenty eight (93.3%) patients were free of stricture. Two (6.7%) patients showed stricture in postoperative RGU in whom urine flow was not improved (Qmax  $< 10$  ml/sec). Analysis showed the outcome was statistically significant (P value was  $< 0.001$ )

**Table II:** Cross table between improvement of flow and postoperative RGU

Subjective improvement of uroflow after operation	Post op RGU-normal	Post op RGU-stricture	Total	P value
Flow not improved	0	2	2(6.7%)	$< .001$
Flow improved	28	0	28(93.3%)	

All patients (11) of stricture length 21 – 30 mm had successful outcome. But among patients of stricture length 31- 40 mm, 17 (89.5%) out of 19 had successful outcome. It was found that longer

segment strictures had higher failure rate (10.5%). Strictures of 21-30 mm length showed 100% success rate.

**Table III:** Success rate with relation to length of stricture.

Length of stricture(mm)	No. of patients	Success	Failure
21- 30	11	11 (100%)	0 (0%)
31 - 40	19	17 (89.5%)	02 (10.5%)
Total	30	28 (93.3%)	02 (6.7%)

## Discussion

For single-stage repair of long segment anterior urethral strictures, dorsal patch urethroplasties are the mainstay of treatment. To avoid the extensive circumferential mobilization of the urethra a dorsolateral patch by one-sided urethral mobilization may be a good alternative for dorsal patch urethroplasty. To maintain the urethral vascularity on one side of the urethra the policy of limited urethral mobilization was adopted i.e. from ventral midline to beyond dorsal midline.

Mean length of stricture was 34.5 mm. Most of the stricture was in 31-40 mm (Longer segment) group. In the study by Shah et al,<sup>11</sup> the length of stricture was 2.5-5 cm in seventeen patients, 5-7.5 cm in twelve patients, 7.5-10 cm in eight patients and 10-12 cm in three patients. Singh et al<sup>7</sup> showed mean length of stricture 8.6 cm (Range 3.5-14 cm). In the study by Songra et al<sup>12</sup> mean length of stricture was 8.06cm (Range 5-18 cm). Average length of stricture was higher in other studies because we are not yet confident to treat such long strictures by single stage procedure which is conventionally treated by Johanson's staged operation.

Regarding locations of stricture, it was found that thirteen patients (43.3%) had in bulbar urethra. Nine (30%) patient had in both bulbar and penile urethra and eight (26.7%) patients had in penile urethra. In the study by Singh et al<sup>7</sup> the distribution of stricture among seventeen patients showed that one patient had stricture in bulbar urethra, eight patients had in penile urethra and eight patients had in both bulbar and penile urethra. Distribution of location of stricture was not significantly different.

In this study each patient was followed up three months after operation with clinical evaluation, urine analysis, uroflowmetry, retrograde and voiding urethrogram (Retrograde Urethrogram & Micturaing Cystourethrogram). Further follow up was done at 6 months. Shah et al<sup>11</sup> in their study had follow up range of 2-6 years (Mean 4 years). Their follow up protocol included clinical

evaluation, uroflowmetry at 3, 6, 12, 18 month and thereafter when needed. In the study by Songra et al,<sup>12</sup> follow up was continued for 8 – 10 months with uroflowmetry, retrograde and voiding urethrogram. Singh et al<sup>7</sup> had follow up range, 12-30 months (Mean 19.8 months). Their follow up protocol included clinical evaluation, uroflowmetry, retrograde and voiding urethrogram.

During post operative follow up three (10%) patients developed wound infection. One (3.3%) patient developed Urethrocutaneous fistula and one (3.3%) patient had chordee. Wound infections were treated conservatively. Fistula also healed with conservative treatment. The chordee was moderate and was planned for surgical correction afterwards. In the study by Shah et al<sup>11</sup> among 40 patients one patient (2.5%) required OIU 9 months following surgery. One patient (2.5%) died due to pulmonary embolism in immediate post-operative period. Wound infection was encountered in 3 patients (7.5%) in early postoperative period. Post-void dribbling or fistula was encountered in none. Songra et al<sup>12</sup> showed that six patients (42.8%) had wound infection that was managed conservatively and 3 patients had leak at repair site which was also managed conservatively. Singh et al<sup>7</sup> in their study showed that one patient developed meatal stenosis and two patients developed superficial wound infection which was managed conservatively. Complications in this study were reasonable and comparable to other studies.

Mean preoperative Qmax was 4.95 ml/sec and mean postoperative Qmax was 15.62 ml/sec. In the study by Singh et al (2009) mean preoperative Qmax was 6.7 ml/sec (Range 3.8 – 9.5) and mean postoperative Qmax was 16.4 ml/sec (Range 8-21.2). This result was similar to other study.

So overall outcome was successful in 28 (93.3%) patients at 6 months follow up. In two patients urine flow did not improve satisfactorily and their Qmax increased but was <10ml/sec. The cause of failure may be due to complication (Infection) that happened in these patients or technical problem.

Shah et al<sup>11</sup> reported outcome was successful in 38 patients out of 40 (95%). Songra et al.<sup>12</sup> (2005) reported overall success rate was 85.71% and only 2 patients had restructure out of 14 patients. Iselin & Webster<sup>13</sup> in their series of 29 men who underwent dorsal onlay graft urethroplasty reported a high early success rate

of 97% at a median follow-up of 19 months. Study on dorsolateral onlay graft urethroplasty by Singh et al<sup>7</sup> shows short-term success rate with a median follow-up of 19 months (range: 12-30 months) was 88% and a satisfactory result rate was 94%. Study on One-sided anterior urethroplasty: a new dorsal onlay graft technique by Kulkarni et al<sup>14</sup> shows study on 24 patients with mean follow up of 22 months shows 22(92%) had a successful outcome and two (8%) were failures. Though the follow up period was shorter in this study, the final outcome and success rate was almost similar to other international published studies.

Singh et al<sup>10</sup> reported a success rate of 86.0% with dorsal onlay mucosal grafts. In a comparative analysis by Barbagli et al<sup>8</sup> 63 patients and a mean follow-up at 55 months, buccal mucosal graft proved superior to flaps with respective success rates of up to 80% for mucosal grafts and 67% for flaps.

The results of oral mucosal graft urethroplasty should ultimately be evaluated by the long-term outcome. There is mounting evidence to suggest that oral mucosa is emerging as the tissue of choice for urethral substitution, and this tissue is also replacing skin graft and flaps for salvage urethroplasty in a variety of complex and recurrent urethral strictures. Reconstructive urologists and pediatric surgeons in developing countries should therefore be familiar with this versatile technique for urethral reconstruction

Considering the findings of the study, we can conclude that dorsolateral onlay urethroplasty by a unilateral urethral mobilization approach is an effective method of treatment and is a satisfactory technique for the treatment of long segment anterior urethral strictures. The morbidity and complications are low and outcomes are excellent.

## References

1. Al-Ali M, Al-Hajaj R. Johanson's staged urethroplasty revisited in the salvage treatment of 68 complex urethral stricture patients: Presentation of total urethroplasty. *Eur Urol* 2001; 39: 268–71.
2. Schreiter F. Two-stage urethroplasty. *Urologe A* 1998; 37: 42–50.
3. Bouchot O, Cassé C, Bochereau G, Prunet D, Buzelin JM. Urethroplasty in 2 stages using skin grafts. *Prog Urol*. 1995; 5: 551–5.
4. Barbagli G, Palminteri E, Guazzoni G, Cavalcanti A. Bulbar urethroplasty using the dorsal approach: Current techniques. *Int Braz J Urol* 2003;29:155–61.

5. Asopa HS, Garg M, Singhal GG, Singh L, Asopa J, Nischal A. Dorsal free graft urethroplasty for urethral stricture by ventral sagittal urethrotomy approach. *Urology* 2001; 58: 657–9.
  6. Pisapati VL, Paturi S, Bethu S, Jada S, Chilumu R, Devraj R, et al. Dorsal buccal mucosal graft urethroplasty for anterior urethral stricture by asopa technique. *Eur Urol* 2008; 54: 314-9.
  7. Singh BP, Pathak HR, Andankar MG. Dorsolateral onlay urethroplasty for anterior urethral stricture by a unilateral urethral mobilization approach. *Indian J Urol* 2009; 25: 211-4.
  8. Barbagli G, Morgia G, Lazzeri M. Dorsal onlay skin graft bulbar urethroplasty: Long-term follow-up. *Eur Urol* 2008; 53: 628–33.
  9. Barbagli G, Palminteri E, Guazzoni G, Montorsi F, Turini D, Lazzeri M. Bulbar urethroplasty using buccal mucosa grafts placed on the ventral, dorsal or lateral surface of the urethra: Are results affected by the surgical technique? *J Urol* 2005; 174: 955–7.
  10. Singh PB, Das SK, Kumar A, Sharma GK, Pandey AK, Swain S et al. Dorsal onlay lingual mucosal graft urethroplasty: Comparison of two techniques. *Int J Urol* 2008; 15: 1002–5.
  11. Shah SA, Ranka P, Choudhary R, Dhawan M, Vishnagara M. Buccal mucosal dorsal substitution urethroplasty in recurrent anterior urethral stricture. *Indian J Urol* 2003; 19: 152-6.
  12. Songra MC, Kerketta A, Dua R. Single stage substitution urethroplasty using buccal mucosal graft in management of stricture urethra. *Indian J Urol* 2005; 23(2): 115-9.
  13. Iselin CE, Webster GD. Dorsal onlay graft urethroplasty for repair of bulbar urethral stricture. *J Urol* 1999; 161: 815-818.
  14. Kulkarni BS, Barbagli G, Sansalone S, Lazzeri M. One-sided anterior urethroplasty: a new dorsal onlay graft technique. *BJUI* 2009; 1-6.
-