

A comparative study between fine needle aspiration cytology findings and histopathological report of major salivary gland neoplasm in a tertiary hospital of Bangladesh

Huq AHMZ¹, Aktaruzzaman M², Habib MA³, Islam MS⁴, Amin ASA¹

¹Deptt. of ENT, Bangabandhu Sheikh Mujib Medical University, Dhaka, ²Upazilla Health Complex, Hazigong, Chandpur, ³Deptt. of ENT, Rangpur Medical College Hospital, Rangpur, ⁴Upazilla Health Complex, Nawabgong, Dhaka. Email: zhuq_sach@yahoo.com

Abstract

Salivary gland tumours are relatively uncommon and most of the tumours arise from parotid gland. Fine needle aspiration cytology (FNAC) is advised preoperatively as diagnostic tool but sometimes found to show both false positive and false negative results. This study was aimed to find out distribution of neoplasm of major salivary glands and also to explore the sensitivity and specificity of FNAC. The present cross sectional study was done in the Dept. of Otolaryngology Head and Neck Surgery, BSMMU from January 2007 to December 2008. A total number of 60 gender-matched patients with major salivary neoplasm, confirmed by FNAC, were recruited in the study. Operated salivary gland specimens were sent for histopathological examination, histopathological findings were compared. Overall male to female ratio was 1:1. Out of 60 cases, 47 (78.3%) patients had parotid and 13 (21.7%) patients submandibular gland neoplasm. Male to female ratio for parotid tumour was 1:1.1 and for submandibular 1.6:1. Mean age of the patients was 44.5 with range of 14-85 years. Of the total 60 cases 47 (78.3%) were benign and 13 (21.7%) malignant. Out of 47 parotid tumour 85.1% were benign and 14.9% malignant. Among the parotid tumour 97% were superficial lobe and 3.0% deep lobe. In case of submandibular gland 53.84% were benign and 46.15% tumour malignant. According to the sides of involvement, 25 (53.2%) cases of parotid neoplasm tumour were in the left and 22(46.8%) the right. In submandibular gland the distribution was 7 (53.8%) and 6 (46.16%) respectively. Statistically incidence of parotid tumour was significantly higher than submandibular tumour ($p<0.05$). Out of 60 cases in 56 (93.3%) preoperative FNAC and postoperative histopathological findings were same. There was 1.7% false positive and 5% were false negative results. Sensitivity, specificity of FNAC were 80% and 97.8% respectively. Positive predictive value was 92.3% and negative predictive 93.6% for FNAC. FNAC though cheap and safe but its diagnostic accuracy was 93.3%. Histopathological examination remained to be of value for diagnostic confirmation of major salivary gland neoplasm.

Introduction

Neoplasms that arise in the salivary glands are relatively rare, yet they represent a wide variety of both benign and malignant histologic subtypes. It constitutes about 10% of all head neck neoplasms which, however, is 3% of all neoplasms in the body¹. Incidence of salivary gland neoplasm in USA found to be about 3-4% of all neoplasm of the head and neck regions². Worldwide incidence of salivary gland neoplasm, however, reported to be between 0.4 to 13.5 cases per 100,000³.

Salivary gland tumours are mainly benign in nature, Carcinoma of the salivary gland also uncommon accounting for less than 1 percent of all head and neck malignant neoplasm. And among malignant cases mucoepidermoid carcinoma was the commonest (39.7%)⁴ by histopathological evaluation. Patients with benign salivary gland neoplasm reported to relatively younger compared to those with malignant cases; median age 51 vs 58 years. It was also demonstrated that tumours arise

from parotid gland is 75%, submandibular gland 16%, minor salivary gland 8% and sublingual gland 1% cases. Moreover, benign tumours found to be pleomorphic adenoma and mostly of parotid gland origin. On the contrary adenoid cystic was the most common type of malignant cases and originated from submandibular and minor salivary glands⁵. However, most benign tumours were pleomorphic adenoma, adenolymphoma and most malignant was mucoepidermoid carcinoma⁶.

Fine needle aspiration of salivary gland lesion may provide preoperative tissue diagnosis. Sismanis and colleague in 1981 reported, 74% overall accuracy rate based on a series of 51 fine needle aspirations. The advantages of fine needle aspiration include its safety, cost and speed⁷. Fine needle aspiration cytology (FNAC) is being increasingly used in the diagnosis of the salivary gland lesions. Cytopathological correlation available of which diagnostic accuracy was 87.5%. 3.12% false positive and 9.37% false negative reports. Thus fine

needle aspiration cytology is a useful diagnostic tool in evaluating neoplastic lesions of the salivary glands⁸.

For salivary gland neoplasm, agreement between histotype determination using FNAC and final histological diagnosis was 79%, specificity was 100%, sensitivity was 83% and diagnostic accuracy was 97%.⁹

Hypothesis: Neoplasm within the major salivary glands predominantly involves the parotid and there are both false positive and false negative results in FNAC test.

Objectives: To find out the topographical distribution and types of neoplasm of the major salivary glands and also compare the preoperative FNAC with postoperative histopathological findings of the study subjects.

Materials and Methods

Study Design - A cross sectional study was undertaken in the Department of Otolaryngology-Head and Neck Surgery, BSMMU, Dhaka from January 2007 to December 2008.

Sample Size - Sixty subjects gender matched patients with major salivary gland neoplasm confirmed by FNAC were included.

Inclusion criteria- Patients of all age with major salivary glands neoplasm and confirmed by FNAC and completion of surgery.

Exclusion criteria- Inflammatory, autoimmune and granulomatous swelling of major salivary glands.

Data collection method- Written informed consent was taken from all the respondents. Data were collected by reviewing medical records.

Sample collection- Preoperative FNAC and postoperative histopathological report.

Analysis of data and result- Results were expressed as mean \pm SD and number (percentage) where applicable. Data were analyzed by using standard statistical program. Results were evaluated by using appropriate tests (Z test and χ^2 test). P value <0.05 was taken as level of significance.

Results

During the study period among 2554 different surgery, 67 (2.6%) surgeries were done for major salivary gland neoplasm, 2487 (97.4%) surgeries were done for others. Difference between operation performed for other than salivary glands neoplasm were statistically significant ($p < 0.001$). A total of 60 gender matched patients with major salivary gland neoplasm were recruited in the study. Study subjects were between 14-85 years with mean age

of 44.5 years. Distribution of patients in different age cluster was shown in table I. Proportion of patients in 4th, 5th and 6th decade was 20%, 36.7% and 23.3% respectively which constituted 80% of cases.

Of the 60 subjects 47 (78.3%) had parotid and 13 (21.7%) submandibular gland neoplasm [$Z=0.516$; $p > 0.05$]. There was no case involving sublingual gland. Among the 47 subjects with parotid neoplasm 22 were male and 25 female having male female ration 1:1.3 On the other hand among 13 subjects with submandibular neoplasm male female distribution was 8 and 5 respectively and ratio 1.6:1. Within parotid tumours 22 (36.7%) involved the right side and 25 (41.7%) left sided. Submandibular tumours the distribution was 7 (11.7%) and 6 (10.0%) respectively (Table II).

In FNAC, among the parotid neoplasm 40 (85.1%) were benign and 7 (14.9%) malignant. In case of submandibular neoplasm the distribution was 7 (53.8%) and 6 (46.2%) respectively (Figure I). Among all the subjects distribution of benign and malignant cases were (parotid and submandibular) 47 (78.3%) and 13 (21.7%) respectively. Benign cases were significantly higher ($p < 0.001$). Within benign parotid tumour Pleomorphic adenoma was 82.5% and next frequent type was Warthin's tumour (12.5%). Of the malignant parotid tumours mucoepidermoid carcinoma was 57.1% (Table III) was commonest, Adenoid cystic carcinoma, Adenocarcinoma and Squamous cell carcinoma were same frequency (14.3%). Among benign submandibular gland tumour Pleomorphic adenoma was 57.1%. Moreover Warthin's tumour and Schwannoma were 28.6% and 14.3% respectively. Of the malignant submandibular cases 50% was adenoid cyst carcinoma, 33.3% mucoepidermal and 16.7% were adenocarcinoma (Table III).

Histopathological findings of the salivary gland neoplasm were shown in table IV. Out of 47 parotid neoplasm 39 turned out to be benign and rest 8 malignant. Among the benign cases 82.0% were Pleomorphic adenoma and 12.8% Warthin's tumour. Of the malignant parotid tumours 62.5% was mucoepidermoid carcinoma and 12.5% for adenoid cystic carcinoma, adeno-carcinoma and squamous cell carcinoma. In case of 13 submandibular glands 6 were benign and 7 malignant. Among benign cases 50.0% were Pleomorphic followed by Warthin's tumour and schwannoma 33.3% and 16.7% respectively. Of the 7 malignant submandibular cases 57.1% were adenoid cyst carcinoma followed by 28.6% mucoepidermoid carcinoma and 14.3% adenocarcinoma respectively.

Among 33 parotid pleomorphic adenoma cases most were involved in the superficial lobe rather than deep lobe (97% vs 3%; $p < 0.01$).

Table I: Distribution of patients with salivary gland neoplasm on the basis of age (yrs) groups

Age groups	Number of case	Percentage
0-10	0	-
11-20	2	3.3
21-30	6	10.0
31-40	12	20.0
41-50	22	36.7
51-60	14	23.3
61-70	3	5.0
71-80	0	-
81-90	1	1.6
Total	60	100%

Table II: Distribution of the major salivary gland neoplasm of the study subjects (n=60) on the basis of side of involvement

Gland type	Side of involvement	N (%)
Parotid (n=47)	Right side	22 (36.7)
	Left side	25 (41.7)
Submandibular (n=13)	Right side	6 (10.0)
	Left side	7 (11.7)

Table III: Distribution of study subjects (n=60) on the basis of FNAC report of major salivary neoplasm

Gland involved	Type of neoplasm	Types	Number	Percentage
Parotid (n=47)	Benign (40)	Pleomorphic adenoma	33	82.5
		Warthin's tumour	5	12.5
		Monomorphic adenoma	1	2.5
		Angioma	1	2.5
	Malignant (7)	Mucoepidermoid Carcinoma	4	57.1
		Adenoid cystic Carcinoma	1	14.3
		Adeno carcinoma	1	14.3
		Squamous cell carcinoma	1	14.3
		Pleomorphic adenoma	4	57.1
		Benign (7)	Warthin's tumour	2
Submandibular (n=13)	Benign (6)	Schwannoma	1	14.3
		Adenoid cystic Carcinoma	3	50.0
	Malignant (6)	Mucoepidermoid Carcinoma	2	16.7
		Adenocarcinoma	1	16.7

Table IV: Distribution of study subjects (n=60) on the basis of histopathological report of major salivary neoplasm

Gland involved	Type of neoplasm	Types	Number	Percentage
Parotid (n=47)	Benign (39)	Pleomorphic adenoma	32	82.0
		Warthin's tumour	5	12.8
		Monomorphic adenoma	1	2.6
		Lymphangioma	1	2.6
		Mucoepidermoid Carcinoma	5	62.5
	Malignant (08)	Adenoid cystic Carcinoma	1	12.5
		Adeno carcinoma	1	12.5
		Squamous cell carcinoma	1	12.5
		Pleomorphic adenoma	3	50.5
		Benign (06)	Warthin's tumour	2
Submandibular (n=13)	Benign (06)	Schwannoma	1	16.7
		Adenoid cystic Carcinoma	4	57.1
	Malignant (07)	Mucoepidermoid Carcinoma	2	28.6
		Adenocarcinoma	1	14.3

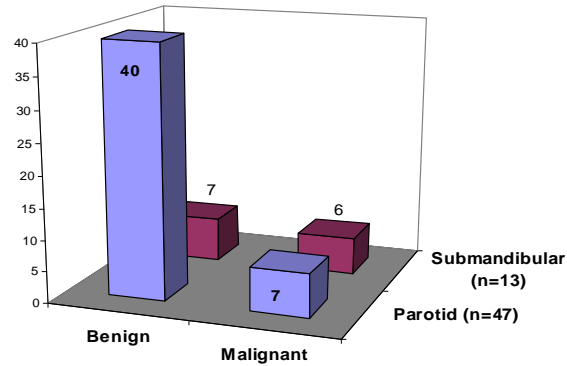


Fig. I: Distribution of subjects with major salivary (parotid and submandibular) glands on the basis of nature of neoplasm in FNAC.

Discussion

In the present series, 60 cases of major salivary gland neoplasm were studied with particular reference to find out the site distribution of neoplasm among the major salivary glands, diagnosed by FNAC and confirmation by histopathological examination. This series also compare the FNAC report with histopathological examination of resected specimen. The results obtained in this series were compared with other home and abroad studies.

Neoplasm of the parotid gland may occur at all ages, from early youth to advanced age¹⁰. In our study the youngest patient was 14 years boy with pleomorphic adenoma and the oldest 85 years female with low grade mucoepidermoid carcinoma. Mean age was 44.5 years. This trend is consistent with one study which demonstrated mean age 44.1 years¹⁰ but in other study it was 54 years⁵. Male and female were equally suffered from major salivary gland tumors^{4,10,11}. In the present study for parotid tumour male-female ratio was 1:1.13 and submandibular 1.6:1. Nagarkar and his colleagues showed that 80% salivary gland tumours were of parotid gland and 15% submandibular gland of which 80% of parotid tumours and 50% of submandibular tumours were benign¹¹. In our series 78.3% tumour involved the parotid and 21.7% submandibular gland. In another study the frequency was shown to 75% for parotid gland, 16% submandibular and 8% minor salivary gland⁵. Our study had no sublingual gland involvement. The present study demonstrated consistency about frequency of parotid neoplasm among the major salivary glands. Tumour involved the parotid gland significantly higher than submandibular gland ($\chi^2 = 5.92$, $p < 0.05$). It has been shown that 85% major salivary tumours are benign and 12% malignant¹⁰. Similarly in our study 85.1% of parotid tumours were benign and 14.9% tumour malignant.

About 50% of submandibular gland neoplasms were found to be benign and 50% malignant.¹² In the present study the benign and malignant proportion was 53.8% and 46.2% respectively. Although this trend was not different from the above mentioned but showed deviation from other in which benign submandibular tumour was 70% and malignant 30%.⁶ Among 60 cases, benign tumours were significantly higher than malignant tumour (47 vs 13; $p < 0.001$).

In case of major salivary gland tumour, there was no side predilection and also an equal distribution among right and left side.⁴ In our series among parotid and submandibular neoplasm, left side 53.3% were involved more than the right side 46.7%.

Most benign tumours were located in the superficial lobe. The ratio of superficial to deep lobe was about 4:1.¹⁰ We have found 97% cases of pleomorphic adenoma were in the superficial lobe. Researcher showed patient are more often diagnosed to have benign tumour (75%) than malignant (25%) one.¹¹ The most common benign parotid tumour was pleomorphic adenoma (51%) followed by Warthin's tumour (23%) and the most common malignant tumour was mucoepidermoid carcinoma (24.2%) followed by salivary duct carcinoma 15.2%.¹⁰ In our study the common benign parotid tumour was pleomorphic adenoma (82.0%) followed by Warthin's (12.8%) and most common malignant tumour was mucoepidermoid (57.1%) followed by adenoid cystic (14.3%) and adenocarcinoma (14.3%). This result differ from above study but correlate with others^{4,13}.

Adenoid cystic carcinoma was the most common malignant tumour (57.1%) followed by mucoepidermoid carcinoma (28.6%). This result not correspond with the study where showed among benign submandibular tumours 66% were pleomorphic adenoma and among malignant submandibular tumours 53.8% were adenoid cystic carcinoma.¹²

Fine needle aspiration cytology (FNAC) is being increasingly used in the diagnosis of salivary gland lesion. FNAC compared with histopathological findings showed diagnostic accuracy 87.5%, false positive 3.12% and false negative reports 3.97%.⁹ We found FNAC and histopathological findings comparable. It was observed that in 56 (93.3%) cases preoperative FNAC and histopathological findings were same. Only 4 (6.7%) FNAC and histopathological evaluation did not match. There was 1.7% false positive result and 5% were with false negative result.

The agreement between histotype determination using fine needle aspiration biopsy and final histological diagnosis was 79%, specificity was 100%, sensitivity was 83% and diagnostic accuracy was 97%.¹⁰ Present study revealed sensitivity 80%, specificity 97.8% and diagnostic accuracy was 93.3%. Positive predictive value and negative predictive value of our study were 92.3% and 93.6% respectively. However, the study by Balakrishnen had showed that sensitivity and specificity were 84% and 79% respectively.¹⁴

Conclusions: FNAC has been proven as cheap, safe and quite accurate in the hands of experienced cytologist. Diagnostic accuracy of FNAC in the present study was 93.3% which suggested that FNAC may be routinely used in the work-up of all major salivary gland neoplasm. Since the result of the study revealed 5% false negativity and 1.7% false positivity.

References

1. Haroon AA, Ahmed K, Hanif A, Rahman SH, Fakir AY. Squamous cell carcinoma of submandibular gland in a young man. *Bang J Otorhinolaryngology*, 1996; 2: 75-77.
2. Sharma D. *Salivary gland tumours*. 2006; [Online] [Accessed 9th Aug 2007], [<http://www.indiandctors.com>]
3. Auclair PL. Salivary gland neoplasm: General considerations. In: Ellis GL, Auclair PL, Gnepp DR, editors. *Surgical Pathology of the Salivary gland*, 1st Ed. Philadelphia: WB Saunders Company, 1991; 135-164.
4. Lee HN, Yadav BS, Ghoshal S. Treatment Outcome In Patients With Salivary Gland Tumors. *Internet J Head Neck Surgery* ISSN: 1937-819X. <http://www.ispub.com/journal/the-internet-journal-of-head-and-neck-surgery/volume-1-number-1/treatment-outcome-in-patients-with-salivary-gland-tumors.html> [Accessed 31st Aug. 2008],
5. Larrain D, Madrid A, Capdeville F, Ferrada C. Salivary gland tumors, Histopathological findings in 168 patients, *Rev. chilena de cirugia* 2005; 57: 373-378.
6. Hee CG, Perry CF. Fine- needle aspiration cytology of parotid tumours: is it useful? *Aust. NZ J Surg*, 2001; 71:345-348.
7. Sismanis A, Merriam JM, Kline TS, Danis RK, Shapshay SM, Strong MS. Diagnosis of salivary gland tumour by Fine needle aspiration biopsy. *Head Neck Surg* 1981; 3: 482-489.
8. Pandit AA, Rernandes GC. Diagnosis of salivary gland tumors by FNAC, *Indian J Cancer* 1993; 31: 260-264.

9. Aversa S, Ondolo C, Bollito E, Fadda G, Conticello S. Pre operative cytology in the management of parotid neoplasm, *Am J Otolaryngol- Head and Neck Medicine and Surgery* 2006; 27: 96-100.
 10. Tsai HM, Lin CC, Huang CC, Huq CH, Tseng HC. Parotid tumours: a 10 year experience. *Am J Otolaryngol Head and Neck Medicine and Surgery*, 2008; 29: 94-100.
 11. Nagarkar NM, Barsal S, Dass A, Singhal SK, Mohan H. Salivary gland tumors experience, *Indian J Otolaryngology and Head Neck surgery* 2004; 56: 31-34.
 12. Madrid A, Larrain D, Capdeville F, Ferrada C, Cumsille MA. Submandibular gland tumors: Experiencia del instituto Nacional del cancer, *Rev. Chilena de cirugia*, 2005; 57: 19-25.
 13. Zbaren P, Schupbach J, Nuyens M, Hauster R. Carcinoma of the parotid gland. *Am J Surgery*, 2003; 186: 57-62.
 14. Balakrishnan K, Castling B, McMahon J, Imrie J, Feeley KM, Parker AJ, Johnston BA. Fine needle aspiration in the management of a parotid mass: a two centre retrospective study. *Surgeon* 2005; 3: 67-72.
-