

LETTER TO THE EDITOR

Congenital absence of one tonsil without any other congenital abnormality: a rare presentation

Congenital absence of one tonsil alone is a rare clinical presentation. Ramsay stated that the tonsil develops at the site of the second pharyngeal pouch because it is a neutral, least disturbed, favorable site in the region of a marked shift in growth¹. So disturbance in the region of second pharyngeal pouch due to marked shift in growth during development of face and neck structures may be responsible for congenital absence of tonsil. During development displacement of mesoderm deep to the second pharyngeal pouch (which forms the tonsil) and around the first pharyngeal cleft (which forms the external ear) along with second arch may also result in the congenital absence of the palatine tonsil with malformation of the external ear on the same side². Using computerized search of the world literature from 1939 to 2010 we found nearly 3 articles consisting of 6 cases of congenital absence of tonsil with external ear deformity.

Here we report a very rare case of congenital absence of one tonsil without external ear abnormality. So far we have reviewed the literature no such unique case has been reported previously.

A 28-year-old male patient presented with complaints of pain in the throat, difficulty in swallowing and fever first visited Gynecologist, a family friend of the patient. Considering her as a physician she examined her at home and found that right tonsil was hugely enlarged and left tonsil seemed absent and referred the patient to a consultant Otolaryngologist. Otolaryngological examination findings revealed hugely enlarged and congested right tonsil, anterior pillar was also congested. Jugulodigastric lymph node on the right side was enlarged and s tender, and oral temperature was 102°F. No tonsillar tissue was seen on the left tonsillar fossa. Above mentioned features of right tonsil are consistent with acute tonsillitis. He had no previous history of tonsillectomy. He had been treated conservatively and symptoms improved within seven days. For further evaluation and documentation, endoscopic examination of oral cavity was done and, absence of tonsil was noted in the left tonsillar fossa. Ear, nose and head-neck region reveals no abnormality. MRI of the oral cavity was done and no tonsillar tissue was found in the left tonsillar bed.

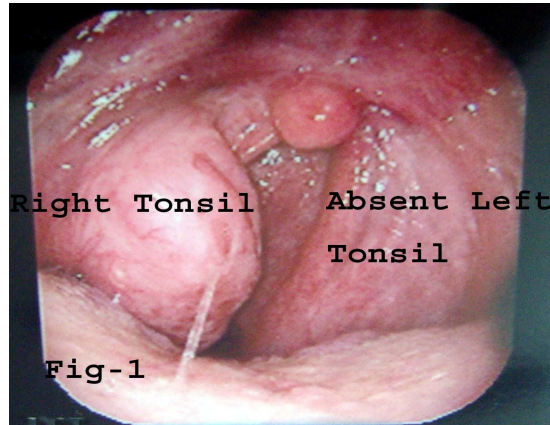


Fig.-1: Endoscopy shows absence of left tonsil

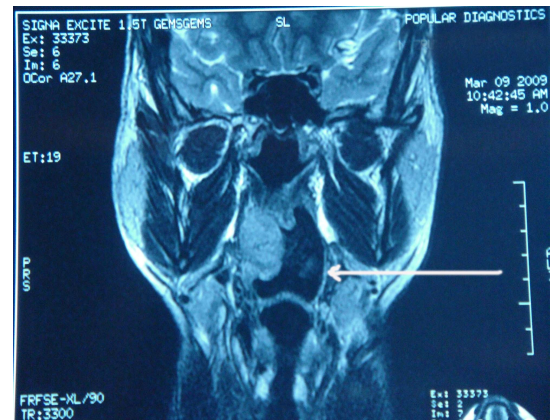


Fig.-2: MRI (coronal section) T2 weighted image shows absence of left tonsil (White arrow).

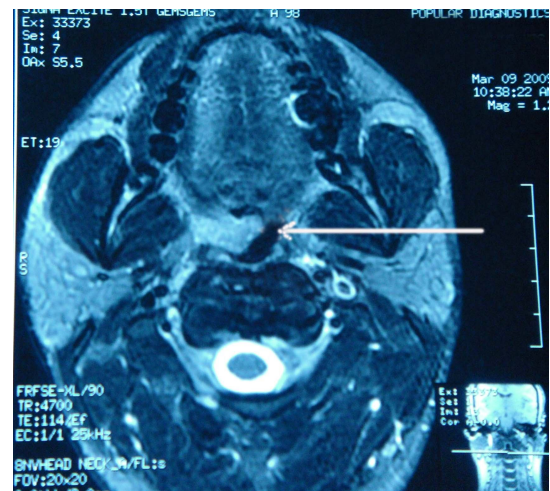


Fig. 3: MRI (axial section) T2 weighted image shows absence of left tonsil (White arrow).

Discussion

Congenital absence of one tonsil with microtia was first reported by J.W. Gerrie in 1939³. Though the patient presented with an attack of acute otitis and mastoiditis in the left deformed ear, detailed study revealed unnoticed absence of ipsilateral tonsil and polydactylism of left hand. Another case of

ipsilateral absence of tonsil and microtia with ectopic salivary gland was reported by Sinha & Singh⁴ in 1978. This patient presented with left external ear deformity with conductive hearing loss. His oropharyngeal examination found ipsilateral absence of tonsil and ectopic salivary gland in the posterior part of the tongue. In 1985 Grewal, Hiranandini and Kalgutkar⁷ reported 4 cases of congenital external ear deformity with conductive hearing loss along with unnoticed ipsilateral congenital absence of palatine tonsil. In reported cases lowest age was 6 and highest was 18. In our case 28 year old male presented with the features of acute tonsillitis of right tonsil with absence of left tonsil without external ear deformity, hearing loss or any other congenital abnormality. Here absence of tonsil is an incidental finding.

A case presents with congenital external ear deformity one must search for absence of palatine tonsil. But the patient presents with absence of one palatine tonsil without external ear deformity, the findings may remain unnoticed and lately presented following an acute attack of the opposite one.

Congenital unilateral absence of tonsil is a very rare condition. Early diagnosis is possible along with external ear deformity. Agenesis of one tonsil without external ear deformity may have delayed or incidental presentation.

Acknowledgement

The author thanks to Dr. S.M. Ishaq, consultant gastroenterologist, comfort diagnostic centre, Dhaka for videoendoscopic picture.

Datta PG¹, Saha KL², Roy JS³, Biswas AK², Das PP⁴

¹Professor of Otolaryngology & Vice Chancellor, Bangabandhu Sheikh Mujib Medical University, Dhaka, ²Dept. of Otolaryngology & Head-Neck Surgery, Bangabandhu Sheikh Mujib Medical University, Dhaka, ³Dept. of Obstetrics and Gynecology, Dhaka Medical College Hospital, Dhaka, ⁴Dept. of Medicine, Dhaka Medical College Hospital, Dhaka, Email: drklsaha@gmail.com

References

1. Ramsay AJ. The development of the palatine tonsil (cat). *American Journal of Anatomy* 1935; 57(1):171-203.
2. Grewal DS, Hiranandani NL, Kalgutkar JS. Congenital absence of the palatine tonsil associated with congenital malformation of the external ear. A congenital anomaly. *The Journal of Laryngology and Otology* 1985; 99: 285-288.
3. Gerrie JW. Congenital absence of one tonsil. Microtia and Polydactylism in the same patient. *Archives of Otolaryngology-Head & Neck Surgery* 1939; 29(2): 378-381.
4. Sinha SN, Singh AK. Ipsilateral absence of tonsil and microtia with ectopic salivary gland-a case report. *J Laryngol* 1978; 92(12): 1147-9.

Back Pain: An Unusual Presentation of Castleman's Diseases

A 17-year-old school boy from Comilla attended us on 4 August, 2010 with severe episodic back pain, abdominal discomfort and intra-abdominal masses for 10 months. The pain usually appeared once in a week or two, spreading from mid back upwards, gradually deteriorating over months. The first physician he encountered found several intra-abdominal masses for which he underwent abdominal surgery in January, 2010. Two months after surgery his symptoms reappeared with localized abdominal swelling right to the umbilicus, and intermittent high grade fever, drenching night sweats, generalized weakness, anorexia and weight loss. His investigation reports over this period revealed mild normocytic normochromic anaemia and raised ESR. WBC, platelet count, bilirubin, creatinine, LDH, blood urea, ALT all were within normal limit. On 6 January, 2010 he underwent abdominal surgery for lymph node biopsy and histopathological examination of which revealed angiofollicular lymph node hyperplasia, i.e.; Castleman's disease (CD). On 2 Aug 2010 MRI of lumbosacral spine was advised by neurosurgeon due to persistent back pain which revealed insignificant finding.

Patient attended Department of Haematology in BSMMU after 7 months of diagnosis of Castleman's disease. On physical examination multiple intra-abdominal masses were found in umbilical region and right iliac fossa, the largest one measuring about 5cm X 5cm, fixed, tender, with smooth surface. Repeat excisional biopsy was important because multicentric CD has potential to evolve into NHL. Previous paraffin impregnated tissue blocks were collected and sent for second opinion. The comment was similar as before, consistent with plasma cell variant (PCV) of CD.

Discussion

Castleman's disease was first recognized in the 1920s and was further described as a clinicopathologic entity in 1954. In 1956, Dr. Benjamin Castleman and coworkers described a patient with a localized mediastinal mass that on biopsy showed hyperplasia resembling Hassall's corpuscles of the thymus, as well as capillary proliferation and hyalinization. Histologically, Castleman's disease is an atypical lymphoproliferative disorder not clearly identified as reactive or neoplastic. While not officially considered a cancer, the overgrowth of lymphatic cells with this disease is similar to lymphoma. The