

Case Report

Osteoma of mastoid part of temporal bone - a rare clinical entity

Naseem Yasmeen¹, M. Alamgir Chowdhury², SM Golam Rabbani³, Mousumi Malakar⁴

Abstract:

Here a case of osteoma is described situated in right mastoid part of temporal bone (post auricular region) in a 35-year-old female. The swelling was slow-growing, oval in shape, stony hard in consistency, 3cm x 5cm in size with normal & free overlying skin but fixed to the bone & non-tender. FNAC revealed no malignant cells. X-ray Mastoids Towne's view showed right mastoiditis. CT scan findings were in favour of angular dermoid without bony erosion. Surgical excision was done under general anaesthesia. Histopathological report was osteoma. Postoperative period was uneventful and follow up after 10 days was fine.

Key words: Osteoma, Temporal bone.

Introduction:

Extracanalicular osteomas of temporal bone are rare, slow-growing, benign neoplasm. Although it may occur anywhere in the temporal bone, it is most common in the mastoid area.¹ It has been described in the literature in only 130 cases between 1861

and 2004.² These can present in the mastoid, squamous part of temporal bone, internal auditory meatus and the middle ear.³ When located in the mastoid, these are solitary, sessile or pedunculated and normally progress to extra cranial growth.⁴ Osteomas in general occur after puberty and those of the mastoid process are seen more often in females.⁵ However, osteomas of the middle ear are more common in males.⁶ Osteoma of the mastoid can be classified as a true osteoma, or a bony neoplasm, rather than as an exostosis or hyperostosis.⁴ Histologically there are 3 types of osteoma of mastoid – osteoma compactum, osteoma cancellariae, osteoma cartilagineum.⁷ Clinically it is difficult to distinguish the type of osteoma because of the similarity of symptoms and objective signs.⁸ The aetiology is not clear and various theories have been suggested, which include: trauma, infection and hereditary.⁹ Excessive periosteal growth activity of the periosteal osteoblasts has also been suggested.¹⁰ Often, symptoms are

1. Assistant Professor, Otolaryngology-Head & Neck Surgery, Medical College for Women & Hospital, Uttara, Dhaka, Bangladesh
2. Professor and Head, Otolaryngology-Head & Neck Surgery, Medical College for Women & Hospital, Uttara, Dhaka, Bangladesh
3. Registrar, Otolaryngology-Head & Neck Surgery, Medical College for Women & Hospital, Uttara, Dhaka, Bangladesh
4. Medical Officer, Otolaryngology-Head & Neck Surgery, Medical College for Women & Hospital, Uttara, Dhaka, Bangladesh

Address of correspondence: Dr. Naseem Yasmeen, Assistant Professor, Otolaryngology-Head & Neck Surgery, Medical College for Women & Hospital, Uttara, Dhaka.

negligible and treatment is unnecessary. However surgical removal is indicated when growth of osteoma causes distressing symptoms and becomes disfiguring.¹ Pain occurs if the growth involves the inner table of the temporal bone.⁴ Depending on their location, it may cause tinnitus, hearing loss, vertigo and facial nerve paresis.¹¹ It can cause functional symptoms causing obstruction in external auditory canal and conductive hearing loss, may cause brain compression and generalized epileptic seizures.¹² CT Scan and MR imaging studies allow one to evaluate the extent of the disease in soft tissues and in the bony structures of the temporal bone.¹³ However surgical removal is indicated mainly for cosmetic reasons or if there is any symptom.¹

Case report:

A 35-year-old female presented with swelling, right mastoid region for the last 25 years. It was found to be oval in shape, 3cm x 5cm in size, stony hard in consistency, non-tender, free overlying skin but firmly adherent to the underlying bone.

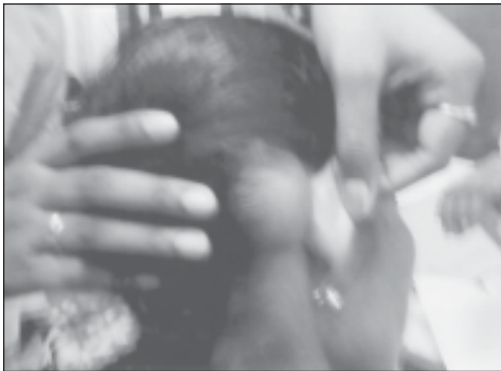

Fig.-1: Showing stony, hard swelling over right mastoid region.

The swelling was slow-growing with no history of trauma, headache, vomiting, hearing impairment, otorrhoea, dizziness, visual

disturbance or any neurological deficit. All routine investigations were within normal limits. X-Ray Mastoids Towne's view showed right mastoiditis. FNAC revealed no malignant cells. CT Scan finding was in favour of angular dermoid in the right mastoid area originating from the outer table of the skull with no bony erosion or intracranial extension.

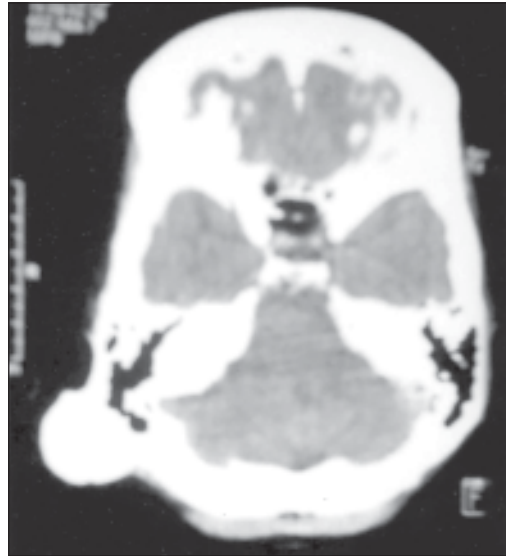


Fig.-2: Showing angular dermoid in the right mastoid area originating from the outer table of the skull with no bony erosion or intracranial extension.

Surgical excision was decided under general anaesthesia. Intraoperative finding was a single, stony hard mass, firmly adherent to the mastoid which had to be separated by chisel and hammer as the tissue was stony hard. Drilling was done to smoothen the bone edges. Histopathological report was osteoma. Postoperative period was uneventful and the patient was doing well till the last follow-up.

Discussion:

Though osteoma of the temporal bone is a rare, slow-growing, benign neoplasm, we have encountered such a case in a female of 35-

year-old for 25 years. Mostly it occurs in mastoid bone in females after puberty which was so in our case. Description of the mass was similar to an osteoma of temporal bone. Regarding aetiology, there was no history of trauma or infection. In mastoid osteomas extending into the facial canal and bony labyrinth, complete excision is not indicated since there may be damage to these structures.¹⁴ CT Scan findings in our patient showed no intracranial extension which was helpful for complete excision. As it is usually asymptomatic, surgical excision is not indicated except for cosmetic reasons. Our patient attended to us for removal of the mass on cosmetic grounds which are the most common indication for surgery. These osteomas might have caused obstruction in external auditory canal and conductive hearing loss which were absent in our patient.

Conclusion:

Though rare, osteoma of mastoid temporal bone has the potential for intracranial extension. So after proper and early diagnosis, surgical excision followed by histological examination is essential.

References:

1. Viswanatha B. Extracanalicular osteoma of the temporal bone. *Ear Nose Throat J* 2008; 87(7): 381-3.
2. Magliulo G, Pulice G. Mastoid Osteoma. *Annal Otorhinolaringol* 2005; 32: 271-8.
3. Simpson WL. Osteoma of the mastoid: report of two cases. *Arch Otolaryngol* 1940; 32: 642-661.
4. Stuart EA. Osteoma of the mastoid: report of a case with investigations of the constitutional background. *Arch Otolaryngol* 1940; 31: 838-854.
5. J.S. Gulia & S Yadav: Mastoid osteoma: A Case Report. *The Internet Journal of Head and Neck Surgery* 2009; 3 (1): 22-23.
6. Hornigold R, Pearch BJ, Gleeson MJ. An Osteoma of the middle ear presenting with the Tulio phenomenon. *Skull Base* 2003; 13: 113-17.
7. Fenton JE, Turner J, Fagan PA. A histopathologic review of temporal bone exostosis & osteomata. *Laryngoscope* 1996; 106: 624-628.
8. Gungor A, Cincik H, Poyrazoglu E, Saglam O, Candan H. Mastoid osteoma: report of two cases. *Otol Neuro-otol* 2004; 25: 95-97.
9. Denia A, Perez F, Canalis RR, Graham MD. Extracanalicular osteomas of the temporal bone. *Arch Otolaryngol* 1979; 105: 706—709.
10. Gupta OP, Samant HC. Osteoma of the mastoid. *Laryngoscope* 1972; 82: 172-176.
11. Lee RE, Balkany TJ, Giant mastoid osteoma with postoperative high frequency sensorineural hearing loss. *Ear Nose Throat J* 2008; 87(1): 23-5.
12. Bhandari YS, Jones RAC. Osteoma of the middle cranial fossa. *J Neurosurg* 1978; 37: 610-612.
13. Lemmerling MM, De Foer B, Vandevyver V. Imaging of inflammatory & infectious diseases in the temporal bone. *Neuroimaging Clinics of North America* 2009; 19(3): 321-37.
14. Coates GM. Osteoma growing from mastoid cortex. *Arch Otolaryngol* 1938; 28: 27-28.