

Original Article

Transcanal Endoscopic Approach to the Mastoid Segment of Facial Nerve and the Role of the Pyramidal Eminence as a Landmark

Sheikh Shawkat Kamal

Abstract:

Objectives: *To study the feasibility of approaches in addressing the mastoid segment of facial nerve through transcanal route exclusively under endoscopic guidance and to verify the usefulness of the pyramidal eminence as a landmark.*

Study design: *The prospective experimental study*

Setting: *“Transcanal endoscopic temporal bone dissection lab” situated in the Surgiscope hospital, Chittagong, Bangladesh.*

Materials: *4 (Four) cadaveric temporal bones.*

Interventions: *Two pure transcanal endoscopic approaches were applied to excavate the mastoid segment of facial nerve. In anterior-medial approach, the dissection was progressed from medial to the lateral direction through the retrotympanum focusing the anterior-medial side of the mastoid segment of facial nerve. Whereas in anterior-lateral approach, the dissection was progressed from lateral to the medial direction through the posterior canal wall focusing the anterior-lateral side of the mastoid segment of facial nerve. In both approaches, the pyramidal eminence was considered as an anatomical landmark to navigate the dissection for the excavation of the mastoid segment of facial nerve.*

Main outcome measures: *The efficacy of each approach in respect of the complete excavation of the mastoid segment of facial nerve and the worthiness of the pyramidal eminence as the landmark for navigating the dissection.*

Results: *In both transcanal endoscopic approaches, the entire mastoid segment of facial nerve could be exposed successfully. But in anterior-medial approach, the chorda tympani nerve was needed to be sacrificed. The search of the mastoid segment of facial nerve with the guidance of the pyramidal eminence was observed as effective and safe.*

Conclusion: *The entire mastoid segment of facial nerve could be successfully addressed through transcanal route under pure endoscopic guidance. The pyramidal eminence has appeared as an important landmark for such endeavor.*

Address of Correspondence: Dr. Sheikh Shawkat Kamal, Consultant Surgeon, Ear, Nose and Throat Department, Surgiscope Hospital, Chittagong, Bangladesh. Phone: 8801711406943, Email: drjoyent@yahoo.com, drshawkatent@gmail.com

Introduction:

To avail the benefits of the minimally invasive surgery offered by the endoscope, many middle ear surgeries that were previously performed under the microscope are now being addressed purely under

endoscopic guidance. Recently practised transcanal endoscopic surgery for the lesions of the tympanic part of the facial nerve is a good example of such attempt.^{1,2} Switching from microscope to endoscope for approaching to the tympanic part of facial nerve has been proved to be least morbid. Moreover, attempt to the lesions of other territories of the fallopian canal such as geniculate ganglion and the proximal part of mastoid segment of facial nerve had also been done with success through transcanal route exclusively under endoscopic guidance.^{3,4}

The approach to the entire mastoid segment of the facial nerve has still remained under the domain of microscopic mastoid surgery. In this standpoint, transcanal endoscopic approach to the entire mastoid segment of facial nerve could be a novel surgical attempt. Unlike the tympanic segment of facial nerve, the mastoid segment is not readily approachable as it remains entirely hidden.

The fallopian canal of the mastoid segment of facial nerve extends from the second genu down to stylomastoid foramen of the temporal bone having almost a vertical course of 15.4 ± 2.14 mm long.⁵ The second genu and the adjacent small part of the mastoid segment are confined in the posterior wall of the retrotympanum. After leaving the retrotympanum in between the posterior wall of the external auditory canal and the horizontal semicircular canal, it goes down along the anterior wall of the mastoid process towards the stylomastoid foramen. Near the second genu, it is closely related with the horizontal semicircular canal and the pyramidal eminence. The distance between the ampular end of the horizontal semicircular canal and the

second genu is 2 ± 0.5 mm.⁶ The second genu lies just posterior-lateral to the pyramidal eminence. Some vital structures come in close relation to the passage of the mastoid segment of facial nerve. The sinus tympani and the posterior semicircular canal come to its posterior-medial side whereas the perifacial mastoid cells, part of the mastoid antrum and the sigmoid sinus come to its posterior lateral side. The anterior-lateral aspect of the mastoid segment of facial nerve is entirely covered by the bony tympanic annulus and by the posterior bony canal wall. As the mastoid segment of the facial nerve leaves the retrotympanum, it crosses the ring of the bony tympanic annulus from medial to lateral direction. This crossing point is the site where the tympanic annulus becomes very close to the mastoid part of facial nerve and it is roughly at the 9 o'clock and 3 o'clock position of the ring of the annulus in right and left ear respectively. According to Nicoleta Măru et. al. this distance was 0.85 mm.⁶ The distance from the posterior bony canal wall to mastoid segment of facial nerve appeared 2.9 ± 1.1 mm in the CT image of the well pneumatized mastoid bone.⁷

Since the mastoid segment of facial nerve has close anatomical relation with posterior bony canal wall and the retrotympanum, so any dissection either passing through the posterior bony canal wall or causing wide exposure of the retrotympanum was expected to expose the area of the mastoid segment of facial nerve. This had also been noticed that the pyramidal eminence as the solid landmark of the second genu of facial nerve could be used to guide the dissection necessary for excavation of the mastoid segment of facial nerve. With these predictions, two approaches were tailored

and attempted to excavate the mastoid segment of facial nerve through transcanal route on the cadaveric temporal bones. The first approach was the anterior-medial approach where the dissection was entirely directed from medial to the lateral direction focusing the anterior medial side of the mastoid segment of facial nerve. The second approach was the anterior-lateral approach where after a preceding exploratory dissection to find out the base of the pyramidal eminence, the main dissection was directed from lateral to the medial direction focusing the anterior lateral side of the mastoid segment of facial nerve. In both approaches, the exploratory dissection progressed gradually along a vertical plane imagined from the base of the pyramidal eminence to excavate the mastoid segment of facial nerve. The present study elaborately depicted the procedures, viability and efficacy of these two attempted approaches.

Materials and Methods:

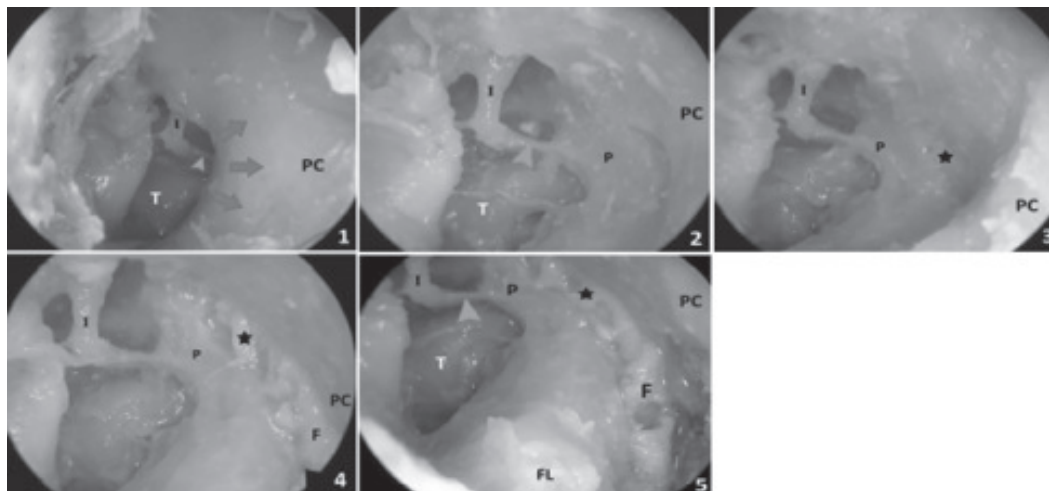
This prospective study was conducted during the period of April'2018 in the "transcanal endoscopic temporal bone dissection lab" situated in the Surgiscope Hospital, Chittagong, Bangladesh. Total 4 (four) adult disarticulated cadaveric temporal bones, well preserved in saturated salt solution were included in this study out of which two were right ear and two were left ear.

0°, 4mm diameter, 18 cm long endoscope was used. Full HD integrated imaging system (iONE Guangzhou, China) was used for video endoscopy and recording. Drilling was done with micromotor (Strong model, Saeshin Precision IND. CO. Korea).

1.8 mm and 3.1 mm cutting round burr were mostly used for the bony dissection. 1.8 mm diamond burr was used to thin out the bone near the fallopian canal of facial nerve. The cadaveric temporal bone was attached to the temporal bone holder in such away that the tip of mastoid was facing the right side of the surgeon in case of right temporal bone and left the side of the surgeon in case of left temporal bone. The bone was tilted towards the surgeon so that, the external auditory canal and the surgeon's eye vision were in the same axis.

All the procedures were done through transcanal route exclusively under endoscopic view while holding the endoscope by non-dominant hand and conducting all instrumentations by dominant hand. For convenient and effective transcanal endoscopic drilling of bone, procedures involving a shortly timed drilling with cutting burr then irrigation with saline water followed by suction clearance have been done in a sequential order.⁸

In the beginning, an incision was given in the meatal skin about 15mm posterior from the tympanic annulus to elevate a wide anteriorly based tympanomeatal flap. It ultimately exposed the tympanum, scutum and about 15mm of the adjacent posterior canal wall. The chorda tympani nerve was partially detached from its bony passage near tympanic annulus and adjacent few millimeters of the posterior canal wall to facilitate its preservation during dissection. Up to this step, above procedures were common for both approaches. Rests of the procedures for individual approaches were mentioned below under separate headings.



1. Planning of the dissection for retrotympanotomy.
2. After retrotympanotomy, complete exposure of the pyramidal eminence up to its base.
3. Excavation of the nerve sheath of second genu at the base of the pyramidal eminence.
4. Gradual exposure of the mastoid part of facial nerve by dissection along the imaginary vertical plane descending from the second genu towards the floor of the external auditory canal.
5. View of the mastoid segment of facial nerve after its complete excavation through anterior medial approach.

Abbreviations & Symbols:-

Green arrow head=the stapedius tendon, Red arrows = the direction of dissection for retrotympanotomy,

Black Star : =the exposed nerve sheath of the second genu, **PC** = the posterior canal wall, **I** = the long process of incus, **T**= the tympanic cavity, **P** = the pyramidal eminence, **F** = the mastoid segment of facial nerve, **FL** = the floor of the external auditory canal.

Figure A: Chronological pictures of the transcanal endoscopic anterior-medial approach to the mastoid segment of facial nerve in left ear.

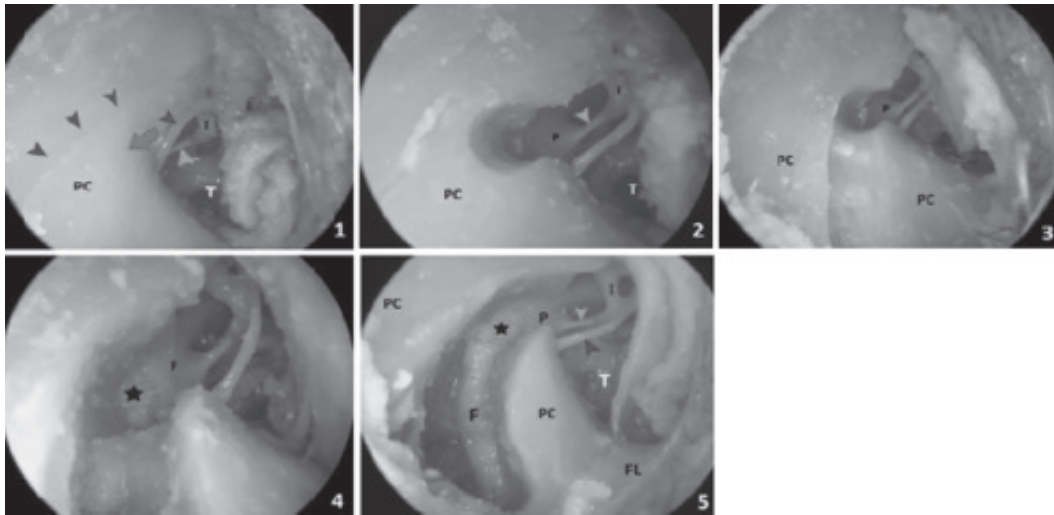
Anterior-medial approach: [Figure A]

All the dissections were done from medial to the lateral direction in a retrograde fashion focusing the anterior-medial side of the mastoid segment of facial nerve. Two cadaveric temporal bones (one left ear and one right ear) were subjected for this approach. With cutting burr, the tympanic annulus and the posterior canal wall lateral to the retrotympanum were dissected out (retrotympanotomy) to facilitate the view of the pyramidal eminence in the posterior wall

of retrotympanum. The chorda tympani nerve was transected to extend this initial bony dissection further posterior in order to get the clear view of the base of pyramidal eminence. The bone at the base of the pyramidal eminence was thinned out with diamond burr and later was dissected out with House micro-curette to expose the nerve sheath of second genu. A vertical plane descending from this exposed second genu towards the floor of the external auditory canal was imagined to guide the next

dissection towards the location of the unexposed mastoid segment of facial nerve. With cutting burr, bony dissection was carried out along this imaginary vertical plane. Care was taken to stay away from the unnecessary disruption of the mastoid air cells by avoiding dissection more posterior-laterally. When this dissection reached near

to the location of the unexposed mastoid segment of facial nerve, the remaining bone along this vertical plane was thinned with diamond burr. Later this thin bone was dissected out with House micro-curette to expose the nerve sheath of the mastoid segment of facial nerve.



1. Planning of the dissection to expose the pyramidal eminence.
2. Exposure of the pyramidal eminence.
3. The progressive dissection on the posterior canal wall along the imaginary vertical plane descending from the base of the pyramidal eminence towards the floor of the external auditory canal.
4. Excavation of the nerve sheath of second genu at the base of the pyramidal eminence.
5. View of the mastoid segment of facial nerve after its complete excavation through anterior-lateral approach.

Abbreviations & Symbols:-

Green arrow head=the stapedius tendon,

Blue arrow head =the chorda tympani Nerve, **B**

Black arrow head =the tympanomastoid suture line,

Red arrow=the direction of dissection to expose the pyramidal eminence,

Black star =the exposed nerve sheath of the second genu.

PC = the posterior canal wall, **I** = the long process of incus.

T= the tympanic cavity, **P** = the pyramidal eminence, **F** = the mastoid segment of facial nerve,

FL = the floor of the external auditory canal.

Figure B: Chronological pictures of the transcanal endoscopic anterior-lateral approach to the mastoid segment of facial nerve in the right ear.

Anterior-lateral approach: [Figure B]

Two cadaveric temporal bones (one left ear and one right ear) were subjected for this approach. Initially, with cutting burr, a partial retrotympanotomy was done under the tympanomastoid suture line to clearly expose the base of pyramidal eminence. A vertical plane on the posterior canal wall descending from the base of pyramidal eminence towards the floor of the external auditory canal was imagined to guide the next dissection towards the location of the unexposed mastoid segment of facial nerve. Then with cutting burr, bony dissection was carried out along this imaginary vertical plane on the posterior canal wall in an antegrade fashion. The dissection progressed gradually from above to downward. Care was taken to stay away from the unnecessary disruption of the mastoid air cells by avoiding dissection more posterior-laterally. The bone at the base of the pyramidal eminence was thinned out with diamond burr. Later this thin bone was dissected out with House micro-curette to expose the nerve sheath of second genu. The remaining bone over the unexposed mastoid segment of the facial nerve along the vertical plane was further thinned with diamond burr. Later this thin bone was dissected out with House micro-curette to expose the nerve sheath of the mastoid segment of facial nerve.

Any disruption of the mastoid antrum/ mastoid periantral cells through either of these two approaches was also carefully scrutinized at the end of the dissection.

Results:

In all cases, the entire mastoid segment could be excavated successfully through these two transcanal endoscopic approaches. Although in anterior-medial approach, the chorda tympani nerve was sacrificed intentionally to complete the

necessary dissection. Conversely, in anterior-lateral approach, the chorda tympani nerve could be preserved successfully.

The vertical plane imagined on the posterior canal wall from the base of the pyramidal eminence always guided the dissection effectively towards the actual location of the mastoid segment of facial nerve. The initial exposure of the nerve sheath of the second genu also helped to navigate the dissection confidently and safely for the excavation of the mastoid segment of facial nerve.

No disruption of the mastoid antrum/ mastoid periantral cells was seen in any case involving either of these two approaches. Only a few mastoid cells near the stylomastoid foramen end of the nerve were seen exposed in both approaches.

Discussions:

Besides the success of excavation of the entire mastoid segment of facial nerve through either of these two transcanal endoscopic approaches, few additional facts have also been observed in this study. It has been evident that all the procedures involved in these two approaches could be done easily by using 0° endoscope. The necessity of the angled endoscope was not felt at all in any step of the procedure. The issue of conservation of the chorda tympani nerve was the major differentiating point in the outcome of these two approaches. In anterior-medial approach, the chorda tympani nerve was needed to be sacrificed for the sake of completing the required dissection whereas, in anterior-lateral approach, this nerve could be preserved successfully. The vertical plane imagined on the posterior canal wall from the base of the pyramidal eminence was felt very much essential to guide the dissection safely towards the location of the mastoid segment of facial nerve. The pyramidal eminence

appeared as the only solid landmark to plan this imaginary vertical plane on the posterior canal wall. So in absence of the pyramidal eminence either by disease or by congenital error, successful transcanal endoscopic approach to the mastoid segment of facial nerve would be difficult. As the mastoid segment of facial nerve descends along the anterior wall of the mastoid process, so there was a risk of disruption of the mastoid antrum/ mastoid periantral cells while approaching to this segment. Apart from the exposure of few mastoid cells near the nerve, it has been observed that a careful dissection along the vertical plane could effectively preserve almost entire mastoid system.

While approaching through transcanal route, two other vital issues were also kept in concerned that might bring variation in the vertical figure of the descending mastoid segment of facial nerve. The first issue was the effect of angular variation of the second genu on the location of the distal portion of mastoid segment. The angle at the second genu between the mastoid part and the tympanic part of facial nerve is ranging from 92° to 125° . So in presence of the obtuse second genu, the distal mastoid segment could have appeared at a more posterior lateral position than its presumed vertical position. But this effect of angular variation of the second genu was least observed in this study since the mastoid segment was viewed from the lateral position rather than the true anterior position. The second issue was the effect of sway of the descending mastoid segment in respect of the sagittal plane either to medial or to lateral. In one Indian study, the descending course of the mastoid segment was found swayed either to medial or to lateral in 40% of their cases and in rest 60% cases, it remained in the vertical plane without any sway.⁵ So if this sway does happen then the part of the

mastoid segment near the stylomastoid foramen would appear either superficial or deep in comparison to the proximal part near the second genu. Considering this fact, here, the dissection was planned to proceed gradually from the upper consistent end to the lower inconsistent end of the mastoid segment of facial nerve.

Three relevant works have been identified in the medical literature that involved transcanal endoscopic exposure of the mastoid segment of facial nerve. In Wick C et al work, while dealing with avascular malformation involving the proximal part of the mastoid segment of facial nerve, the involved part of the mastoid segment was seen excised successfully through transcanal endoscopic anterior-medial approach after sacrificing the chorda tympani nerve. A good pictorial view of the excavated mastoid segment of facial nerve through transcanal route was found in L. Presutti et al work.⁹ But the details of such dissection were not mentioned there. In author's own previous work, the mastoid segment of facial nerve had also been exposed through the transcanal endoscopic mastoidectomy approach.¹⁰ But the major difference with present study is that here, the mastoid system was almost entirely preserved.

It has been clearly evident in this study that the entire mastoid segment of the facial nerve could be excavated effectively through the transcanal endoscopic approach. In comparison to its traditional counterpart- the postauricular mastoidectomy approach, this transcanal approach could preserve the mastoid system and avoid postauricular incision. With this minimal invasive character, the transcanal endoscopic approach has opened a new horizon of addressing any part of the tympanomastoid segment of facial nerve starting from the geniculate ganglion to stylomastoid foramen.

Further clinical application of such approach would substantiate this fact.

Conclusions:

Like the tympanic part of facial nerve, the entire mastoid segment of facial nerve could be successfully approached through the transcanal route purely under endoscopic guidance. For such approach, the pyramidal eminence has played a vital role to navigate the required bony dissection.

References:

1. Marchioni D, Alicandri-Ciufelli M, Piccinini A, Genovese E, Monzani D, Tarachi M, Presutti L. Surgical Anatomy of Transcanal Endoscopic Approach to the Tympanic Facial Nerve, *Laryngoscope* 2011; 121:1565–1573.
2. Kahinga AA, Han J H, Moon I S. Total Transcanal Endoscopic Facial Nerve Decompression for Traumatic Facial Nerve Palsy. *Yonsei Med J* 2018 May;59(3):457-460.
3. Marchioni D, Soloperto D, Genovese E, Rubini A, Presutti L. Facial nerve hemangioma of the geniculate ganglion: an endoscopic surgical approach. 2014 Dec;41(6):576-81.
4. Wick C C, Sakai M, Richardson T E, Isaacson B. Transcanal Endoscopic Ear Surgery for Excision of a Facial Nerve Venous Malformation With Interposition Nerve Grafting: A Case Report. *Otol Neurotol* 2017;38:895–899.
5. Yadav S P S, Ranga A, Sirohiwal B L, Chanda R. Surgical Anatomy of Tympano-mastoid Segment of Facial Nerve. *Indian Journal of Otolaryngology and Head and Neck Surgery* 2006 January-March; 58(1):27-30.
6. Maru N, Cheita A C, Mogoanta C A, Prejoianu B. Intratemporal course of the facial nerve: morphological, topographic and morphometric features. *Romanian Journal of Morphology and Embryology* 2010, 51(2):243–248.
7. Aslan A, Goktan C, Okumus M, Tarhan S, Unlu H, Morphometric analysis of anatomical relationships of the facial nerve for mastoid surgery. *The Journal of Laryngology & Otology* June 2001; **115**: 447–449.
8. Kamal S S. A worthy technique for transcanal drilling during endoscopic ear surgery. *Research gate*. Sheikh Shawkat Kamal. 9th October. 2015. Web. 22nd November. 2015. https://www.researchgate.net/publication/284327632_A_worthy_technique_for_transcanal_drilling_during_endoscopic_ear_surgery
9. L. Presutti, M. Bonali, D. Marchioni, G. Pavesi, A. Feletti, L. Anschuetz, M. Alicandri-Ciufelli. Expanded transcanal transpromontorial approach to the internal auditory canal and cerebellopontine angle: a cadaveric study. *Acta Otorhinolaryngologica Italica* 2017; 37: 224-230.
10. Kamal S S. The Practice of Transcanal Endoscopic Mastoid Dissection on Cadaver. *Research gate*. Sheikh Shawkat Kamal. 26th June. 2016. Web. 5th July. 2016. https://www.researchgate.net/publication/304801170_The_Practice_of_Transcanal_Endoscopic_Mastoid_Dissection_on_Cadaver