

Original Article

Relationship between Inferior Thyroid Artery and Recurrent Laryngeal Nerve - A Study of 200 Cases

Muhammad Ali Azad¹, AKM Asaduzzaman², Mohammad Delwar Hossain², Faysal Bin Mohsin³, Abdullahis Safi³

Abstract

Introduction: Thyroid surgery is a common modality of treatment for both benign and malignant thyroid disorders. Relationship between inferior thyroid artery (ITA) and recurrent laryngeal nerve (RLN) is crucial in preservation of recurrent laryngeal nerve. Thorough anatomical knowledge and meticulous surgery will ensure the integrity of recurrent laryngeal nerve.

Objective: The purpose of this study is to observe the anatomical position of recurrent laryngeal nerve in relation to inferior thyroid artery which will eventually lead to identification of recurrent laryngeal nerve peroperatively.

Methods: A cross sectional retrospective study was conducted during the time period of 1st January 2013 to 31st December 2015 in Combined Military Hospital, Dhaka among 200 patients who had undergone thyroidectomy.

Results: In this series on the right side 71.8% cases RLN was dorsal to ITA, 21.7% cases it was ventral and in 6.5% cases RLN runs in between the branches of ITA. In case of left side 74.5% cases RLN was dorsal to ITA, 22.5% cases it was ventral and in 3% cases RLN runs in between the branches of ITA.

Conclusion: Usually RLN runs dorsal to ITA. In left side it is deeper and in case of right side it is more superficial. RLN may pass through the branches of ITA, but it is not very common.

Key words: Recurrent laryngeal nerve (RLN), Inferior thyroid artery (ITA).

-
1. Head neck Oncosurgeon, Dept. of ENT and Head - Neck surgery, Combined military hospital Dhaka.
 2. Head neck Surgeon, Dept. of ENT and Head-Neck Surgery, Combined Military Hospital Dhaka.
 3. Trainee Officer (Otolaryngology), Dept. of ENT and Head - Neck surgery, Combined Military Hospital Dhaka

Address of correspondence: Lt Col (Dr.) Muhammad Ali Azad, Head Neck Oncosurgeon, Dept. of ENT and Head - Neck Surgery Combined Military Hospital Dhaka.

Introduction

In initial period thyroid surgery was associated with higher morbidity. Subsequently it was well understood that RLN, parathyroids and external branch of superior laryngeal nerve has to be preserved.¹ Anatomical relationship between RLN and ITA is very important in order to preserve the RLN.^{2,3} Mostly the morbidity is due to technical failure (inadequate anatomical knowledge, lack of surgical skill & experience, distorted anatomy as in cancer & large

multinodular goiter) to identify the vital structures and the variations in the surgical anatomy. Several studies have been published revealing the anatomy of the RLN in thyroid surgery.

The ITA normally arises from the thyrocervical trunk.⁴ Which is a branch of first part of subclavian artery⁵. Past Studies have reported the incidence of origin of the ITA from the vertebral artery and internal thoracic artery. Absence Of ITA (unilateral Or bilateral) have also been reported in previous studies.^{6,7,8,9,10}

The recurrent laryngeal nerves branch from the vagus nerve, relative to which they get their names; the term “recurrent” from Latin: re- (back) and currere (to run), indicates they run in the opposite direction to the vagus nerves from which they branch. The vagus nerves run down into the thorax, and the recurrent laryngeal nerves run up to the larynx.¹¹

The vagus nerves exit the skull through the jugular foramen and travel within the carotid sheath dorsal to the carotid artery. After arising from vagus the RLN hooks around the aortic arch on the left side and the subclavian artery on the right side.¹¹

Both RLN and ITA may be branching or non branching. mostly branching of RLN occurs after crossing the ITA 1 cm below the cricothyroid joint. RLN may be related dorsally, ventrally or in between branches of ITA.

Methods

This descriptive study based on the retrospective data was conducted at Combined Military Hospital, Dhaka during the period of January 2013 to December 2015. Total 200 cases were studied. Approval of the Institutional Ethical committee was obtained for publishing the study. All patients gave informed written consent prior to study.

Patients who were operated for benign goitres including toxic goitres and thyroid cancers were included in this study. The surgical findings were recorded in predesigned “Operation notes” register. Charts of the patients both male and female in the age range from 12 to 74 years were reviewed and operation notes analyzed. Required data regarding exploration of RLN and its relationship to ITA were retrieved. Data thus obtained were analyzed using SPSS - 16 for testing the significance of data, Pearson chi square was used as test of significance. A p - value of <0.05 was considered statistically significant.

Results

Out of total 200 patients, 74 were male and 126 were female. The age range of the patients was 12–74 years.

Table-I
Shows branching pattern of RLN and ITA.

	Right		Left	
	Non branching	Branching	Non branching	Branching
RLN	82%	18%	86%	14%
ITA	56%	44%	58%	42%

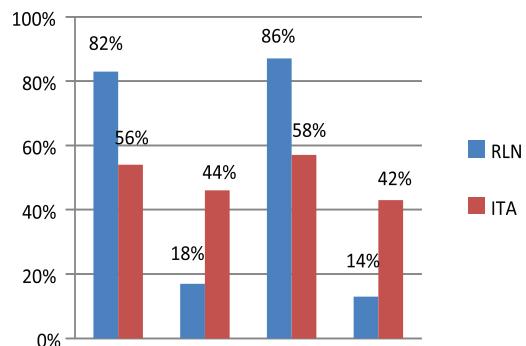


Fig.-1: Bar diagram of branching pattern of RLN and ITA

Table –II shows RLN ventral to the ITA 21.7% in right side and 22.5% in left side, dorsal to ITA 71.8% in right side and 74.5% in left side, In between branches of ITA 6.5% in right side and 3% in left side.

Table-II

Shows relationship between RLN and ITA

RLN	Non branching ITA	
	Right (%)	Left (%)
Ventral to ITA	21.7	22.5
Dorsal to ITA	71.8	74.5
Betweenbranches of ITA	6.5	3

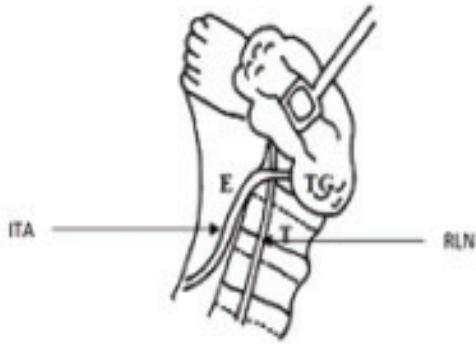

Fig.-2: Showing non branching RLN dorsal to ITA

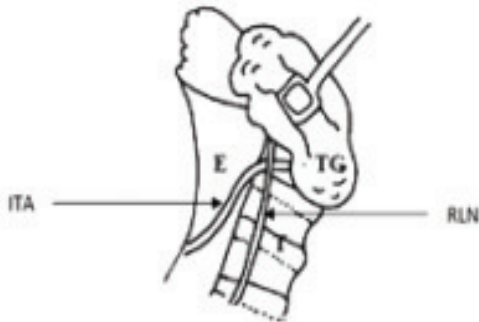


Fig.-3: Showing non branching RLN ventral to ITA

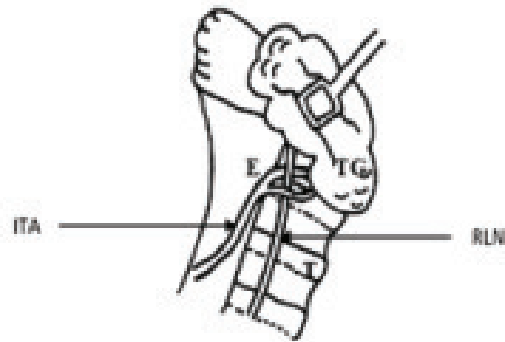


Fig.-4: Showing non branching RLN in between ITA

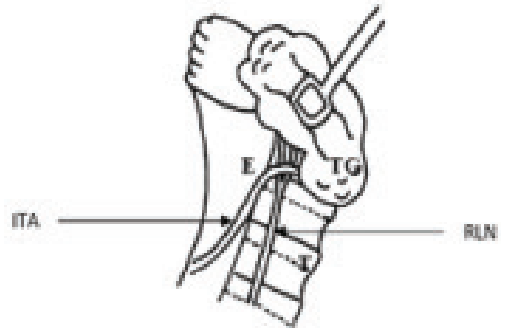


Fig.-5: Showing branching RLN dorsal to ITA

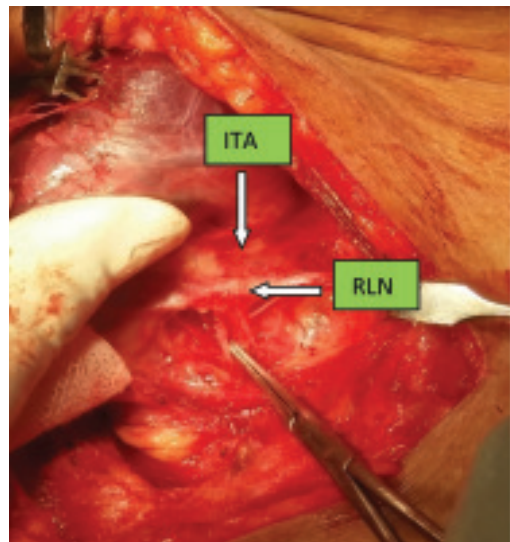


Fig.-5: Showing RLN passing dorsal to ITA (left side)

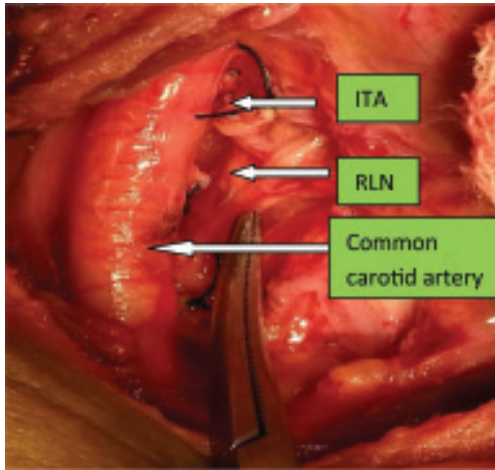


Fig.-6: Showing RLN passing ventral to ITA (right side).

Discussion

Due to high associated morbidity and mortality, thyroid surgery was limited to very few indications in the initial days of nineteenth century. Great evolution occurred with advent general anaesthesia and improved antiseptic measures. Also anatomical knowledge about the vital structures related to the gland improved. This brought down the complication rate associated with thyroid surgery. The morbidity of thyroid surgery has decreased to less than 1%.

Most authors recognize 3 types of relationships between the RLN and the ITA, as follows:^{2,12,13}

- a) RLN anterior to ITA
- b) RLN posterior to ITA
- c) RLN between branches of ITA.

The relationship of the RLN and ITA has shown a regional variation¹⁴. A study from China showed that 80% of right and 91.5% of left RLNs to travel posterior to ITA.¹⁵ A Brazilian study observed that in most instances RLN travel through the branches of ITA. Furthermore, absent ITA was detected in 4% instances.^{16,17}

Another variation described is a double ITA. Jiri Sedy reported a case of doubled ITA on the right side. He also found an accessory thyroid artery arises from subclavian artery.¹⁸ In present study no such variation was observed.

Rajamadhava et al¹⁹ reported that RLN on the right side was found posterior to ITA in 55% cases, anterior to ITA in 40% cases, in rest of the 5% cases RLN was in between branches of ITA. The left RLN was found posterior (70%) and anterior (20%) to left ITA and in between its branches in 7.5% cases.

Bakht zada et al²⁰ identified 398 nerves in 416 sides. they found RLN anterior to ITA in 55.27% cases, dorsal to ITA in 34.67% cases and in remaining 10.05% cases the RLN was in between branches of ITA.

In our study we found RLN has non branching pattern in 82% in right side and 86% in left side. It is branched in 18% in right side and 14% in left side. ITA has non branching pattern in 56% in right side and 58% in left side. It is branched in 44% in right side and 42% in left side. We found RLN ventral to the ITA 21.7% in right side and 22.5% in left side, RLN dorsal to ITA 71.8% in right side and 74.5% in left side, finally we observed RLN in between branches of ITA 6.5% in right side and 3% in left side.

Conclusion

The gold standard for preservation of the recurrent laryngeal nerve during thyroid surgery is still visual anatomical identification. Other techniques may be used only as an adjunct to the gold standard. Identification of the RLN and its branches should be done prior to the clamping of the ITA and all its branches. It can be identified in Behr's triangle, by tubercle of Zuckerkandle or in triangle of Lore.^{21,22} In a setting where advances in technology are not readily available, the surgeon must have adequate

knowledge about the variations in the neurovascular anatomy of the thyroid gland as well as necessary skill to prevent complications of surgery.

References

1. Friedman M, LoSavio P, Ibrahim H. Superior laryngeal nerve identification and preservation in thyroidectomy. *Arch Otolaryngology Head Neck Surg* 2002;128:296–303.
2. Yalacin B, Tubbs RS, Durmaz A, Comert A, Toygar M, Loukas M, et al. Branching pattern of the external branch of the superior laryngeal nerve and its clinical importance. *Clin Anat* 2012; 25:32–9.
3. Bowden RE. The surgical anatomy of the recurrent laryngeal nerve. *Brit J Surg* 1955;43:153–63.
4. Konstantinos Natsis, Matthaios Didagelos, Georgios Noussios, Aspasia Adamopoulou, Elisavet Nikolaidou, and Georgios Paraskevas, Combined anomalous origin of a left inferior thyroid artery and a left vertebral artery, (2009).
5. Pejkovic B. *Wien Klin Wochenschr.* An anatomical variation of the origin of the human right inferior thyroid and bronchial arteries. 2004; 116 Suppl 2:84-6.
6. Chandrakala SP, Mamatha., Thejaswini K.O. Variation in the origin of inferior thyroid artery and relation of the artery with recurrent laryngeal nerve. *National Journal of clinical anatomy*, 2013 Vol-2(1), page 11-15.
7. H Sunanda, S Tilakeratne, KPVR De Silva. Surgical anatomy of the recurrent laryngeal nerve; a cross-sectional descriptive study *Galle Medical Journal* Vol.15(1) 2010 pp.14-16.
8. Jonathan H. Sherman, Gene L. Colborn. Absence of the left inferior thyroid artery: Clinical implications. *Clinical Anatomy* Volume 16, Issue 6, pages 534–537, November 2003.
9. Morigyl B, Sturm W, Absence of three regular thyroid arteries replaced by an unusual lowest thyroid artery: A case report. *Surg Radiol Anat* 1996; 18:147-50.
10. Rao TR, Balakrishna R, Shetty PC, Suresh R. Ectopic thyroid tissue with a rare vascular variation. *Int J Morphol.* 2007; 25:121-124
11. Drake, Richard L.; Vogl, Wayne; Tibbitts, Adam W.M. Mitchell; illustrations by Richard; Richardson, Paul (2005). *Gray's anatomy for students*. Philadelphia: Elsevier/Churchill Livingstone. ISBN 978-0-8089-2306-0.
12. Aina E, Hisham AN. External Laryngeal Nerve in thyroid surgery: recognition and surgical implications. *ANZ J Surg* 2001; 71:212–4.
13. Berlin DD. The recurrent laryngeal nerves in total ablation of the normal thyroid gland - an anatomical and surgical study. *Surg Gynecol Obstet* 1935;60:19–26.
14. Kaplan EL, Salti GI, Roncella M, Fulton N, Kadowaki M. History of the recurrent laryngeal nerve: from Galen to Lahey. *World J Surg* 2009;33:386–93.
15. Costa Maag, CM, Oliveira EL. - Contribuição ao estudo das relações da artéria tireoideia inferior com o nervo laríngeo recorrente e o tronco simpático. *Rev Bras Cirurgia* 1997; 87(1):3–7.
16. Lekacos NL, Tzardis PJ, Sfikakis PG, Patoulis SD, Restos SD. Course of the

- recurrent laryngeal nerve relative to the inferior thyroid artery and the suspensory ligament of Berry. *IntSurg* 1992;77: 287–8.
17. Steinberg JL, Khane GJ, Fernandes MC, Neel JP. Anatomy of the recurrent laryngeal nerve: a redescription. *LaryngolOtol* 1986;100:919–27.
 18. Jiri Sedy, *International Journal of Anatomical Variations*, 2008; 1: 10-11.
 19. Rajamadhava R, Hussain Kafeel A, Swayam Jothi S, Hemanth Kommuru, Sujatha N. Variations in the course of superior and inferior thyroid arteries in relation to external & recurrent laryngeal nerves. *IOSR journal of dental and medical sciences*, vol14(6)2015, pp05-09.
 20. Zada B, Anwar K, Malik SA, Ullah N, Khan N, Salam F. Anatomical relationship between recurrent laryngeal nerve and inferior thyroid artery in thyroidectomy patients. *Journal of ayub medical college*. vol 26(3)2014.
 21. Schulte KM, Roher HD. Complications in the surgery of benign thyroid. *ActaChir, Austriaca*2001; 33(4):164-172.
 22. Yalcin B, Poyrazo"lu Y, Ozan H. Relationship between Zuckerkandl's tubercle and the inferiorlaryngeal nerve including the laryngeal branches. *Surgery Today*2007 Jan; 37(2)109–113.