

## Case Report

# Odontogenic Keratocyst of Coronoid Process Presenting as an Infratemporal Mass

G. Raju<sup>1</sup>

### Abstract

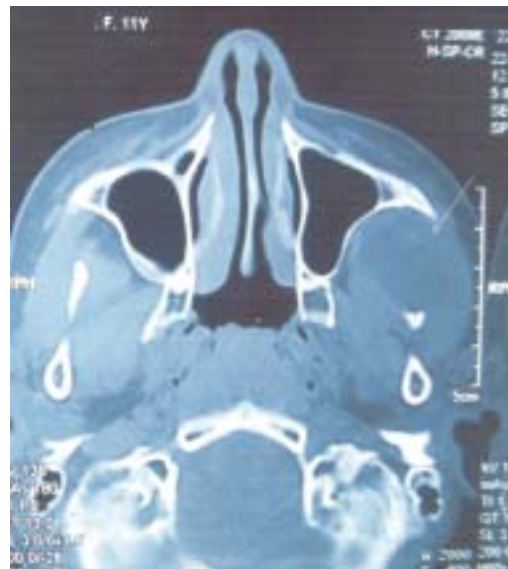
*A pediatric patient presented with facial swelling. CT scans showed a left infratemporal mass with erosion of coronoid process and normal dentition. CT guided FNAB suggested the possibility of odontogenic keratocyst. The mass was excised by a transzygomatic approach. A four year followup has not shown any recurrence. The possibility of odontogenic keratocyst needs to be considered while evaluating infratemporal fossa swellings.*

**Key words :** Infratemporal fossa, Odontogenic keratocyst, Coronoid process

### Case report

An eleven year old girl presented with painless progressive Left sided facial swelling since two months. There were no nasal, dental and ophthalmologic complaints. Examination showed an ill defined soft tissue swelling of the left infratemporal region. Nasal, ophthalmic, oral cavity and dental examinations were normal. Plain X-ray of the Para-nasal sinuses showed an ill defined soft tissue mass in the left infratemporal region with normal sinuses. A CT scan showed a soft tissue swelling of the left infratemporal fossa involving the masticator muscles with erosion of the coronoid process of the mandible (Figs 1 & 2). Oropharynx, paranasal sinuses, nasopharynx and pterygoid plates were normal. Orthopantogram showed normal dentition with destruction of left coronoid process of the mandible (Fig.3). Fine needle aspiration from the mass was inconclusive. Over a period of one month the swelling increased in size and the patient developed mild trismus. A CT guided aspiration revealed thick creamy pus that was sterile and was negative for AFB. A provisional

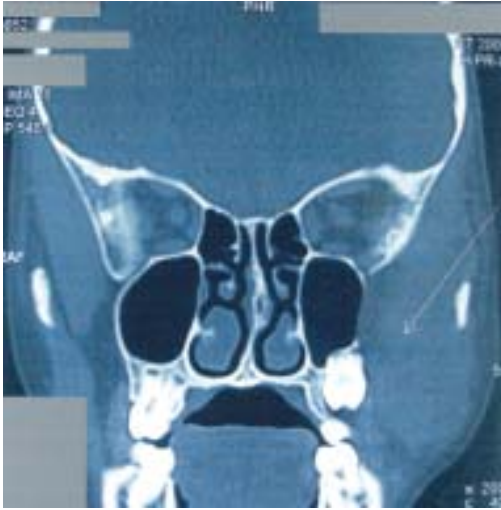diagnosis of an odontogenic keratocyst was made. The cyst was excised by a transzygomatic approach. The cyst was completely excised along with surrounding temporalis muscle. Remnant of the coronoid process was curetted. The patient had an uneventful recovery. Histological examination was characteristic of odontogenic keratocyst. In a four year follow up, there has been no recurrence.



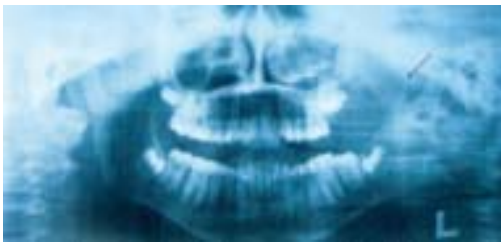
**Fig.-1.** Photograph of CT scan (coronal) showing the mass and destruction of left coronoid process of mandible (indicated by arrow)

Specialist, Department of ENT, ESIC Hospital  
K. K. Nagar, Chennai 600 078, India

**Address of Correspondence:** Dr. G. Raju, 4,  
Saravana Apartments, 348 T.T.K. Road, Alwarpet,  
Chennai 600018, India, Telephone: (0091-44)  
24981566, E-mail : shobraju@yahoo.com



**Fig.-2.** Photograph of CT scan (Axial) showing the mass and destruction of left coronoid process of mandible (indicated by arrow)



**Fig.-3.** Photograph of OPG showing destruction of left coronoid process of mandible (indicated by arrow)

### Discussion

Odontogenic keratocysts are not uncommon. It was first described by Philipsen in 1956.<sup>1,2</sup> WHO reclassified OKC as Keratocystic Odontogenic Tumor (KCOT) in 2005.<sup>2,3,4</sup> Odontogenic keratocysts arise from the remnants of dental lamina, also known as rests of Serres. Odontogenic keratocysts present as slow growing non specific cysts. Symptoms depend on the location of the cyst. Intraosseous cysts may present as a jaw swelling, loosening of teeth and pathological fracture of mandible. Multiple keratocysts are frequently associated with the bifid-rib, basal

cell nevus syndrome (Gorlin-Goltz syndrome).<sup>3</sup> These lesions have a peak incidence in second and third decades and occur rarely below ten years of age.<sup>2</sup> The clinical behavior in children is similar to the condition in adults.<sup>6</sup> and have a high recurrence rate ranging between 10 to 60%.<sup>2</sup> Odontogenic keratocysts occurring in the soft tissue of skull are usually caused by erosion of cortical plate of bone by aggressive lesions which extend into the soft tissues, skull base, zygoma, lateral orbital rim and temporalis muscle or recurrences after initial surgery.<sup>1,7</sup>

Odontogenic keratocysts of the infratemporal fossa usually are from extensions from the maxilla<sup>7</sup> and very rarely from the coronoid process of the mandible.<sup>1</sup> Primary extra osseous odontogenic keratocysts have only been rarely reported and present as gingival cysts.<sup>8</sup> Odontogenic keratocysts located primarily in the coronoid process of the mandible have hardly been reported in the literature. *Kružički* et al. seems to be the first who described these atypical case.<sup>4</sup> Primary tumors of infratemporal fossa are rare and comprise of Schwannomas, Neurofibromas, Rhabdomyosarcomas etc. Extensions into infratemporal fossa occur from tumors of maxilla and salivary glands. In this case, several of these possibilities were considered as differential diagnosis. The possibility of an odontogenic cyst or tumor was not initially considered of in view of clinically and radiologically normal dentition. Non contributory FNAB added to the problem of diagnosis. Pre operative histological confirmation of the lesion has been advocated by several authors.<sup>1,3</sup> Incisional biopsy for confirmation of pathology was not possible in this case due to the location of the swelling in the infratemporal fossa. Odontogenic keratocysts was considered only after a CT guided aspiration suggested the possibility of the condition.

Because of possible malignant transformation and high recurrence rates, radical en-block resection and close follow-up has been advocated.<sup>1</sup> In this case, besides radical excision, cosmetic consideration was also important in view of the age and sex of the patient.

Transzygomatic approach was considered as most suitable since the mass was confined to the infratemporal fossa and the coronoid process. Other approaches like trans-antral, trans-parotid and submandibular would not have provided sufficient access.

The case is reported for its rarity in pediatric age group and for its occurrence in the coronoid process of mandible. The possibility of odontogenic keratocyst needs to be kept in mind while evaluating swellings of infratemporal fossa.

There is no conflict of interest in the manuscript. Ethical approval for this manuscript is not required.

#### References

1. Jackson IT, Potparik Z, Fasching M, Schievink WI, Tidstrom K, Hussain K. Penetration of the skull base by dissecting keratocyst *Journal of Cranio-Maxillo-Facial Surgery* 1993;21:319–25
2. Peter R. Larsen in *Otolaryngology Head & Neck Surgery*, Charles W. Cummins. 4<sup>th</sup> edition Vol. 2 1511- 43
3. Mahadesh J, Kokila, Laxmidevi BL. Odontogenic Keratocyst of Maxilla Involving the Sinus – OKC to be a Cyst or a Tumour? *Journal of Dental Sciences & Research* 2010;1:2:83-90
4. Madras J, Lapointe H, Keratocystic Odontogenic Tumour: Reclassification of the Odontogenic Keratocyst from Cyst to Tumour: *J Can Dent Assoc* 2008;74(2):165-165h
5. Worrall SF Recurrent odontogenic keratocyst within the temporalis muscle. *British J Oral and Maxillofacial Surg* 1992;30:59 – 62
6. Preston RD, Narayana N. Peripheral odontogenic keratocyst *J Periodontol* 2005; 76(12):2312-5.
7. Meara JG, Li KK, Shah SS, Cunningham MJ. Odontogenic keratocysts in the pediatric population. *Arch Otolaryngol Head Neck Surg* 1996 ;122(7):725-8.
8. Brzozowski F, Wanyura H, Stopa Z, Kowalska K Odontogenic keratocysts in the material of the Department of Craniomaxillofacial Surgery, Medical University of Warsaw. *Czas. Stomatol* 2010; 63(2):69-78