

Original Article

Outcome of Endoscopic Third Ventriculostomy (ETV) in patients with Hydrocephalus of all age group-a single center study

Sultana MS¹, Rahman H², Roy R³, Bhuiyan TH⁴, Azad AK⁵, Ahmed S⁶

Conflict of Interest:

Funding Agency:

Contribution to Authors: Dr. Mst Shamima Sultana, Dr. Md. Habibur Rahman

Manuscript Preparation: Dr. Mst Shamima Sultana, Dr. Md. Habibur Rahman

Data Collection: Dr. Md. Abul Kalam Azad, Dr. Md Sharif Ahmed

Editorial Formatting: Dr. Rajkumar Roy, Dr. Tofael Hossain Bhuiyan

Copyright: @2022bang. BJNS published by BSNS. This article is published under the creative commons CC-BY-NC license. This license permits use distribution (<https://creativecommons.org/licenses/by-nc/4-0/>) reproduction in any medium, provided the original work is properly cited and is not used for commercial purposes.

Received: 25 Mar, 2024

Accepted: 24 May, 2024

Objective:

Endoscopic third ventriculostomy (ETV) is considered as a treatment of choice for obstructive hydrocephalus secondary to congenital aqueduct stenosis. It can also be done in post infective, normal pressure hydrocephalus, hydrocephalus secondary to posterior fossa tumor, myelomeningocele, and other causes. This study is done to evaluate the outcome of ETV in patients with hydrocephalus of all age groups.

Methods:

This study was done in the Department of Neurosurgery, Rangpur Medical College Hospital from the period of June 2017 to October 2023. Within this period ETV was done in fifty-nine patients with hydrocephalus from different etiologies in all age groups. Each case was properly evaluated by T2W axial and sagittal MRI of brain.

Results:

ETV was done in fifty-nine (59) patients with symptomatic HCP. Mean age was 15.38 ± 17.67 SD. Minimum age was 2 months and maximum 70 years. We did ETV below 6 months of age group in 5(8.5%) of cases. Between 6 months to 10 years 26(44.1%) and between 11-20 years 13(22%) patients. ETV was done under 20 years in 44(74.6%) patients, that represents maximum group of study population. In our study male was 26(44.1%) and female 33(55.9%) of patients. All patients were present with features of raised intracranial pressure.

Conclusion:

ETV is an effective treatment for selected patients with obstructive hydrocephalus. We can also do ETV in patients with myelomeningocele, post-meningitis HCP with obstructive component NPH and other etiology. It needs long-term follow-up to assess its failure rate.

Key words:

Endoscopic Third Ventriculostomy, Hydrocephalus, ventriculoperitoneal shunt.

Introduction

Hydrocephalus is the symptomatic accumulation of cerebrospinal fluid (CSF) inside the cerebral ventricles.[1] Hydrocephalus could be of 3 types- obstructive type, communicating type and complex hydrocephalus. Hydrocephalus, secondary to congenital aqueduct stenosis, posterior third ventricle tumor, cerebellopontine angle tumor, other posterior fossa tumors are of obstructive variety. Hydrocephalus following cerebellar infarct, Dandy- Waker malformation, syringomyelia with or without Chiari malformation, shunt malfunction,

encephalocele, craniosynostosis is usually of obstructive type. Myelomeningocele with hydrocephalus, slit ventricle syndrome and multiloculated hydrocephalus are also of obstructive hydrocephalus. Normal pressure hydrocephalus is of communicating variety. Some cases of hydrocephalus secondary to intraventricular hemorrhage, ventriculitis, meningitis and post-operative cases after complete excision of mass lesions are also of communicating variety.[2] Complex hydrocephalus is a variety of hydrocephalus when both the element of obstruction and the

1. Dr. Mst Shamima Sultana, Associate Professor, Department of Neurosurgery, Rangpur Medical College, Rangpur.
2. Dr. Md. Habibur Rahman, Associate Professor, Department of Neurosurgery, Rangpur Medical College, Rangpur.
3. Dr. Rajkumar Roy, Associate Professor, Department of Neurosurgery, Rangpur Medical College, Rangpur.
4. Dr. Tofael Hossain Bhuiyan, Professor and Head, Department of Neurosurgery, Rangpur Medical College, Rangpur
5. Dr. Md. Abul Kalam Azad, Associate Professor, Department of Medicine, Shaheed Monsur Ali Medical College, Sirajganj
6. Dr. Md Sharif Ahmed, Phase B Resident, Rangpur Medical College, Rangpur.

Correspondence to:

Dr. Mst Shamima Sultana, Associate Professor, Department of Neurosurgery, Rangpur Medical College, Rangpur, Bangladesh
E-mail: mstshamimasultana6@gmail.com

defect in the CSF absorption persist.[3]

Two commonly employed surgical procedures for the treatment of pediatric hydrocephalus are endoscopic third ventriculostomy (ETV) and ventriculoperitoneal shunt (VPS). Shunts are mechanical devices which are associated with numerous complications, for instance obstruction, failure, or infection. Unfortunately, there is an increased risk of mortality related to delayed recognition of shunt malfunction.[4]

Although ETV is indicated in selected patients in all types of hydrocephalus, the success of ETV in obstructive hydrocephalus is better than in communicating hydrocephalus. [2]

Materials and Methods:

Study design:

This is a retrospective study that was done in a single center; the Department of Neurosurgery, Rangpur Medical College Hospital from June 2017 to October 2023.

Study Population:

Those patients are admitted within this period and fulfill the inclusion criteria included within the study.

Inclusion criteria

- Patients above 2 months of age
- Favorable radiological selection criteria for ETV
- Obstructive HCP due to any pathology including posterior fossa tumor, CPA tumor, pineal region tumor, MM.
- Communicating HCP has obstructive components
- Patient with shunt malfunction
- HCP with visual problem

Exclusion criteria

- Patients below 2 months of age
- Unfavorable Radiology for ETV
- Patients are not willing to do this procedure.
- Active meningitis.

Pre-operative Work-up:

In all patients, first a CT scan of brain was done to detect the type of hydrocephalus (Obstructive/communicating). Then an MRI of brain done and in selected patients' IV contrast was given to detect the radiological criteria required for ETV.

Radiological selection criteria for ETV:

Patients were prepared for ETV after proper evaluation of T2W sagittal and axial MRI of brain (Figure-1). To assess:

- Anatomy of the floor of third ventricle,
- Width of foramen of Monro,
- Generous pre-pontine interval,
- Space anterior to mammillary bodies and
- Thickness of the floor of third ventricle.

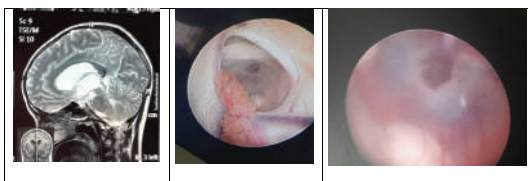


Figure 1: showing radiological criteria of patient selected for ETV(a), Endoscopic view of Foramen of Monro(b), After floor of third ventricle fenestration(c)

Equipment details for ETV:

We used Karl Storz Little Lotta ventriculoscope which is a wide angle straight forward telescope with a viewing angle of 6 degree. It has a working channel of 1.6 mm, two irrigation suction channels of 0.8 mm and its outer diameter is 3.6 mm. The benefit of this diameter is that we can do ETV even with a narrow Foramen of Monro. It also included an obturator with an operating sheath with an outer diameter 4.5 mm and 13.3 cm length. Ventriculostomy forceps are used to make fenestration in the floor of third ventricle having diameter 1 mm and length 30 cm. A Fogarty catheter 2F size is used to widen the fenestration in few cases. Bipolar coagulation electrode is occasionally used if any unusual bleeding occurs with a diameter of 1.3 mm and length 30 cm.

Surgical technique:

The trajectory of the scope was assessed from the image. A straight line from entry burr points up to the floor of third ventricle anterior to mammillary bodies. ETV performed in supine position with flexion of head so that the burr hole site comes at the highest point. The incision was linear. The location of burr hole was determined from image. It was roughly 3 cm lateral to midline and center was 1 cm anterior to the coronal suture in right side. Dura opened in a cruciate manner. Brain cannula was introduced to locate ventricle, to measure cortical distance and to maintain proper trajectory of endoscopic sheath. Floor fenestration is done by ventriculostomy forceps in midline, later it widened by Fogarty catheter(2F) approx. 4 mm. Preferable location in midline, the most transparent portion, anterior to the mammillary bodies and as possible posterior to the infundibular recess.

Follow up:

Patients with a minimum of 3 months to 1 year follow-up were included in the study. For these patients, we examined details of any subsequent hospitalization in the inpatient service. Analysis was then based on initial and subsequent hospitalizations for ETV or shunt. In follow up both improvement of previous features, reduction in the size of ventricles is assessed both clinically and radiologically in child and in adult. Radiological evaluation was done by doing MRI of brain and analyzing T2 images, any flow void across the floor of third ventricle is accepted as an indicator of patent stoma and good functioning ETV.

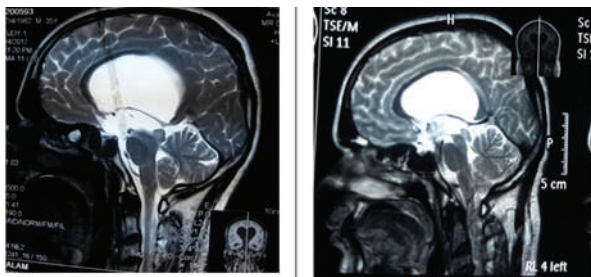


Figure-2: showing trajectory and preop T2 sagittal image in a patient with NPH. The second image shows flow void near the floor of the third ventricle indication patent ETV stoma.

Good outcome

This includes ETV success by resolution of the preoperative signs of raised ICP i.e., improvement in the level of consciousness, resolution of eye movement abnormalities, resolution of headaches, and reduction of the fontanelle tension (in infants). On follow up CT scan of brain criteria include decrease of the ventricular size over a period of three months. Most marked change is noted in cases of acute hydrocephalus and in reduction in size of the third ventricle (i.e., by 25%) [12].

Poor Outcome

ETV failure resulted in poor outcome. It is defined as subsequent surgery for hydrocephalus after primary surgery (i.e., repeat ETV or placement of ventriculoperitoneal shunt [VP shunt]) [5]. Inpatient deaths were noted, deaths following the procedure included as ETV failure but if died after surgery for other pathology were not included as ETV failure.

Statistical analysis:

The program used in our study was IBM SPSS 25. Quantitative data were analyzed using mean and standard deviation, while frequency and percentage were used with qualitative data. Pearson Chi-square test was used to analyze qualitative data. A P value ≤ 0.05 was considered statistically significant, while > 0.05 statistically insignificant.

Results:

Patients were divided into six age groups in this study (Table-1). The predominant age group was 6 months to 10 yrs and 11-20 years. Mean age was 15.38 ± 17.67 SD. Minimum age was 2 months and maximum 70 years. In our study male was 26(44.1%) and female 33(55.9%) of patients. Between 6 months to 10 yrs group ETV done in 26(44.1%) of patients, of them good outcome observed in 21 cases and poor in 5 cases.

Various parameter as age group, sex, requirement of VP shunt after ETV procedure, type of hydrocephalus and specific etiology was analyzed statistically for any association with outcome. Four parameters showed no strong association with outcome (statistically not significant). The only parameter show association in this study is the requirement of VP shunt after ETV procedure. Out of 59 patients, only 4 patients required revision VP shunt after this procedure, in these four patients' outcome was poor (Table-1).

Sl No	Parameter	n	%	Good Outcome	Poor Outcome	Fishers exact test, p-value
1	Age group					
	< 6 months	5	8.5	5	0	0.606
	6 months-10 yrs	26	44.1	21	5	
	11-20 yrs	13	22	12	1	
	21-30 yrs	5	8.5	4	1	
	31-40 yrs	4	6.8	3	1	
>41 yrs	6	10.1	5	1		
2	Sex					0.488
	Male	26	44.1	21	5	
	Female	33	55.9	29	4	
3	Post-procedure VP shunt					0.000
	Yes	4	6.8	0	4	
	No	55	93.2	50	5	
4	Etiology					0.816
	a. Congenital	25	42.4	22	3	
	b. Post-infective	5	8.5	5	0	
	c. NPH	3	5.1	3	0	
	d. Tumor with HCP	13	22.1	10	3	
	e. Shunt malfunction	11	18.6	8	3	
f. Post hemorrhagic	2	3.3	2	0		
5	Type of HCP					0.333
	a. Obstructive	49	83.1	40	9	
	b. Communicating	10	16.9	10	0	

Table 1: showing comparison of outcome with various parameter

In this study, patients presented with features of raised intracranial pressure as headaches in 44(74.6%), nausea and vomiting in 41(69.5%). Visual disturbance was present in the form of blurred vision in 35(59.3%). Infants have increased head circumference. Behavioral problems were present in 8(13.6%) of patients. Gait disturbance noticed in 25(42.4%). (Table 2)

Table-2: showing symptoms and signs of the study patients

Symptoms/signs	Frequency	percentage
Headache	44	74.6
Nausea/Vomiting	41	69.5
Visual disturbance	35	59.3
Increased OFC	22	37.3
Abnormal Behavior	8	13.6
Gait disturbance	25	42.4

We did ETV in different etiology. Congenital cause included primary aqueduct stenosis, Chiari I malformation with HCP, MM with HCP, cerebral palsy, arrested HCP, Arachnoid cyst which included 25(42.2%) of cases. Post-infective state as after sequelae of bacterial and tubercular meningitis with HCP, ETV done in 5(8.5%) cases and post hemorrhagic HCP in 2(3.3%). In 3(5.1%) of NPH patients ETV done. After the shunt malfunction ETV was done with removal of VP shunt in 11(18.6%) cases. Tumor as CP angle tumor, pineal gland tumor, third ventricular tumor ETV done in 13(22.1%). The outcome of ETV shows no association with etiology in this study.

In our study, a good outcome was observed in 50(84.7%) patients and a poor outcome in 9(15.3%) patients. But ETV was successful in 51 patients; one patient with successful ETV died after primary tumor surgery complications, so this included as poor outcome. (Table-3)

Table 3: showing outcome of patients in ETV success or failure group

Success /Failure	n	%	Good outcome	Bad outcome	Mortality
ETV success	51	86.8	50	1	1
ETV failure	8	13.6	0	8	4

In this study 5 patient expired, four died due to ETV failure. First case was 38 yrs old lady with CPA tumor and HCP; ETV was successfully done but after surgery she develop meningitis, despite all effort's patient died. Second case Huge HCP of an 8-month-old baby during the procedure mild bleeding occur, so EVD given after ETV, CSF over drainage. Third patient with shunt malfunction with HCP, ETV done with removal of shunt later intraventricular abscess develop and patient died. Our fourth case of an 8 yrs old girl with posterior fossa tumor and F/O raised ICP, ETV done on an emergency basis, procedure was uneventful but suddenly patient collapsed on the night of surgery. Our 5th case was a 60 yrs old patient CP angle tumor with HCP, ETV was successful, but the patient expired after primary tumor surgery.

ETV was done in 49(83.1%) cases of obstructive HCP and 10(16.9%) cases of Communicating hydrocephalus.

In this study the most common complication was fever in the immediate post-operative period that was resolved after broad spectrum antibiotic with aerobic and anaerobic coverage. It occurs in 12(20.3%) of patients. Meningitis develops in 3(5.1%) of them one patient of CP angle tumor with HCP died due to meningitis sequelae. CSF over drainage occurs in one child of 8 months of age because of insertion of EVD following ETV because of minor bleeding. In one Child of Shunt malfunction ETV done, later intraventricular abscess developed and after recovery repeat VP shunt was given. In 34(57.6%) of ETV patients' postoperative period was uneventful.

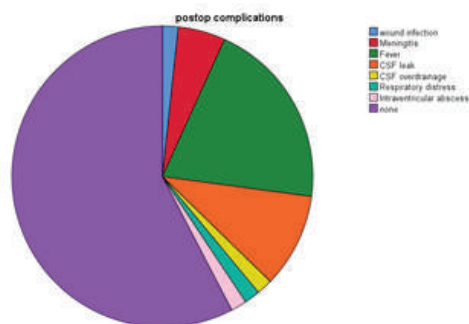


Figure 3: Pie chart for post-operative complications

Discussion:

In this study ETV was done in 59 patients of different age groups and different etiology. Special attention was given to the radiological selection criteria for ETV. Those patients fulfil the criteria irrespective of etiology ETV was done. Surgical techniques were also given priority as we assess the burr point from the pre-operative T2 sagittal section, a straight line from entry to the floor of third ventricle anterior to the mamillary bodies. In this series success rate was 88% in congenital causes as: primary aqueduct stenosis, Chiari Malformation with HCP and myelomeningocele with HCP. ETV was successful in 72.7% patients with shunt malfunction. But 100% success rate was achieved in NPH, post- hemorrhagic HCP and post-infective HCP.

Nayak et al.2015 observed 83.3% success rate in congenital (aqueduct stenosis), intracranial bleed and post infective etiologies. Whereas the success rate was 100 % in patients with shunt malfunction, tumor and posterior fossa lesion.[13]

In this study four (6.8%) patients required post-ETV procedure VP shunt, in all cases poor outcome observed. Nayak et al.2015 observed that those patients required postoperative shunting had good outcome in only 50% cases. Only 1 patient had wound related complications that led to a bad outcome.[13]

ETV is effective in all age groups including full-term normal birth weight infants.[15] Though some studies have reported poor results in infants younger than 3 months, the effectiveness has been related to etiology.[14] In our study we did ETV in 5(8.5%) patients aged under six months of age with 100% good outcome. Nayak et al.2015 in his study found that pediatric age groups (0-5 years) had a good outcome in 88.8%.[13] In this study ETV was done in 44(74.6%) up to 20 years of age with a good success rate of 86.4%. This study shows no association with age groups.

Obstructive hydrocephalus is the ideal indication for ETV, with congenital or acquired aqueduct stenosis showing the best results.[16] Other ones include communicating hydrocephalus with inferior bulging of floor and forward bowing of anterior wall of the third ventricle. Slit ventricle syndrome with upward ballooning of the floor of the third ventricle is also valid.[17] ETV can be safely performed in the chronic phase of TBM, [18,19,20] whereas it is difficult in acute stages.

In this study we did ETV in 49(83.1%) patients with obstructive HCP due to different etiology as congenital cause, tumor with HCP and shunt malfunction that having success rate 81.6%. In communicating HCP ETV was done in 10(16.9%) patients due to post-infective, post-hemorrhagic and NPH having 100 % success rate.

Variation in success rates of ETV may be associated with numerous factors, from patient factors, such as age and etiology of hydrocephalus, to provider factors such as surgeon/center experience and volume. In this study, age, gender, payer type, region, and etiology of hydrocephalus were not associated with ETV failure.[21] This study shows no association between age, sex with the outcome of ETV.

In this study we give more concentration on the radiological criteria for patient selection for ETV. So, we did this procedure in a wide range of etiology and in all age groups.

A generous prepontine interval (PPI) is generally accepted as an anatomical feature that may affect the safety and functionality of ETV. Patients with an obliterated or reduced PPI can safely undergo ETV as surgeons gain sufficient experience in endoscopy. [6,7]

The majority of ETV complications are centered around the procedure itself. The overall morbidity rate reported to range from 0 to 31.2%, the overall rate of permanent morbidity is 2.38% and mortality ranges between 0.28% and 1.28% [8-10]. In this study procedure related complications occur in one patient (1.7%), CSF was hazy after ETV procedure so a EVD (external ventricular drainage) was given. Mortality occurs in 4 patients (6.8%) that was procedure related. One patient was well after ETV procedure, but hospital death occurs after primary pathology (CP angle tumor) surgery. Nayak et al. 2015 in his study found overall mortality rate 21.6%(n=5). [13]

Some examples of such dreadful complications include meningitis, sepsis, thalamic injury, basilar artery injury. One of the major contributors to failure is loss of anatomical orientation which is frequently the result of altered anatomy caused by many diseases [11]. In this study post-operative fever developed in 12(20.3%) patients; that later resolved, CSF leakage in 6(10.2%) patients that spontaneously stopped. Meningitis developed in 3(5.1%) of patients with poor outcome in one patient. Nayak et al.2015 in his study experienced wound related complication with mortality in 1(4.3%) patient. In three patients (13%) the cause of mortality was aspiration pneumonitis and another one due to CSF metastasis.[13]

Nayak et al. 2015 in his study observed good outcome in 82.6% of patients and poor outcome in 17.4%. [13] In our study good outcome found in 84.7% cases and poor outcome in 15.3%.

Conclusions

ETV is an effective treatment for selected patients with obstructive hydrocephalus. We can also do ETV in patients with myelomeningocele, post-meningitis HCP with obstructive component NPH and other etiology. It needs long-term follow-up to assess its failure rate. Success rate of ETV depends on proper selection of cases on a radiological basis, with expertise in the procedure and also on etiology.

References:

1. Rekate HL. A contemporary definition and classification of hydrocephalus. *Semin Pediatr Neurol.* 2009 Mar;16(1):9-15.
2. Yadab YR, Parihar V, Pande S, Namdeb H & Agarwal M. Endoscopic third ventriculostomy. *J Neurosci Rural pract.* 2012 May-Aug;3(2): 163-173.
3. Yadav YR, Mukerji G, Parihar V, Sinha M, Pandey S. Complex hydrocephalus (combination of communicating and obstructive type): An important cause of failed endoscopic third ventriculostomy. *BMC Res Notes.* 2009; 2:137.
4. Wright Z, Larrew TW, Eskandari R (2016) Pediatric hydrocephalus: current state of diagnosis and treatment. *Pediatr Rev* 37(11):478–490
5. Buxton N, Ho KJ, Macarthur D, Vloeberghs M, Punt J, Robertson I. Neuroendoscopic third ventriculostomy for hydrocephalus in adults: report of a single unit's experience with 63 cases. *Surg Neurol.* 2001; 55:74–8. [PubMed: 11301084]
6. Souweidane MM, Morgenstern PF, Kang S, Tsiouris AJ, Roth J. Endoscopic third ventriculostomy in patients with a diminished prepontine interval. *J Neurosurg Pediatr.* 2010; 5:250–4.
7. Warf BC, Campbell JW, Riddle E. Initial experience with combined endoscopic third ventriculostomy and choroid plexus cauterization for post-hemorrhagic hydrocephalus of prematurity: The importance of prepontine cistern status and the predictive value of FIESTA MRI imaging. *Childs Nerv Syst.* 2011; 27:1063–71.
8. Bouras T, Sgouros S. Complications of endoscopic third ventriculostomy: a systematic review. *Acta Neurochir Suppl.* 2012; 113:149–53.
9. Bouras T, Sgouros S. Complications of endoscopic third ventriculostomy. *World Neurosurg* 79: S22.e9-S22.e12, 2013.
10. Kawsar KA, Haque MR, Chowdhury FH. Avoidance and management of perioperative complications of endoscopic third ventriculostomy: the Dhaka experience. *J Neurosurg.* 2015; 123:1414–9.
11. Zohdi A. Brain endoscopy in hydrocephalus the role of intracranial endoscopy in the management of hydrocephalus dos and don'ts (Doable or Not?). Tuttligen: Verlag Endo-Press; 2008.
12. Santamarta D, Martin-Vallejo J, Díaz-Alvarez A, Maillo A. Changes in ventricular size after endoscopic third ventriculostomy. *Acta Neurochir (Wien)* 2008; 150:119–127. discussion 127.
13. Nayak MT, Kamath V. Outcome of endoscopic third ventriculostomy: analysis of first 23 cases. *International Journal of Advances in Medicine* 2015;2: 94-99.
14. Yadab YR, Bajaj J, Ratre S, Yadab N, Parihar V, Swamy N, et al. Endoscopic third ventriculostomy -A Review. *Neurol India* 2021;69: S502-13.
15. Yadav YR, Jaiswal S, Adam N, Basoor A, Jain G. Endoscopic third ventriculostomy in infants *Neurol India.* 2006; 54:161–3
16. Moorthy RK, Rajshekhar V. Endoscopic third ventriculostomy for hydrocephalus: A review of indications, outcomes, and complications *Neurol India.* 2011; 59:848–54
17. Yamaguchi J, Watanabe T, Nagata Y, Nagatani T, Seki Y. Upward ballooning of the third ventricle floor in a patient with slit ventricle syndrome: A unique magnetic resonance imaging finding *Neuroradiol J.* 2017;30:62–4
18. Yadav YR, Parihar VS, Todorov M, Kher Y, Chaurasia ID, Pande S, et al Role of endoscopic third ventriculostomy in tuberculous meningitis with hydrocephalus *Asian J Neurosurg.* 2016; 11:325–9
19. Bajaj J, Yadav YR, Parihar V, Ratre S, Swamy MN, Sinha M, et al. Endoscopic third ventriculostomy in tuberculous meningitis *Neuroendoscopic Surgery: A Comprehensive Approach.* 2020 1st Salubris Medical Publishers:47–51
20. Yadav YR, Yadav N, Parihar V, Ratre S, Bajaj J, Mehmet Turgut, et al Role of endoscopic third ventriculostomy in Tuberculous Meningitis with Hydrocephalus Tuberculosis of the Central Nervous System: Pathogenesis, Imaging, and Management. 2017 1st Springer International Publishing AG:429–46
21. Lam S, Harris D, Lin Y, Rocque B, Ham S and Pan IW. Outcome of Endoscopic third ventriculostomy in adults. *J Clin Neurosci* 2016 September; 31: 166-17.