

# Idiopathic Lobular Panniculitis with Extensive Hypermetabolic Lesions in FDG PET-CT Scan: Case Report

Afroza Akhter<sup>1</sup>, Byeong-Cheol Ahn<sup>2</sup>, Chae Moon Hong<sup>2</sup>

<sup>1</sup>Institute of Nuclear Medicine and Allied Sciences, Dhaka, Bangladesh

<sup>2</sup>Department of Nuclear Medicine, Kyungpook National University Hospital, Daegu, Republic of Korea

**Correspondence Address:** Dr. Afroza Akhter, Assistant Professor & SMO, Institute of Nuclear Medicine and Allied Sciences, Dhaka, BAEC, Bangladesh, Email: afrozaainmas@gmail.com, telephone: +8801816404873

## ABSTRACT

Panniculitis indicates 'inflammation of fat tissue'. Idiopathic Lobular Panniculitis is a rare condition in which inflammation occurs in the subcutaneous tissue, just beneath the skin. It is predominantly observed in women in the age group of 30-60 years. Occasionally, children may also be affected. We report a case of a 57 years old woman, who presented with multiple palpable skin lesions in both thigh, upper arms, breast and facial site specially left cheek and submandibular area. All of her laboratory findings including hematological and biochemical parameters were normal except slightly low white blood cell count. <sup>18</sup>FDG PET-CT revealed multiple hypermetabolic lesions in the subcutaneous layer of skin and fat layers of the retroperitoneum. Diagnosis was confirmed by surgical biopsy which was reported as lobular panniculitis. Distinguishing true malignant cutaneous and subcutaneous benign might be difficult, but when lesions show high uptake of FDG, it can be related to an active inflammation. Extensive FDG uptake in a benign case like this is rare. Therefore, <sup>18</sup>FDG PET-CT is not only helpful in detecting panniculitis but also feasible for identifying active state of the disease.

**Key words:** Panniculitis, FDG-PET CT.

Bangladesh J. Nucl. Med. Vol. 24 No. 1 & 2 year 2021

**Doi:** <https://doi.org/10.3329/bjnm.v24i1-2.59337>

## BACKGROUND

As the clinical use of <sup>18</sup>FDG PET-CT is increasing, Nuclear Medicine (NM) physicians are encountering most of the cutaneous and subcutaneous lesions, the most common cause being inflammation (1, 2). Inflammatory tissue shows increased cellular oxygen and glucose utilization. This manifests as hypermetabolic foci on PET imaging. Inflammatory processes involving fat lobules, lobular panniculitis, may also demonstrate intense hypermetabolism on FDG-PET imaging (3,4). Panniculitis is a group of diseases whose hallmark is inflammation of subcutaneous adipose tissue and characterized by one or multiple, recurrent, subcutaneous nodules. It is associated with acute systemic symptoms such as fever, generalized malaise and abdominal pain. It is also known as idiopathic

relapsing febrile lobular non-suppurative panniculitis as the cause is unknown. Immunologic, traumatic, metabolic, paraneoplastic and infectious causes have been also implicated for lobular panniculitis. Other important causes of lobular panniculitis include systemic lupus erythematosus,  $\alpha$ 1-antitrypsin deficiency, lymphoma, trauma, pancreatitis, and certain types of infections (5, 6). Panniculitis also tend to occur in patients with malignancy (7). Diagnostic tool for idiopathic lobular panniculitis includes complete physical examination with comprehensive evaluation of medical history. Blood tests to detect serum amylase and lipase levels. Sometimes CBC with differentials count may show low white cell count and decreased hemoglobin (anemia). Blood electrolyte may reveal abnormal levels. Erythrocyte sedimentation rate (ESR) and C-reactive protein levels may be increased. Sometimes it may reveal abnormal liver function test. Depending upon the organ involved further studies such as chest x-ray, CT, or MRI can be done. Deep skin biopsy is the confirmatory test. For suspicious lesion <sup>18</sup>F-FDG PET-CT findings can be feasible for distinguishing active inflammation from stable condition.

## CASE REPORT

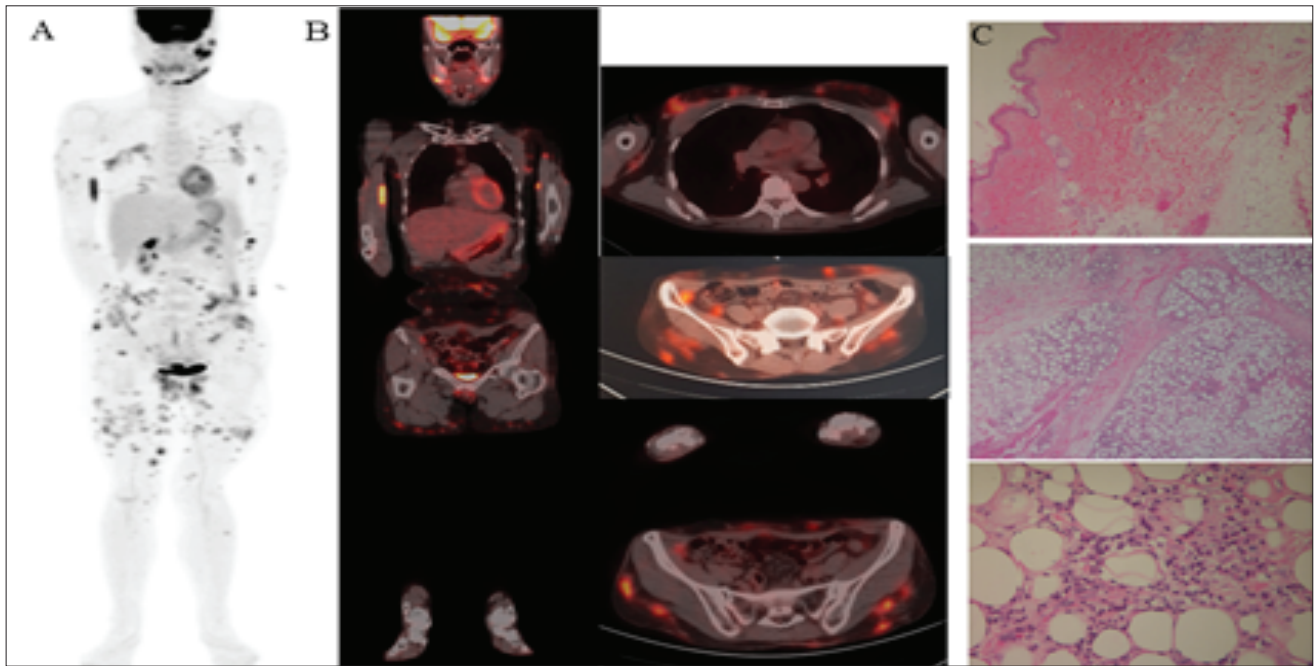
A 57 years old woman presented with multiple palpable skin lesions in both thighs, both upper arms, both breasts and face especially left cheek and submandibular area with the complains of morning stiffness, fever for two months, photosensitivity, multiple skin rashes and recurrent oro-genital ulcer. Laboratory findings show slightly low white blood cell count ( $4.54 \times 10^3/\mu\text{L}$ ), hemoglobin (13.2 g/dl), ESR (14mm/hour), CRP (<0.1) and Differential count (65.1% segmented neutrophils, 24.8% lymphocytes, 7.5% monocytes, 0.8% eosinophil and 0.5% basophil). Other biochemical parameters including serum lipase and

amylase level were normal. Chest CT scan revealed no active lung lesion, only dermal thickening in the right upper breast area and soft tissue thickening in the left upper outer breast area. In abdominal CT there were multiple nodular soft tissue lesions in subcutaneous fat layer. In MRI there was multiple ill-defined enhancing nodular lesions in subcutaneous fat layer and an infiltrating soft tissue lesion in the anterior aspect of left iliacus muscle.  $^{18}\text{F}$ FDG PET-CT was also done for the diagnosis of suspicious skin lesions. It revealed multiple hypermetabolic lesions in subcutaneous layer of skin and fat layers of the retroperitoneum (SUV max: 12.8). Immuno-histochemistry for lymphoma and special stains for microorganisms were negative. IgG4 level was within normal limit (207 mg/L, Normal range: 30-2010 mg/L). Differential diagnosis were cutaneous T cell lymphoma /IgG4 related disease / idiopathic lobular panniculitis (Weber Christian disease) / Lupus panniculitis. As initial infectious diagnostic evaluation was not concluding, skin biopsy was taken from two different sites. Biopsy from right thigh area showed lobular panniculitis with presence of predominantly lymphocytes and plasma cells. Another biopsy from the soft tissue of right chest wall revealed the sign of chronic inflammations with heavy infiltrations of lymphocytic-plasma cells. Immuno-histochemistry for

lymphoma and special stains for microorganisms were negative. Patient was diagnosed as a case of lobular panniculitis by skin biopsy and was treated with high dose steroid and azathioprine with good response.

## DISCUSSION

Etiology of nodular panniculitis is unknown. There is one hypothesis that explains that fat may trigger an autoimmune or autoinflammatory granulomatous reaction. In this reaction, white blood cells infiltrate and damage the subcutaneous fat, causing necrosis and fibrosis. Inflammatory processes involving fat lobules in lobular panniculitis, demonstrate intense hypermetabolic uptake on FDG-PET imaging. Though FDG-PET has been shown to have high sensitivity and specificity in the assessment of malignancy, there are some false-positive benign FDG-avid conditions like reactive nodes; inflammation related to injection, immunization, trauma, biopsy, surgery, chemotherapy or radiotherapy, variations of physiological uptake, granulomatous inflammation; and acute and chronic infection such as TB, fungal infection, toxoplasmosis, etc (8). There was no history of trauma in this case. Metabolically active fat, i.e, brown fat usually demonstrates typical symmetric distribution in the supraclavicular and paravertebral regions, in the neck and in the axillae (9).



**Figure 1 :** FDG PET-CT scan showing multiple hypermetabolic lesions in subcutaneous layer of skin and fat layer of retroperitoneum, SUVmax 12.8 (A: MIP image and B: coronal and axial views). Histopathology slides showing inflammatory lymphocytic infiltration in the subcutaneous adipose tissue consisting with lobular panniculitis (image C: H&E original magnification x 40,200,400).

Sometimes panniculitis tend to occur in patients with malignancy. Subcutaneous Panniculitis-Like T-Cell Lymphoma (SPTCL) is one of the differential diagnosis for idiopathic lobular panniculitis. Immunohistochemical staining and flow cytometry work-up for positive aberrant T-cell population like CD2, CD3 and CD8 with a partial loss of CD5 and CD7 can differentiate SPTCL from idiopathic lobular panniculitis (10). Immunohistochemistry for lymphoma and special stains for microorganisms were also negative in this reported case. Changes in liver function test, CBC count, and electrolyte levels reflect visceral involvement of organs, including the lungs, heart, intestines, spleen, kidneys, and adrenal glands in patients with idiopathic lobular panniculitis / Weber-Christian disease. Patients may present with a leukocytosis or leukopenia, anemia, or hypocomplementemia. Erythrocyte sedimentation rate (ESR) and C-reactive protein (CRP) are usually elevated, although the degree of elevation varies. Serum and urine amylase and lipase levels are usually within the reference ranges, differentiating Weber-Christian disease from a panniculitis associated with pancreatic disease. We can also differentiate Weber-Christian disease from alpha1-antitrypsin panniculitis by measuring alpha1-antitrypsin level.

Reported patient had all other biochemical reports were within normal limit. Before biopsy, the only positive finding was hypermetabolic lesions in subcutaneous layer of skin and fat layers of the retroperitoneum detected by FDG PET-CT. Though we confirmed our diagnosis by surgical biopsy, FDG PET-CT played an important role for the suspicious subcutaneous hypermetabolic lesions.

## CONCLUSION

FDG PET-CT can play an important role for the diagnosis of panniculitis like subcutaneous disease as well as guiding the biopsy and follow up evaluation. As the lesions are <sup>18</sup>F-FDG-avid, they could be misinterpreted as

metastatic involvement. Therefore, biopsy is advisable to confirm the uncertain diagnosis. Careful clinical correlation can often resolve the true etiology of many of these hyper-metabolic foci.

## Acknowledgement

This study was supported by a grant from KOICA (Korea International Cooperation Agency) Fellowship Program 2018.

## REFERENCES

1. Priyanka Verma, Sumit Gujral, Ramesh V Ashopa-Spontaneous Resolution of Idiopathic Panniculitis: Role of <sup>18</sup>F-Fluorodeoxyglucose Positron Emission Tomography/Computed Tomography in Diagnosis and follow-up; Indian J Nucl Med. 2018 Jul-Sep; 33(3): 248-249
2. Metser U, Tau N. Benign cutaneous and subcutaneous lesions on FDG-PET/CT. Semin Nucl Med 2017;47:352-61.
3. Yen RF, Shun CT, Pan MH, et al. FDG PET manifestation of lobular panniculitis. Clin Nucl Med. 2004; 29:442-443.
4. Blumer, Steven L. MD\*; Scalcione, Luke R. MD\*; Ring, Bobbi N. MD†; Johnson, Ravi RTN, CNMT\*; Motroni, Betty MD‡; Katz, Douglas S. MD\*; Yung, Elizabeth Y. MD; Cutaneous and Subcutaneous Imaging on FDG-PET: Benign and Malignant Findings; Clinical Nuclear Medicine: October 2009 - Volume 34 - Issue 10 - p 675-683; doi: 10.1097/RLU.0b013e3181b53845.
5. Michael P, Gratiot J. Mesenteric panniculitis associated with trauma. Calif Med. 1964; 100:285-287.
6. Requena L, Sanchez YE. Panniculitis. Part II. Mostly lobular panniculitis. J Am Acad Dermatol. 2001; 45:325-361. doi: 10.1067/mjd.2001.114735.
7. Yunyun Zhao, Qian Wang et al. 18FDGPET CT findings of panniculitis and its feasibility for distinguishing active inflammation from stable conditions; J Nucl Med May 1, 2017 vol. 58 no. supplement 1 1210.
8. <https://radiologykey.com/18f-fdg-petct-normal-variants-artefacts-and-pitfalls-in-lymphoma>.
9. Alkhalwaldeh K, Alavi A. Quantitative assessment of FDG uptake in brown fat using standardized uptake value and dual time point scanning. Clin. Nucl. Med. 2008; 33:663-667.
10. Barbara Bennani-Baiti, Siddhartha Yadav and Lesley Flynt, Nabila Bennani-Baiti; Value of Positron Emission Tomography in Diagnosing Subcutaneous Panniculitis-Like T-Cell Lymphoma; Journal of Clinical Oncology 33, no. 10 (April 2015) 1216-1217. DOI: 10.1200/JCO.2014.59.8193.