

# Choroidal Metastasis from Follicular Thyroid Carcinoma: A Rare Case Report

Md. Sunny Anam Chowdhury and Md. Abdul Awal

Institute of Nuclear Medicine and Allied Sciences, Bogra

**Correspondence Address :** Md. Sunny Anam Chowdhury ,Senior Medical Officer ,Institute of Nuclear Medicine and Allied sciences ,GPO Box # 61, Mohammad Ali Hospital Campus, Bogra, E-mail: drsunny43@gmail.com

## ABSTRACT

**Follicular thyroid carcinoma is the second most common thyroid carcinoma and causes distant metastasis more frequently than any other types. Choroidal metastasis from follicular thyroid carcinoma is extremely rare. Only a few cases have been reported since 1979. We present the case of a 60 years old woman developing choroidal metastasis with associated local (lymph nodes) and distant (lungs) metastasis after nine years of diagnosis as primary follicular carcinoma.**

**Key words:** Choroidal metastasis, distant metastasis, metastatic follicular carcinoma, orbital metastasis.

## INTRODUCTION

Follicular thyroid carcinoma is the second most common types of thyroid cancer accounts for approximately 11% of thyroid cancers (1). It is well documented that distant metastasis is more common in follicular carcinoma than any other thyroid cancers. Hematogeneous spread is the most common route for metastasis of follicular thyroid carcinoma and bone, lung, brain, skin and adrenal glands are the common sites of metastasis (2). Metastases of thyroid carcinoma to the choroid and/or orbit are infrequent and constitute about 5-6.5% of total orbital malignancy (3,4). From 1979 to 2012, 31 cases of choroidal and orbital metastases of thyroid carcinoma were reported and among them 22 cases were choroidal metastases and nine were orbital metastases. Among 22 cases of choroidal metastases, seven patients had papillary carcinoma, six patients had medullary carcinoma and five patients had follicular carcinoma of thyroid. On the other hand, among nine cases of orbital metastases four patients had papillary carcinoma, three patients had follicular carcinoma, one

patient had Hürthle cell carcinoma and one had non-specified thyroid carcinoma. Almost all the patients had a long history of carcinoma and evidence of other distant metastases (5).

Differentiated thyroid cancer patients from different areas of Bangladesh attend to all nuclear medicine institutes of the country for radioiodine therapy and subsequent managements. As far our knowledge only one case of orbital metastasis from follicular variant of papillary carcinoma was reported in National Institute of Nuclear Medicine and Allied Sciences, BSMMU campus by the year 2010 (6). We report another case of a 60 years old female patient, who was diagnosed as follicular carcinoma of thyroid gland nine years ago and recently presented with metastasis in choroid of her right eye with associated local lymph nodes and bilateral lungs metastases.

## CASE REPORT

A 60 years old female patient of low socio-economic condition from a rural area of northern part of Bangladesh was histopathologically diagnosed as a case of follicular carcinoma of thyroid nine years back after right sided hemithyroidectomy. After three months she underwent a completion surgery. The unfortunate woman did not take any radioiodine ablation therapy following surgery and was not under regular follow-up. She irregularly took 150 microgram of levothyroxine. After eight years following last surgery she developed recurrence of carcinomatous thyroid tissue at thyroid bed and bilateral multiple lymph nodes metastasis. Then another completion

surgery with neck clearance was done. She was advised for radioiodine ablation in a nuclear medicine institute but the patient's party ignored. After ten months following the third surgery she came to Institute of Nuclear Medicine & Allied Sciences, Bogra with the complaints of neck swelling, dysphagia, cough and pain with blurring of vision in right eye. On examination, palpable irregular masses firm in consistency found in thyroid bed. Few enlarged lymph nodes are also found along both sided anterior cervical chains, supra-sternal and left supraclavicular regions. Ultrasonography of neck revealed multiple foci of significant residual thyroid tissue in thyroid bed and multiple enlarged lymph nodes of variable sizes along bilateral anterior cervical chains, suprasternal and bilateral supra-clavicular regions. Her thyroglobulin level was found 21.6 ng/ml, TSH level was 3.8 m IU/L even though she didn't took levothyroxine for last two months. A whole body iodine scan showed (Figure 1) multiple foci of increased radiotracer at thyroid bed indicating significant residual thyroid tissue. There was also diffusely distributed radiotracer seen along both lung fields indicating bilateral lung metastasis. Fine needle aspiration from left supraclavicular and suprasternal lymph nodes revealed metastatic deposit from follicular carcinoma of thyroid. An ocular ultrasonography of right eye was performed and sonographic scan showed a 9.6x6.7 mm irregular mass like area arising from left lateral part of choroid of right eye (Figure 2). Ophthalmoscopic examination of right eye also showed an irregular choroidal mass close to the optic disc (Figure 3). Patient was sent for USG guided FNAC from the orbital mass and the result showed metastasis from follicular thyroid carcinoma. We consulted with a radiation oncologist and the oncologist suggested about external-beam radiotherapy for right eye followed by radioiodine therapy after excision of lymph nodes.

## DISCUSSION

The Choroid is the vascular layer of the eye, containing connective tissues and lying between the retina and the sclera, originated embryonically from neural crest ectoderm and nourishes the outer retina and a portion of the optic nerve. Blood flow in the choroid is very high, thus it provides a vascular avenue for tumor emboli to sequester and allows an environment receptive to growth (7, 8). This characteristic makes the choroid the most common ocular metastatic site especially for those carcinomas that spread in haematogenous route.

The primary cancer that most commonly lead to choroidal metastasis is breast cancer, accounting 40-53% and the second most common primary tumor is lung cancer, accounting 20-29% of cases. Other less common sources are gastrointestinal tract (4%), prostate (2%), kidney (2-4%) and skin (2%). Besides primary carcinomas reported metastasizing to choroid include tumors arising from submandibular gland, thyroid, testes, ovaries, urothelial tract, neuroendocrine tumor and sarcoma (8).

Metastases of thyroid carcinomas to the choroid and/or orbit are rare. A survey on English-language articles and case reports published from 1977 to 2012 found 31 cases of orbital and/or ocular metastases from thyroid gland and among them 22 cases were choroidal metastases. Among the 22 cases, most common primary tumor was papillary thyroid carcinoma, occurred in seven cases. There were six cases metastasized from medullary thyroid carcinoma and five cases from follicular thyroid carcinoma (5). In our case, choroidal metastasis occurred from follicular thyroid carcinoma.

Hematogeneous spread is the most common route of metastasis from follicular carcinoma and distant metastasis occur more frequently to bone, lung, brain, skin and adrenal gland (2). In all previously reported cases of follicular thyroid carcinoma metastasis to

choroid, patient presented with coexisting metastasis to bones or lungs (5, 9). In our case, the patients had also coexisting metastasis to local lymph nodes and both lungs. The age of patients' ranges between 50 - 83 years with no sex predilection as reported previously and almost all the patients had a long history of thyroid carcinoma at the time of ocular presentation (5, 9). In this case, the 60 years old female patient unfortunately did not take any iodine  $^{131}\text{I}$  ablation therapy after first completion surgery nine years back. The patient's party again ignored a radioiodine therapy following another completion surgery and neck clearance due to recurrence and local lymph nodes metastasis after eight years of first diagnosis. After nine years of diagnosis of primary follicular thyroid carcinoma she presented with distant metastasis to both lung fields and choroid of right eye.

Presenting symptoms of choroidal metastasis were reported as decreased or blurring of vision, pain in eye and flashes in 81%, 5% and 5% cases respectively. However, patients were asymptomatic in 9% of cases and lesions may be found on routine ocular examination (5, 8). In this case, pain and blurring of vision were the presenting complaints of our patient that support previous observations.

Ophthalmological examination including assessment of vision and ultrasonography should be the first line investigations after a suspicious complaint of choroidal metastasis as they are easily available and noninvasive procedure and free from radiation hazards. They can give information about unilateral or bilateral involvement, sites, appearance and number of metastatic focus. In majority of choroidal metastasis from thyroid carcinoma cases (80%) there were unilateral single focuses (8). Ophthalmoscopic examination of our patient revealed a single focus of irregular choroidal mass close to the optic disc. Ocular ultrasonographic scan showed solid irregular mass arising from left lateral part of choroid. Different tomographic imaging techniques such as CT scan or

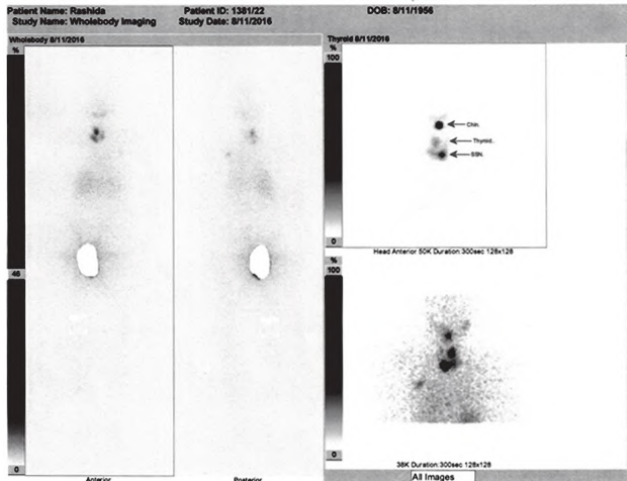
MRI should be applied to evaluate tumor extension (8). A biopsy or fine-needle aspiration should be recommended to confirm the origin of the tumor. In our case, CT scan or MRI was not done but a FNAC suggested metastatic follicular carcinoma of thyroid gland. It is reported that a whole body  $^{131}\text{I}$  scanning reveals uptake in the orbit in 26% of choroidal and/or orbital metastasis from papillary or follicular carcinoma of thyroid (5). But in this case no uptake was seen in orbital region in  $^{131}\text{I}$  whole body scan. However, uptake in thyroid bed and bilateral lung fields indicated recurrence and lung metastases respectively.

Enucleation is the treatment of choice in choroidal and/or orbital metastases that cause loss of vision and/or persistent pain. Brachytherapy with  $^{125}\text{I}$ -episcleral radioactive plaque insertion, external beam radiation,  $^{131}\text{I}$  therapy, chemotherapy and/or targeted therapy with small molecules are other treatment options (5). Few researchers reported a dramatic response to radioiodine therapy and complete regression of  $^{131}\text{I}$ -avid choroidal lesion within few months (9). In case of non  $^{131}\text{I}$  avid metastatic deposit cure by radioiodine therapy was unlikely but reduction of the size of the lesion and improvement of vision was also reported in few cases (7). External beam radiotherapy is reported to cause tumor regression in 85-93% of patients with vision improvement or stabilization in 56% of eyes (8). In this case, we decided to treat the metastatic patient with high dose of radioiodine therapy for distant metastasis (lungs) after excision of lymph nodes and before radioiodine therapy local external beam radiotherapy was decided by oncologist to reduce choroidal mass size as it was a non  $^{131}\text{I}$  avid lesion.

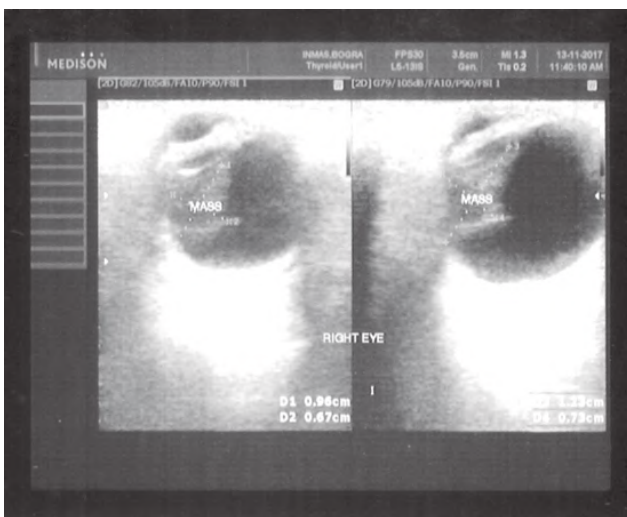
## CONCLUSION

Although it is extremely rare, the possibility of choroidal metastasis should be considered in case of pain or visual disturbance in patients with long history

of thyroid carcinoma and periodic ocular examination is necessary to detect such cases earlier. To reduce such complications early detection of thyroid carcinoma and appropriate treatment should be the main target.

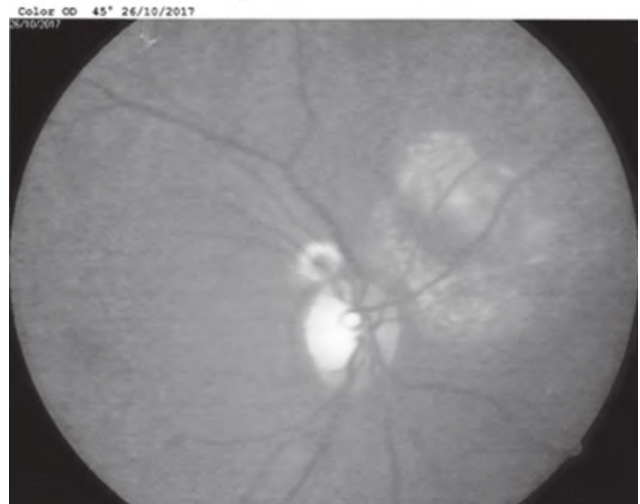


**Figure 1: Whole body <sup>131</sup>I scan showing multiple foci of increased radiotracer at thyroid bed indicating significant residual thyroid tissue. There was also diffusely distributed radiotracer seen along both lung fields indicating bilateral lung metastasis.**



**Figure 2: Ultrasonographic scan showing a 9.6x6.7 mm irregular mass like area arising from left lateral part of choroid of right eye.**

Institution: Bogra Swasthoseba Hospit/Patient: Rasheda Begum, Mat.  
 Department: BADAS-CRBIS Eye Care Pro/Date of birth : 01/01/1967  
 Address: Matidali (Infront SOS Sol/Patient no.: 4  
 Attending Dr.: Dr.M Z Islam. Referring Dr.: Dr.M Z Islam.  
 Photographer: Sayednur  
 Comment: Choroidal 2ndy tumour.



**Figure 3: Ophthalmoscopic examination showing an irregular choroidal mass (white arrow) close to the optic disc.**

## REFERENCES

1. American cancer society, 'Thyroid cancer', retrieved 12 Dec 2014, <<http://www.cancer.org/acs/groups/cid/documents/webcontent/acspc-030369-df.pdf>.
2. Girelli ME, Casara D, Rubello D et al. Metastatic thyroid carcinoma of the adrenal gland. J Endocrinol Invest 1993;16:139-41
3. Hornblass A, Kass LG, Reich R. Thyroid Carcinoma metastatic to the orbit. Ophthalmology.1987;94(8):1004-7
4. Betharia SM. Metastatic orbital carcinoma of thyroid. Indian J Ophthalmol. 1985;33(3): 191-3
5. Besic N, Luznik Z. Choroidal and orbital metastases from thyroid cancer. Thyroid 2013; 23 (5): 543-51
6. Nahar N, Begum F, Begum R, Reza S. Orbital metastatic mass-evaluated by ultrasound imaging. Bangladesh J Ultrasonogr 2010;17(1):36-40
7. Avram AM, Gielczyk R, Su L, Vine AK, Sisson JC. Choroidal and skin metastases from papillary thyroid cancer: case and a review of the literature. J Clin Endocrinol Metab 2004;89(11): 5303-7
8. Arepalli S, Kaliki S, Shields CL. Choroidal metastases: origin, features and therapy. Indian J Ophthalmol. 2015; 63(2): 122-127.
9. Papastefanou VP, Arora AK, Hungerford JL, Cohen ML. Choroidal metastasis from follicular cell thyroid carcinoma masquerading as circumscribed choroidal haemangioma. Case Report in Oncological Medicine Volume 2014. Article ID 251817 <http://dx.doi.org/10.1155/2014/251817>