

**Case report:**

**A rare case of double orifice mitral valve with flail leaflet with embryological significance – A case report**

*Kumar GP<sup>1</sup>, Shaffiuddin M<sup>2</sup>*

**Abstract:**

Mitral valve having a double orifice opening into the left ventricle is an uncommon anomaly, In this case study we describe about a 25 years old female who came to cardiology outpatient block with exertional dysnea , the abnormality was suspected by a murmur ,further investigation Colour Doppler echocardiography showed congenital double-orifice mitral valve. This finding was confirmed by open heart surgery, and her mitral valve was successfully repaired.

**Key words:** Mitral valve with double orifice, left ventricle, murmur, exertional dysnea echocardiography, open heart surgery.

DOI: <http://dx.doi.org/10.3329/bjms.v13i1.17442>

Bangladesh Journal of Medical Science Vol. 13 No. 01 January '14 Page 80-83

**Introduction:**

The mitral orifice is well –defined transitional zone between the left atrium and left ventricle. Normal mitral valve consists of a central orifice located between anterior leaflet and posterior leaflet. Within the mitral annular circumference the anterior mitral leaflet occupies roughly one-third, whereas the posterior leaflet occupies the remaining two-thirds of the annular circumference.

At the end of the fourth week, two mesenchymal cushions, the atrioventricular endocardial cushions appear at the superior and inferior borders of the atrioventricular canal. Initially, the atrioventricular canal gives access only to the primitive left ventricle and is separated from the bulbus cordis by the bulbo ventricular flange. Near the end of the fifth week, however , the posterior extremity of the flange terminates almost midway along the base of the superior endocardial cushion and is much less prominent than before. Since the atrioventricular canal enlarges to the right, blood passing through the atrioventricular orifice now has direct access to the primitive left as well as the primitive right ventricle.

The superior and inferior endocardial cushions, the two lateral atrioventricular cushions appear on the right and left borders of the canal. The superior and inferior cushions, in the meantime , project further

into the lumen and fuse , resulting in a complete division of the canal into right and left atrioventricular orifices by the end of the fifth week.

**Atrioventricular valves:**

After the atrioventricular endocardial cushions fuse, each atrioventricular orifice is surrounded by local proliferations of mesenchymal tissue. When the blood stream hallows. Out and thins tissue on the ventricular surface of these proliferations, valves form and remain attached to the ventricular wall by muscular cords. Finally muscular tissue in the cords degenerates and is replaced and id replaced by dense connective tissue, the valves then consist of connective tissue covered by endocardium. They are connected to thick trabeculae in the wall of the ventricle, the papillary muscles, by means of chordate tendineae. In this manner two valves leaflets, constituting the bicuspid or mitral valve , form in the atrioventricular canal and three, constituting the tricuspid valve , form on the right side.

**Case Report:**

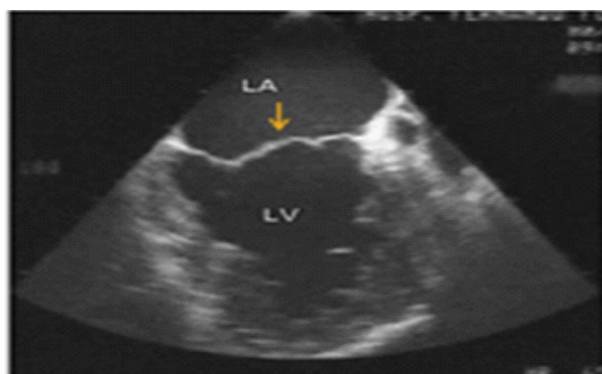
A 25years old female presented with Dysnea on exertion (NYHA functional class III) with orthopnea, PND which developed 1 month ago and gradually increasing symptoms. She underwent cardiac evaluation and was referred for further evaluation.

1. Dr. Gattu Praveen Kumar, Assistant professor, Mamata institute of Medical Sciences
2. Dr. Md. Shaffiuddin, Resident cardiology Medwin Hospital Hyderabad

**Corresponds to:** Dr.Gattu Praveen Kumar, Assistant professor ,Mamata institute of medical sciences [praveengattu@yahoo.com](mailto:praveengattu@yahoo.com)

On examination, a pansystolic murmur was heard in 3<sup>rd</sup>, 4<sup>th</sup> and 5<sup>th</sup> intercostal spaces in left parasternal area. Color Doppler flow imaging of the mitral valve showed 2 separate envelopes of antegrade flow into the left ventricle through the double orifices during diastole. In (Fig 1) two chamber Apical view showed division of mitral annulus into two by a small tissue like structure, where the septal and the lateral annuli were guarded by two leaflets. Color Doppler did not demonstrated any regurgitation, Pulse Doppler flow shows normal mitral flow

In (fig2). Short axis parasternal view instead of usual fish mouth appearance with single orifice , it showed two separate mitral orifices with knot like appearance. Tricuspid valves were functionally normal with a single orifice , with no diastolic gradients or regurgitations seen on Doppler examination .No other cardiac congenital anomalies were detected. The above discussed findings were justified in the operating room (fig. 3).with congenital Double orifice mitral valve with unequal size of two orifices were seen with posterolateral orifice with its own chordate tendinae with small papillary muscles, anteromedial orifice with a flail leaflet which also had its own chordate tendinae and papillary muscles .Mitral valve was successfully repaired, postoperative course was uneventful .patient remained and discharged in sinus rhythm.

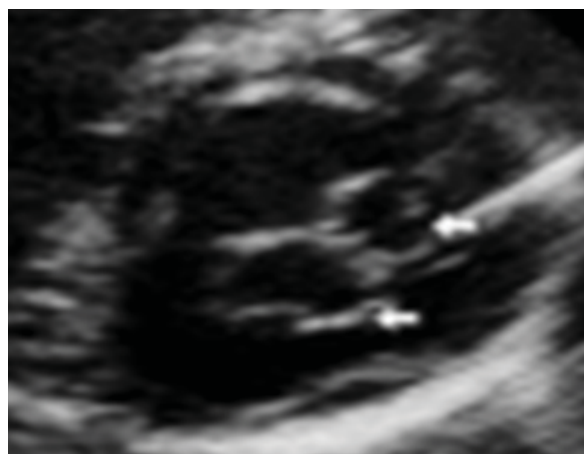

**Fig 1: Apical two chamber view showed a small tissue like structure dividing the common mitral annulus into two**

#### **Discussion:**

Double orifice mitral valve (DOMV) is a rare congenital anomaly , which was first described by Greenfield in 1876<sup>1</sup>.The normal mitral valve consists of a central orifice located between a sail-like anterior leaflet and a C-shaped posterior leaflet. The anterior mitral leaflet occupies roughly one-third of the annular circumference and the posterior leaflet

occupies roughly the remaining two-thirds of the annular circumference. In a DOMV, however, abnormal tissue divides the mitral orifice into 2 parts<sup>2</sup>. The mitral valve can function reasonably well in about 50% of patients with DOMV. The commonly associated lesion is atrioventricular septal defect, VSD, coarctation of aorta, interrupted aortic arch, patent ductus arteriosus, primum atrial septal defect, tetralogy of Fallot, and ebstein anomaly<sup>3</sup>, but in this case there was no such lesion.



**Fig 2: Short axis parasternal view shows double-orifice mitral valve**

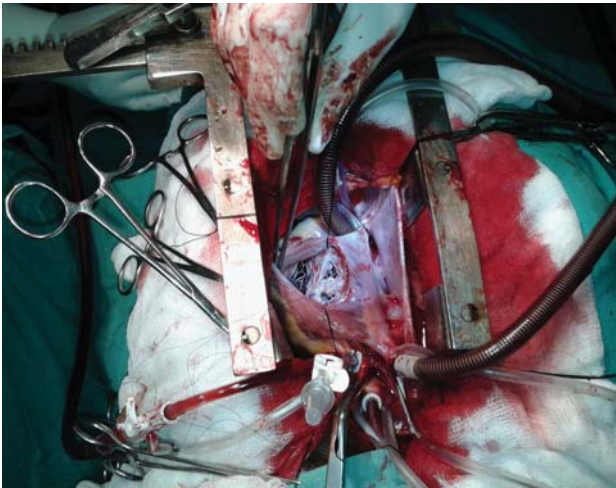
Trowitschet al<sup>4</sup>, proposed echocardiographic imaging was which divided DOMV into 3 different types:

1. Hole type (accessory orifice surrounded by leaflet tissue that may have a chordal ring),
2. complete bridging (fibrous bridge in the plane of the mitral valve sails, dividing the mitral valve opening into 2 parts that may be equal or unequal) and
3. Incomplete bridging (small strand of fibrous tissue connects only the tips of the anterior and posterior leaflets).

Our case falls into the complete bridge type of DOMV as per the Trowitzsch classification. Rosenberg et al reported 25% of patients with DOMV have partial persistent AV canal and about 5% of patients with partial persistent AV canal have DOMV. In their post-mortem study, Bano-Rodrigo described that only five cases (15%) had equal orifices due to the presence of a central fibrous subdivision. The natural evolution of double orifice mitral valve is unknown<sup>3</sup>. Bibhuti Das et al found that various abnormalities along with DOMV were left-

sided obstructive lesions, VSD; anomalies of the tricuspid valve<sup>2</sup>. However, in our case, there was no associated anomaly.

Ilbawi and associates<sup>5</sup> found a double-orifice mitral valve in 5% of 155 surgically repaired atrioventricular canal defects. The characteristic feature of double-orifice mitral valve is that all the chordae of one papillary muscle go to one of the ostia, whereas all the chordae of the other papillary muscle go to the other ostium.



**Fig 3: Showing posterolateral orifice & anteromedial orifice with flail leaflet**

Lee and associates<sup>6</sup> reported their experience of 25 patients with double-orifice mitral valve in atrioventricular canal defects. In the early part of their experience they divided the bridging tissue, with massive fatal regurgitation in most patients. In an asymptomatic patient, DOMV can be an incidental finding during echocardiographic examination. Though 2DE is useful in diagnosing the abnormal mitral valve anatomy, RT3DE examination provides additional anatomic details like the central bridging tissue and its extent to ventricular side and its spatial orientation to other sub-mitral structures<sup>7,8</sup>.

The embryologic theories explaining its origin include abnormal leaflet fusion and persistence of left part of the common atrioventricular canal. The combined area of DOMV in the presence of an AVSD is 85-90% of the normal expected area. Abnormal structure, including large bridging tissue, bulky abnormal leaflets, fused chordae or abnormal papillary muscles, reduce the effective area of the valve. Abnormalities in the leaflets include thickening, fusion, perforations, restricted movements and ruptured chordae with flail cusps. Such valves can result in clinically significant degrees of mitral incompetence<sup>9</sup>. Management needs to be individualized based on the associated lesions, extent of physiological derangement (stenosis or regurgitation) and clinical symptoms.

**References:**

1. Greenfield WS. Double mitral valve. *Trans Pathol Soc London* 1876; **27**: 128–129.
2. Das BB, Pauliks LB, Knudson OA, Kirby S, Chan KC, et al. Double-Orifice Mitral Valve with Intact Atrioventricular Septum: An Echocardiographic Study With Anatomic and Functional Considerations. *J Am Soc Echocardiogr*. 2005; **18**:231–6. PMID:15746712 <http://dx.doi.org/10.1016/j.echo.2004.12.001>
3. Bano-Rodrigo A, Van Praagh S, Trowitzsch E, Van Praagh R. Double-orifice mitral valve: a study of 27 postmortem cases with developmental, diagnostic and surgical considerations. *Am J Cardiol*. 1988; **61**:152–60. [http://dx.doi.org/10.1016/0002-9149\(88\)91322-7](http://dx.doi.org/10.1016/0002-9149(88)91322-7)
4. Trowitzsch E, Bano-Rodrigo A, Burger BM, Colan SD, Sanders SP. Two-dimensional echocardiographic findings in double-orifice mitral valve. *J Am Coll Cardiol*. 1985; **6**:383–7. [http://dx.doi.org/10.1016/S0735-1097\(85\)80176-5](http://dx.doi.org/10.1016/S0735-1097(85)80176-5)
5. Ilbawi MN, Idriss FS, DeLeon SY, et al. Unusual mitral valve abnormalities complicating surgical repair of endocardial defects. *J Thorac Cardiovasc Surg* 1983; **85**:697-704. PMID:6843150
6. Lee CN, Danielson GK, Schaff HV, Puga FJ, Mair DD. Surgical treatment of double orifice mitral valve in atrioventricular canal defects. Experience in 25 patients. *J Thorac Cardiovasc Surg* 1985; **90**:700-5. PMID:4058042
7. Lu Q, Lu X, Xie M, Wang X, Wang J, Yang Y, et al. Real-time three-dimensional echocardiography in assessment of congenital double orifice mitral valve. *J Huazhong Univ Sci Technol Med Sci*. 2006; **26**:625–8. <http://dx.doi.org/10.1007/s11596-006-0539-y> PMID:17219987
8. Takahashi K, Guerra V, Roman KS. Three-dimensional echocardiography improves the understanding of the mechanisms and site of left atrioventricular valve regurgitation in atrioventricular septal defect. *J Am Soc Echocardiogr*. 2006; **19**:1502–10. <http://dx.doi.org/10.1016/j.echo.2006.07.011> PMID:17138036
9. Hoffman P, Stumper O, Groundstroem K, Sutherland G. The transesophageal echocardiographic features of double-orifice left atrioventricular valve. *J Am Soc Echocardiogr*. 1993; **6**:94–100. PMID:8439430