

## **Case Report**

### **A rare case of left lung agenesis in a female teenager.**

Ankan B<sup>1</sup>, Debabrata S<sup>2</sup>, Kaushik S<sup>3</sup>, Debraj J<sup>4</sup>, Arnab M<sup>5</sup>, Arpita B<sup>6</sup>

#### **Abstract:**

Pulmonary agenesis is a rare congenital anomaly. History of recurrent chest infection in first year of life is the presenting symptom although patient may be asymptomatic and detected on routine chest x-ray. Our patient presented with recurrent chest infections since childhood. CT scan thorax revealed absence of lung tissue on left side with mediastinal shifting and herniation of right lung to left side. Pulmonary angiography confirmed the diagnosis of left lung agenesis.

**Key words:** left, lung agenesis, female

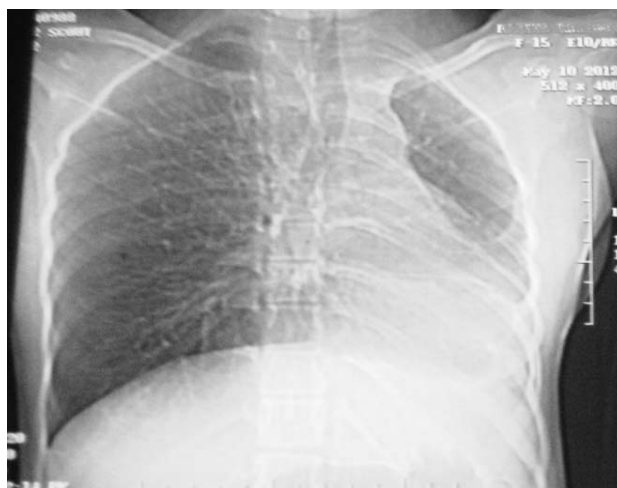#### **Introduction:**

Pulmonary agenesis is a rare congenital anomaly due to failure of development of primitive lung bud with incidence of 34 per 100000 live births<sup>1</sup>. About half of the cases are associated with cardiovascular, skeletal, gastrointestinal or genitorurinary abnormality<sup>2</sup>. Fifty percent of pulmonary aplasia are stillborn or die within the first five years of life<sup>3</sup>. Bilateral congenital pulmonary agenesis is a rare lethal anomaly, first described by Morgagni<sup>3</sup>. History of recurrent chest infection in first year of life is the presenting symptom although patient may be asymptomatic and detected on routine chest x-ray. We are reporting a case of left lung agenesis who presented with cough and exertional dyspnoea at the age of 15 years.

#### **Case report:**

A 15-year-old girl came to us with chief complains of dry cough, exertional dyspnea and recurrent episodes of respiratory tract infection since childhood. On general examination, there was mild pallor and tachypnea. On examination of respiratory system, there was decreased movement of left hemithorax with shifting of trachea and apex beat to the left. Breath sound was

absent in the left hemithorax and percussion note was dull in the left side. Traube's space was situated in left fifth intercostals space. Her chest x-ray (CXR) showed left sided homogenous opacity with mediastinal shifting to left side [Figure I].



**Figure I: Chest x-ray PA view showing left sided homogenous opacity with mediastinal shifting to left side**

CT scan of thorax showed absence of left lung with herniation of right lung to the left hemithorax with shifting of heart to the left hemithorax [Figure II].

1. Md Ankan Bandyopadhyay, RMO cum Clinical Tutor, Department of Pulmonary Medicine, NRS Medical College and Hospital, Kolkata, E-mail - drankan11@gmail.com
2. Debabrata Saha, Post Graduate Trainee, Department of Pulmonary Medicine, NRS Medical College and Hospital, Kolkata, E-mail - debabrata.derma.chest@gmail.com
3. Kaushik Saha, DTCD, RMO cum Clinical Tutor, Department of Pulmonary Medicine, NRS Medical College and Hospital, Kolkata, E-mail - doctorkaushiksaha@gmail.com
4. Debraj Jash, Post Graduate Trainee, Department of Pulmonary Medicine, NRS Medical College and Hospital, Kolkata, E-mail - jashdebraj@gmail.com
5. Arnab Maji, Post Graduate Trainee, Department of Pulmonary Medicine, NRS Medical College and Hospital, Kolkata E-mail - drarnabmaji@gmail.com
6. Arpita Banerjee, Consultant Pulmonologist, Kolkata, E-mail - dr.arpita.banerjee@gmail.com  
Department of Pulmonary Medicine of NRS Medical College and Hospital, Kolkata, West Bengal, India.

**Corresponds to:** Dr. Kaushik Saha, Rabindra Pally, 1st Lane. P.O. - Nimta. Kolkata, E-mail - doctorkaushiksaha@gmail.com

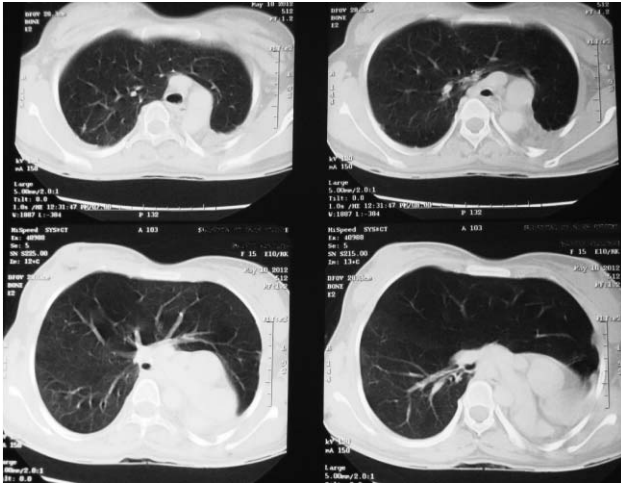


Figure II: CT scan thorax showing absence of left lung with herniation of right lung to the left hemithorax with shifting of heart to the left hemithorax

Bronchoscopy showed rudimentary left main bronchus narrowed to a blind end about 2 cm away from the carina [Figure III].

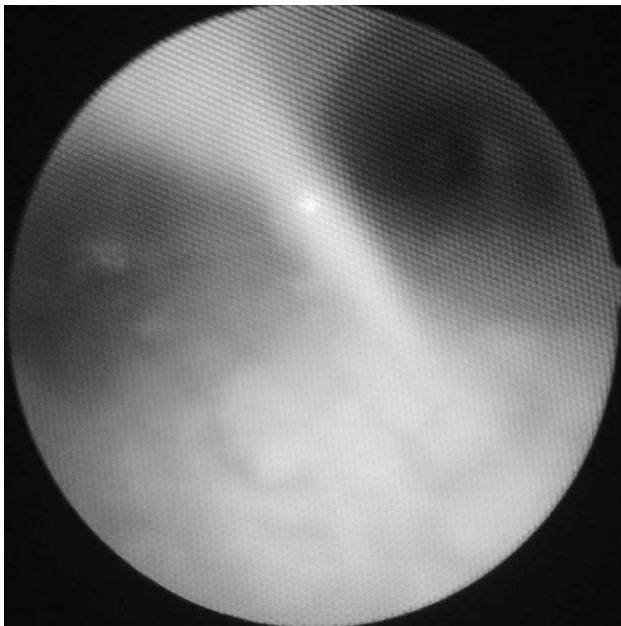


Figure III: FOB showing rudimentary left main bronchus narrowed to a blind end about 2 cm away from the carina

CT Pulmonary angiography showed absence of left pulmonary artery. So, the diagnosis of left lung agenesis type 2 was established. No other associated congenital anomaly was found in this patient.

### Discussion

Development of the bronchial tree takes place at about 26<sup>th</sup> to 31<sup>st</sup> day of intrauterine life. Depending upon the stage of development of the primitive lung bud, pulmonary agenesis is classified

into three categories: Type 1 (Agenesis) - Complete absence of lung and bronchus and no vascular supply to the affected side; Type 2 (Aplasia) - Rudimentary bronchus with complete absence of pulmonary parenchyma; Type 3 (Hypoplasia) - Presence of variable amounts of bronchial tree, pulmonary parenchyma and supporting vasculature <sup>4</sup>.

The onset of symptoms in pulmonary agenesis is remarkably variable. The age of presentation depends on type of lesion present. In many cases, presence of this anomaly usually comes to light during infancy because of recurrent chest infections, cardiopulmonary insufficiency or due to associated congenital anomalies. However, patients with one lung have been reported to survive well into adulthood without much complaint and they are detected in later years on routine CXR done for some other reasons. Nearly 50% cases of pulmonary agenesis have associated congenital defects, involving cardiovascular (ventricular septal defect, atrial septal defect, tetralogy of Fallot), skeletal (hemivertebra, absent ribs), gastrointestinal (esophageal atresia, imperforate anus) and genitourinary (absent or polycystic kidney) system <sup>5</sup>. The exact etiology of this condition is unknown although genetic factors, viral agents and dietary deficiency of Vitamin A during pregnancy have been implicated <sup>5</sup>. Left sided agenesis is more common and these subjects have a longer life expectancy than those with right sided agenesis <sup>6</sup>. Clinically the disease closely mimics collapse of the lung of affected side. The possibility of lung agenesis should be strongly suspected when CXR reveals bony symmetry, opaque hemithorax with ipsilateral mediastinal shift and herniation of contralateral lung to the affected side. Diagnosis of pulmonary agenesis should be made on CXR, CT scan of thorax, bronchoscopy and pulmonary angiography. With the advent of CT scan, these invasive procedures, which entail significant risk have become unnecessary <sup>7</sup>. Treatment in adults consists of control of recurrent infections, symptomatic treatment in form of expectorants and bronchodilators and management of other complications. Prophylaxis for respiratory syncytial virus, pneumococcus, influenza infections are recommended. No treatment is required in asymptomatic cases. Treatment is necessary for chest infections. Patients having stumps (hypoplastic bud) may require surgical removal if postural drainage and antibiotics fail to resolve the

infection. Corrective surgery of associated congenital anomalies, wherever feasible, may be undertaken<sup>8</sup>. Overall, prognosis depends on two factors. Firstly, the severity of associated congenital anomalies and secondly, involvement of the normal lung in any disease process. To conclude, clinical findings of recur-

rent respiratory infections and radiologic evidence of opaque hemithorax, bony symmetry and herniation of normal lung to the affected side, along with associated congenital anomalies, are suggestive of pulmonary agenesis.

---

**References:**

1. Borja AR, Ransdell HT Jr, Villa S. Congenital development arrest of the lung. *Ann Thorac Surg* 1970;**10**:317-26. [http://dx.doi.org/10.1016/S0003-4975\(10\)65608-1](http://dx.doi.org/10.1016/S0003-4975(10)65608-1)
2. Razaque MA, Singh S, Singh T. Pulmonary agenesis. *Indian J Chest Dis Allied Sci* 1980;**22**:174-8. PMID:7216317
3. Skandalakis JE, Gray SW, Symbas P: The trachea and the lungs. In: Skandalakis JE, Gray SW, editors. *Embryology for Surgeons*. 2nd ed. Baltimore, MD: Williams and Wilkins; 1994. p 429-32.
4. BOYDEN EA. Developmental anomalies of the lungs. *Am J Surg* 1955;**89**:79-89. [http://dx.doi.org/10.1016/0002-9610\(55\)90510-9](http://dx.doi.org/10.1016/0002-9610(55)90510-9)
5. Sbokos CG, McMillan IK. Agenesis of the lung. *Br J Dis Chest* 1977;**71**:183-97. [http://dx.doi.org/10.1016/0007-0971\(77\)90109-7](http://dx.doi.org/10.1016/0007-0971(77)90109-7)
6. OYAMADA A, GASUL BM, HOLINGER PH. Agenesis of the lung; report of a case, with a review of all previously reported cases. *AMA Am J Dis Child* 1953;**85**:182-7 PMID:13007169
7. Bhagat R, Panchal N, Shah A. Pulmonary aplasia: a CT appearance. *Indian Pediatr* 1992; **29**:1410-2 PMID:1294496
8. Chopra K, Sethi GR, Kumar A, Kapoor R, Saha MM, et al. Pulmonary agenesis. *Indian Pediatr* 1988;**25**:678-82. PMID:3220546