

**Original article****Supraorbital foramen and supraorbital notch morphometry- An assured aid to target the supraorbital nerve**Naveen Kumar<sup>1</sup>, Ravi Bhaskar<sup>2</sup>, Anjana S<sup>3</sup>, Satheesha K.S<sup>4</sup>, Surekha Shetty D<sup>5</sup>, Ashwini Aithal P<sup>6</sup>**Abstract:**

**Introduction:** Supraorbital neuralgia is manifested with pain and tenderness at the distribution of the supraorbital nerve (SN). Explicit knowledge of the location of SN is vital for clinicians performing regional nerve blocks to relieve the pain. In the present study, detailed measurements of the supraorbital foramen (SOF) and supraorbital notch (SON) of South Indian skulls are presented, and the data are compared with those from other populations. **Methodology:** One hundred SON/SOF were assessed morphometrically from 50 dried adult human skull. Relevant morphometric measurements were performed using Vernier caliper. The parameters used were horizontal and vertical diameters of SON/SOF, distance between SON/SOF from the supraorbital rim; SOF to the nasal skeletal midline; SOF to the temporal crest of the frontal bone, and SOF to the superior wall of the IOF. Data was analyzed using SPSSv16.0. **Results:** SON was more frequently found than SOF. The mean distance of SON/SOF to the nasal midline was 24.77 mm on right side and 23.36 mm on left side. The mean distance of SON/SOF to the temporal crest of frontal bone was 30.22 mm on both sides. Mean distance between SON/SOF to infraorbital foramen was 39.71 mm on right side and 40.41 mm on left side. Mean height of SOF was 1.38 mm on the right side and 1.31 mm on the left side. Mean transverse diameter of SON was 3.93 mm. **Conclusion:** Differences exist in the dimensions and position of SOF/SON among different races and people of other regions. Anatomical knowledge of SON/SOF is essential in facilitating craniofacial surgical procedures and in the treatment of neuralgia.

**Keywords:** Supraorbital notch; supraorbital foramen; supraorbital nerve; nerve block; craniofacial surgery.

Bangladesh Journal of Medical Science Vol. 22 No. 03 July'23 Page : 598-603  
DOI: <https://doi.org/10.3329/bjms.v22i3.65332>

**Introduction:**

The most essential anatomic entities for maxillofacial and plastic surgery operations are the supraorbital and infraorbital neurovascular bundles. The supraorbital foramen (SON) is located at the medial part of the supraorbital margin. Clinically supraorbital foramina

are regarded as two types. If it is complete, it is of hole type; when it is incomplete, it is viewed as notch type<sup>1</sup>. Anatomically, 'hole type' is the supraorbital foramen, whereas the 'notch type' is the supraorbital notch (SON). Previous morphometric analysis studies have reported that SON frequencies are higher than

1. Naveen Kumar, Department of Anatomy, Ras Al Khaimah College of Medical Sciences. RAK Medical & Health Sciences University, Ras Al Khaimah, UAE
2. Ravi Bhaskar, Department of Anatomy, Saphthagiri Institute of Medical Sciences & Research Center, Bengaluru, Karnataka, India.
3. Anjana S, Department of Anatomy, Saphthagiri Institute of Medical Sciences & Research Center, Bengaluru, Karnataka, India.
4. Satheesha K.S, Department of Anatomy, Srinivas Institute of Medical Sciences and Research Center, Mukka, Karnataka, India.
5. Surekha Shetty D, Division of Anatomy, Department of Basic Medical Sciences, Manipal Academy of Higher Education in Manipal, Karnataka, India.
6. Ashwini Aithal P, .Division of Anatomy, Department of Basic Medical Sciences, Manipal Academy of Higher Education in Manipal, Karnataka, India

**Correspondence:** Dr. Ashwini Aithal P, Assistant Professor, Division of Anatomy, Department of Basic Medical Sciences, Manipal Academy of Higher Education, Manipal, Karnataka, India  
Email: [ashwini.anat@gmail.com](mailto:ashwini.anat@gmail.com)

the SOF<sup>2</sup>. Both these have a different relationship with the supraorbital nerve, the terminal branch of the ophthalmic division of the trigeminal nerve. The supraorbital nerve is prone to traumatic injury because of its superficial location<sup>3</sup>. In the incidence of SOF, the course of the supraorbital nerve remains unchanged, and hence puncturing at the foramen could readily damage the nerve. However, in the SOF, the supraorbital nerve may show inner or outer deviation and thus may not travel through the vicinity of the foramen<sup>4</sup>. Aforesaid, anatomically variant relation of supraorbital nerves with the foramen or notches would mislead the puncturing site for radiofrequency therapy. Moreover, the surgical approach to the exact location of the supraorbital foramen/notch is a delicate task and needs to be precise. Hence detailed knowledge of its anatomy is required to accomplish the appropriate surgical outcomes<sup>5</sup>.

Iatrogenic injury to the neurovascular bundle at the SOF/SON may cause paresthesia or lead to anesthesia<sup>6</sup>. Supraorbital neuralgia or migraine is manifested with pain and tenderness at the distribution of the supraorbital nerve. Precise diagnosis of the symptoms of neuralgia is decisive in choosing suitable therapies. Palpating method to confine the SON/SOF in managing migraine headaches is no longer advisable. At times supraorbital nerve block is the choice of treatment<sup>3,7</sup>. The supraorbital nerve blocks are also performed in the region of supra-orbital foramen during procedures such as the closure of facial wounds, debridement, biopsies, and other cosmetic cutaneous procedures<sup>8</sup>. Without awareness regarding the site of exit of regional nerves, injury can occur, resulting in loss of sensation in corresponding regions of the face<sup>9</sup>. Therefore, detailed knowledge regarding the supraorbital foramen and morphometric measurements involving the various distances from SOF to the local landmarks such as nasion (nasal midline), the temporal crest of the frontal bone, supraorbital margin, and infraorbital foramen shall provide easy access to the SOF for surgical interventions.

This anatomical study aimed to investigate the bilateral configuration and locality of the SOF or SON in the skulls of the South Indian population. The locations of the foramina were measured relative to the frequently encountered surgical landmarks on the skull and analyzed based on gender and side.

#### **Method and Material:**

One hundred SOF/SON were assessed

morphometrically from 50 dried adult human skull with intact bony orbit (R= 50 and L= 50) in this study. The presence of supraorbital notch or foramina were ascertained bilaterally and relevant morphometric measurements were performed using Vernier caliper. The identification between supraorbital foramen (SOF) and notch (SON) was made (Figure 1). In the presence of SOF, the horizontal and vertical diameters of the foramen were measured. The relative position of the SOF was analyzed with measurements made from SOF to the nasal skeletal midline (SOF-NSM), from SOF to the temporal crest of the frontal bone (SOF-TCFB), from SOF to the superior wall of the infraorbital foramen (SOF-IOF) and from SOF to supraorbital rim (SOR). All values were tabulated and from these measurements and mean, standard deviations (mean  $\pm$  SD) were calculated. Descriptive statistics and t-test were used to analyze the data using SPSS v 16.0. Measurements were evaluated according to gender and side. A statistically significant difference was considered when the p-value was less than 0.05.

**Ethical clearance:** Not applicable

#### **Results**

There were 14 female and 36 male crania according to the standard criteria used in forensic medicine. When measurements of the foramina of both sides are considered, there were 36 SOF and 62 SON. SOF/SON was absent in 2 crania on the right side and in 1 cranium on the left side. There was presence of an accessory SOF on both the sides. The data concerning these measurements are in Table 1. Transverse and vertical diameter of SON/SOF was higher in female than in male skulls. Whereas the measurement of distance between SON/SOF with bony landmarks was higher in males compared to female skulls. There was a statistically significant difference between SOF-SOR measurement. The comparison between the measurements of the right and left foramina are summarized in Table 2. No significant difference was present between the right and left side measurements. The comparison between the measurements of right and left side of male and female crania are summarized in Table 3. Among the measurements, distance between SOF-SOR right (P<0.05) and left side (P<0.05) were statistically higher in male crania than in female crania.

#### **Discussion**

Precise knowledge regarding the location of the supraorbital foramen is essential for clinicians in

performing surgeries over the supraorbital margin. Hence, the present study measured the exact location and dimensions of the foramen/notch in adult human skulls, and the findings are compared with previous studies. The formation of foramen results from the ossification of the periosteal ligament located below it<sup>10</sup>. Incomplete ossification of this ligament causes a slight gap at the lower margin resulting in an incomplete foramen<sup>11</sup>. In the present study, the frequency of occurrence of the SON was 63.2%, and the SOF was 36.7% which is closer in range to previous studies<sup>12</sup>. Studies have shown that the position of supraorbital foramina/notches is not constant<sup>13</sup>. Hence, the localization of SOF or SON may not be similar for individuals with different geographic and climatic conditions. This is evident from the study report by Agnieszka et al., According to them, the prevalence of SON is more in the populations from the warm region than in the cold, and the location of SOF or SON is higher in position in the people of cold climate regions<sup>2</sup>. Our findings emphasize the ethnic variations in the occurrence of SOF/SON as supported by other studies. Studies from Northeast Asians and North American region<sup>14</sup>, Mexicans<sup>15</sup>, Chinese<sup>16</sup> showed a higher frequency of SOF occurrence than other populations. The supraorbital foramen is at greater risk during surgical dissection, as during retraction, the supraorbital neurovascular bundle is more likely to be stretched. In populations with a greater incidence of supraorbital foramina, extra care must be exercised during the reflection of scalp flaps<sup>16</sup>.

The SOF/SON measured approximately 23 mm in female crania and 24 mm in male crania from the nasal midline. Previous studies reported similar measurements where the distance between the SOF/SON and the midline ranged between 20-30 mm<sup>17,18</sup>. A much lengthier (29 mm) distance between the SOF and midline was observed in a study conducted on a different population<sup>19</sup>. The mean transverse diameter of SON was 3.92 mm on both the sides and the mean transverse diameter of SOF was 2.37 mm on right side and 2.09 mm on left side. It was interesting to note that the transverse diameter of SON and SOF was slightly higher in female skulls compared to male skulls. These diameters were somewhat less when compared to previous studies done on Indian skulls<sup>6</sup>. The size of the SOF/SON reflects the thickness of the supraorbital nerve and the caliber of supraorbital vessels. Previous studies have reported that the supraorbital notches with width less than 5

mm showed at least one accessory foramen which indicates the early division of supraorbital nerve and their exit through the accessory foramina. The horizontal distance measurement of the SON/SOF helps in avoiding injury to supraorbital nerves and vessels during brow surgery. Similarly, to execute the access incision to approach the location of the SOF, prior knowledge of distance from the supraorbital rim as a closest determination of the SOF location is often considered as landmark<sup>20</sup>. Supra orbital nerve block therapy necessitates managing neuropathic pain caused by the post traumatic supraorbital nerve injury<sup>21</sup>. The nerve in such cases is blocked by injecting the anesthetic drug approximately 2 cm lateral to the supraorbital notch<sup>22</sup>. It was also noted in the present study that there was complete absence of SOF/SON in 3 skulls. Complete absence of foramen/notch may deprive the supraorbital neurovascular structures, the protection and make them more vulnerable to injuries at the supraorbital margins.

The morphometric measurements using dried skulls have unique significance over other methods such as radiological or intraoperative procedures as the former gives a whole integrated morphology of the foramen/notches<sup>23</sup>. The importance of morphometric study of the SOF/SON and IOF gains a special attention and popularity in invasive surgical approaches which are having limited visibility<sup>24,25</sup>. Surgical procedures in the forehead and temple region, brow lifting (blepharoplasty), have gained importance as substantial components of managing the aging face. Adequate knowledge of forehead anatomy, especially the supraorbital region, is essential for performing these cosmetic surgeries<sup>26</sup>. Injury to the supraorbital neurovascular bundle might lead to hematoma formation, anesthesia or hypoesthesia in the area of the forehead, necrosis of parts of the forehead flap leading to hair loss. In frontal sinus obliteration, orbital decompression, and exploration for the fractures and orbital exenteration, the location of SOF/SON and its measurements from the supraorbital rim are used as reference points<sup>27,28</sup>. Therefore, the present study can serve as a guide for anesthetic, diagnostic, therapeutic or invasive surgical purposes.

### Conclusion

Supraorbital morphometry is essential for performing surgical interventions in the region of the forehead and the periorbital areas. Some intra-ethnic and interethnic variations in the position of the SOF/SON may exist; thus, these mean distances

found may vary from population to population. Our findings suggest that gender should be considered when locating the foramina as the measurements may be lengthier in males than in females. There may be an accessory supraorbital foramen and is more frequently seen lateral to the main SOF/SON. The present study adds information to the literature concerning the morphometry of supraorbital foramina and the distances of these foramina from surgically encountered landmarks, which might facilitate invasive procedures without causing any injury to the surrounding vital structures.

**Declarations**

**Source of fund:** NONE

**Conflict of Interest:** NONE

**Authors' contribution:**

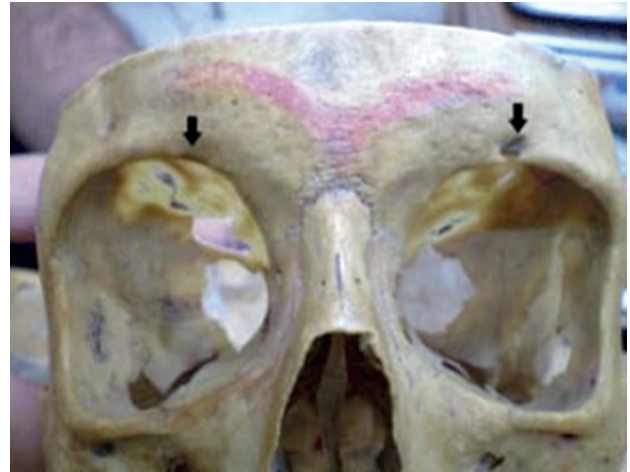
Data gathering and idea owner of this study: RB, NK

Study design: RB, SKS

Data analysis: AS, SSD

Writing and submitting the manuscript: NK, AAP

Editing and approval of final draft: NK, AAP



**Figure 1:** Figure showing the skull with presence of both supraorbital notch (right side arrow) and supraorbital foramen (left side arrow)

**Table 1: Comparison in measurements between male and female crania**

Parameters	Male (n=36) (Measurements in mm)			Female (n=14) (Measurements in mm)		
	Mean±SD	Minimum	Maximum	Mean±SD	Minimum	Maximum
Transverse diameter of SON	3.82±1.85	0.97	7.75	4.05±1.72	1.33	7.36
Transverse diameter of SOF	2.15±0.95	0.84	5.87	2.85±1.02	1.20	3.80
Vertical diameter of SOF	1.35±0.41	0.52	2.70	1.39±0.37	0.77	1.64
Distance between SOF and SOR	2.50±1.09	0.86	5.56	1.50±0.42*	0.90	1.87
Distance between SOF and NSM	24.46±3.17	18.14	32.13	23.23±3.10	18.31	30.56
Distance between SOF and TCFB	30.31±2.89	24.08	37.40	30.05±2.80	23.44	34.94
Distance between SOF and IOF	40.24±3.51	34.31	49.23	39.67±3.03	34.47	45.59

SOF-supraorbital foramen, SOR-supraorbital rim, NSM-nasal skeletal midline, TCFB- temporal crest of the frontal bone, IOF-infraorbital foramen. \*p<0.05.

**Table 2: Comparison in measurements between right and left sides**

Parameters	Right side (n=49) (Measurements in mm)			Left side (n=50) (Measurements in mm)		
	Mean±SD	Minimum	Maximum	Mean±SD	Minimum	Maximum
Transverse diameter of SON	3.93±1.78	0.98	6.53	3.92± 2.21	0.97	7.75
Transverse diameter of SOF	2.37±0.97	0.91	4.09	2.09± 1.20	0.84	5.87
Vertical diameter of SOF	1.38± 0.37	0.82	2.10	1.31± 0.52	0.52	2.70
Distance between SOF and SOR	2.58± 1.46	0.86	5.56	2.05± 0.96	0.98	4.57
Distance between SOF and NSM	24.77± 3.32	18.31	32.13	23.36± 3.18	18.14	31.37
Distance between SOF and TCFB	30.22± 2.89	24.08	37.40	30.22± 2.80	23.44	34.96
Distance between SOF and IOF	39.71± 3.03	34.31	47.19	40.41± 3.18	34.51	49.23

SOF-supraorbital foramen, SOR-supraorbital rim, NSM-nasal skeletal midline, TCFB- temporal crest of the frontal bone, IOF-infraorbital foramen.

**Table 3: Comparison in measurements between male and female crania based on side**

Parameters	Male (n=36) (Measurements in mm)	Female (n=14) (Measurements in mm)
Transverse diameter of SON right	3.95 ±1.85	3.90 ±1.72
Transverse diameter of SON left	3.68±2.45	4.20±1.95
Transverse diameter of SOF right	2.24±0.95	3.31±0.67
Transverse diameter of SOF left	2.04±1.28	2.27±1.02
Vertical diameter of SOF right	1.37±0.41	1.43±0.18
Vertical diameter of SOF left	1.32±0.57	1.31±0.37
Distance between SOF and SOR right	2.83±1.48	1.39±0.42*
Distance between SOF and SOR left	2.15±1.09	1.72±0.12*
Distance between SOF and NSM right	24.96±3.63	24.27±2.36
Distance between SOF and NSM left	23.89±3.17	22.53±3.10
Distance between SOF and TCFB right	30.25±3.02	30.13±2.65
Distance between SOF and TCFB left	30.36±2.76	29.99±2.92
Distance between SOF and IOF right	39.88±3.03	39.24±3.08
Distance between SOF and IOF left	40.65±3.51	40.04±2.67

SOF-supraorbital foramen, SOR-supraorbital rim, NSM-nasal skeletal midline, TCFB- temporal crest of the frontal bone, IOF-infraorbital foramen. \*p<0.05.

**References:**

1. Keyue Xie, Songlei Liu, Bing Huang, Ming Yao, "Effects of Supraorbital Foramen Variations on the Treatment Efficacy of Radiofrequency Therapy for V1 Trigeminal Neuralgia: A Retrospective Study". *Pain Research and Management*. vol. **2020**, Article ID 8142489, 6 pages, 2020.
2. Agnieszka Tomaszewska, Barbara Kwiatkowska, Rimantas Jankauskas. The Localization of the Supraorbital Notch or Foramen is Crucial for Headache and Supraorbital Neuralgia Avoiding and Treatment. *The Anatomical Record*. 2012; **295**:1494–1503
3. Levin M. 2010. Nerve blocks in the treatment of headache. *Neurotherapeutics*. 2010; **7**:197–203.
4. Q. Meng, W. Zhang, Y. Yang, M. Zhou, X. Li. Cardiovascular responses during percutaneous radiofrequency thermocoagulation therapy in primary trigeminal neuralgia. *Journal of Neurosurgical Anesthesiology*. 2008; **20**(2): 131–135.
5. Cuzalina AL, Holmes JD. A simple and reliable landmark for identification of the supraorbital nerve in surgery of the forehead:an in vivo anatomical study. *J Oral Maxillofac Surg*. 2005;**63**:25–27.
6. Gupta T. Localization of important facial foramina encountered in maxillo- facial surgery. *Clin Anat*. 2008;**21**:633–640.
7. Evans RW, Pareja JA. Supraorbital neuralgia. *Headache*. 2009;**49**:278–281.
8. Yashila Periyasamy and Bala Krishna. Morphometric Analysis of Supraorbital Foramen-A Research', *International Journal of Current Advanced Research*. 2021;**10**(01): 23550-23553.
9. Saylam C, Ozer MA, Ozek C, Gurler T. Anatomical variations of the frontal and supraorbital transcranial passages. *J Craniofac Surg*. 2003;**14**:10–12.
10. Henry Hollinshed W. in; *Anatomy of surgeon vol-1p 111* New York and London, Hoeber harper1966; 111.
11. Last FJ. Eugene Wolff's Anatomy of the Eye and Orbit. WB Saunders Company, Philadelphia, Penn.; 1968.
12. Priya Roy P, S D Jadhav, Kumar Sai Sailesh , MA Doshi, M P Ambali. Morphometric Analysis of Supraorbital and Infraorbital Foramen in Maharashtrian Skulls. *RJPBCS*. 2015;**6**(4):20.
13. Singh S, Bilodi AK, Suman P. Morphometric analysis on supraorbital notches and foramina in south Indian Skull. *Int J Cur Res Rev*. 2013;**5**(10): 43-50.
14. Hanihara T, Ishida H. Frequency variations of discrete cranial traits in major human populations. IV. Vessel and nerve related variations. *J Anat*. 2001;**199**:273–287
15. Berry AC. Factors affecting the incidence of non-metrical skeletal variants. *J Anat*. 1975;**120**:519–535.
16. Cheng AC, Yuen HK, Lucas PW, Lam DS, So KF. Characterization and localization of the supraorbital and frontal exits of the supraorbital nerve in Chinese: an anatomic study. *Ophthal Plast Reconstr Surg*. 2006;**22**:209–213.
17. Erdogmus S, Govsa F. Anatomy of the supraorbital region and the evaluation of it for the reconstruction of facial defects. *J Craniofac Surg*. 2007;**18**(1):104-112.
18. Ashwini LS; Mohandas Rao KG, Saran S; Somayaji SN. Morphological and morphometric analysis of supraorbital foramen and supraorbital notch: a study on dry human skulls. *Oman Med J*. 2012;**27**(2):129-33.
19. Jeong SM, Park KJ, Kang SH, Shin HW, Kim H, Lee HK, et al., Anatomical consideration of the anterior and lateral cutaneous nerves in the scalp. *J Korean Med Sci*. 2010;**25**(4):517-522.
20. Kleier DJ, Deeg DK, Averbach RE. The extraoral approach to the infraorbital nerve block. *J Am Dent Assoc*. 1983;**107**:758–760.
21. Antonacie F, Pareja JA, Caminero AB. Chronic paroxysmal hemicranias and hemicranias continua, anaesthetic blockades of pericranial nerves. *Funct Neurol*. 1997;**12**:11–15
22. Massry GG, Murphy MR, Azizzadeh B. Master techniques in blepharoplasty and periorbital rejuvenation. New York: Springer 2011.
23. Bunyarit, S. S., Ying, R. P. Y., Kadir, B. A., Nizam, M. M., & Rahman, M. Dental intervention perspective: Anatomical Variation of Mental and Mandibular Foramen in Selected Malay Patients. *Bangladesh Journal of Medical Science*. 2016;**15**(3):450–454.
24. Reisch R, Perneczky A, Filippi R. Surgical technique of the supraorbital key-hole craniotomy. *Surg Neurol*. 2003;**59**:223–227.
25. Tewari S, Gupta C, Palimar V, Kathur S. Morphometric analysis of infraorbital foramen in South Indian dry skulls. *Bangladesh Journal of Medical Science*. 2018; **17**: 562–563.
26. Webster RC, Gaunt JM, Hamdan US, Fuleihan NS, Giandello PR, Smith RC. Supraorbital and supratrochlear notches and foramina: anatomical variations and surgical relevance. *Laryngoscope*. 1986;**96**(3):311-315.
27. Huanmanop T, Agthong S, Chentanez V. Surgical anatomy of fissures and foramina in the orbits of Thai adults. *J Med Assoc Thai*. 2007;**90**(11):2383-2391.
28. W Ahmad, W. M. A, Noor, N. F. M, Shaari, R, Roslan, N. A. N, Mustapa, N. H, Adnan, M. N, Ghazali, F. M. M, Yaqoob, M. A, Akbar, N. A. N, Aleng, N. A, Alam, M. K. (2022). A Five-Year Retrospective Study on Fractured Orbital Walls: A Spearman Correlation Analysis. *Bangladesh Journal of Medical Science*. 2022;**21**(4):744–750.