

**Original article****Efficacy of Mometasone Furoate Nasal Spray with Oral Montelukast in the treatment of Otitis Media with Effusion with or without Adenoid Hypertrophy and Atopic diseases.**Afroza Khanam<sup>1</sup>, Gulshan Akhtar<sup>2</sup>, Mohammad Abdur Rahman<sup>3</sup>, NurunNahar Chowdhury<sup>4</sup>**Abstract**

**Background:** Otitis media with effusion [OME] is a common chronic but silent disease of middle ear in children and is the commonest cause of hearing impairment, delayed language development and altered quality of life. Though surgical management is the treatment of choice but now alternative medical treatment with steroid nasal spray is well accepted. **Aim of this study:** In this prospective, randomized placebo control study we want to observe the efficacy of Mometasone furoate nasal spray in conjunction with oral Leukotriene receptor blocker [Montelukast] in comparison to Mometasone furoate nasal spray only and normal saline spray as placebo for 3 months. **Materials and Methods:** Total sixty children aged 2-12 years old diagnosed with bilateral OME for at least 3 months with or without enlarged adenoid & atopic diseases, were randomly allocated into three equal groups. The first group A received Mometasone furoate nasal spray plus Tab Montelukast for 12 weeks and second group B received only mometasone furoate nasal spray & third group C received normal saline spray for the same duration. **Result:** Otolaryngologic clinical exam, Pure Tone audiometry & tympanometry were done at the end of treatment [3 months duration]. In otoscopic examination normal tympanic membrane finding show significant improvement in group A than group B & group C and tympanometric result in group A, show 80% improvement in middle ear status & had larger chi-square value than group B [60% improvement] and group C [10% improvement] and pure tone audiometry result show highest hearing threshold improved in group A and were more significant than group B and control group C. **Conclusion:** Mometasone furoate nasal spray is a much more effective medical treatment option in resolution of OME when it is combined with oral Leukotriene receptor blocker Montelukast as it helps to normalize the Eustachian tube function and middle ear status by decreasing enlarged adenoid size, atopic disorders and improving hearing power & quality of life.

Bangladesh Journal of Medical Science Vol. 21 No. 04 October'22 Page : 836-841  
DOI: <https://doi.org/10.3329/bjms.v21i4.60282>

**Introduction**

Otitis media with effusion (OME) is a common and important ear problem of childhood. It is a chronic disease where accumulation of mucus or serous sticky fluid accumulate in middle ear and mastoid air cells without features of an acute infection.<sup>1</sup>

The etiology of OME is multifactorial. Adenoid hypertrophy, allergy/atopy, repeated upper respiratory tract infection and gastro-oesophageal reflux disease including poor eustachian tube function, all have been identified as etiological factors.<sup>2,3</sup> It is the leading cause of acquired hearing loss in children. This may affect language and mental development.<sup>4</sup>

1. Dr. Afroza Khanam. Associate Professor. Department of Otolaryngology. Green Life Medical College, Dhaka.
2. Dr. Gulshan Akhtar. Associate Professor. Department of Pediatrics. Green Life Medical College, Dhaka.
3. Dr. Mohammad Abdur Rahman. Assistant Professor. Department of Cardiology. Shaheed Suhrawardy Medical College, Dhaka.
4. Professor Dr. Nurun Nahar Chowdhury. Professor & Head. Department of Psychiatry. Green Life Medical College, Dhaka.

**Correspondence:** Dr. Afroza Khanam phone 01726915890 email: [afrozakhanam85@gmail.com](mailto:afrozakhanam85@gmail.com)

Conventional medical therapy has been tried for OME, including antibiotics, nasal decongestants, antihistamines, but all fail to provide satisfactory relief of otogenic symptoms and ultimately they require surgery which are more cost effective and again some parents do not agree with it under General Anaesthesia because of hazards.<sup>5,6</sup>

So, some authors have suggested the use of short term systemic as well as topical intra nasal corticosteroid spray in the treatment of OME for decades,<sup>2,7,8,10,11</sup> Topical intranasal steroid is relatively safe especially the glucocorticoid which is rapidly degraded in the nasal mucosa to less active metabolites and is absorbed & metabolized through the liver. The systemic adverse effects are therefore less likely while the desired anti-inflammatory effects are so good<sup>19,20</sup> In this experimental study, we choose mometasone furoate monohydrate topical nasal spray with leukotriene receptor blocker tab Montelukast in the treatment of OME compared with only mometasone furoate monohydrate nasal spray and in control group normal saline spray in children aged between 2-12 years. The efficacy of the topical mometasone furoate steroid spray with leukotriene receptors blocker Montelukast significantly improved [p<0.001 with large chi-square value] the clinical and audiological status of children with OME.

### Materials and Methods:

This is an experimental, randomized prospective placebo control study, carried out from January'20 to December'20 on 66 children of the age group 2-12 years and were diagnosed as bilateral Otitis Media with effusion in the Department Otolaryngology and Department of Pediatrics of a tertiary care hospital in Dhaka, Bangladesh. It was approved by the institutional ethical committee. Informed written consent was obtained from parents of children under study after explanation of the research purpose.

Following steps were implemented in reaching the diagnosis of OME in children. History was taken from the parents, giving importance on different aspects of the condition including nasal obstruction, nasal discharge, snoring, hypo-nasal voice, difficulties in hearing and school performance, H/O previous earache and previous operation in the field of ear, nose and throat. Clinical examination of ear, nose, throat, otoscopy & Pure tone audiometry with tympanometry were done to see hearing impairment and middle ear compliance.

X-ray nasopharynx L/V view was done for diagnosis of enlarged adenoid in every child. In our study 50 children had enlarged adenoid (grade-2 & 3). Total circulating eosinophil and S.IgE level were done for evaluation of allergic diseases.

The exclusion criteria for the study were:

1. Previous H/O intranasal or systemic steroid use.
2. Previous H/O surgery for these illness.
3. Sensory neural hearing loss.
4. Nasal polyp.
5. Sinusitis.
6. Active upper RTI in the preceding 2 weeks.
7. Known H/O immunodeficiency.
8. Known H/O hypersensitivity to mometasone furoate or other steroid.
9. Down syndrome.
10. Cranio-facial abnormality

6 children did not continue the follow up visit and were excluded from the study. Total 60 children who participated in this study were randomly divided into 3 equal groups by a random number table. Group -A and Group-B considered as a study group and group-C represented as control group.

Parents were instructed how to use intra nasal spray and given Mometason Furoate nasal spray with oral Montelukast in group A and only Mometason furoate nasal spray in Group- B, Nosomist spray (normal saline) as placebo in group C with the instruction to take 1 spray mometasone furoate (100 mcg/day) into each nostril once daily for 12 weeks. Instructed dose of Montelukast was 4 mg tablet upto age 5 years & 5 mg for 6-12 years of age.

Otoscopy examination, with basic audiological evaluation including pure tone audiometry and tympanometry were performed before treatment, 8 weeks treatment after and after stopping of treatment (after 12 weeks). Tympanometry and pure tone audiometry were done by an audiologist in a standardized room. A type 'B' flat tympanogram was considered to support diagnosis of OME and 'C' Curve indicate negative pressure in middle ear. Clinical examinations and otoscopy were done once per week for 3 weeks and at the end of treatment. OME resolution was defined as normal finding of tympanic membrane on otoscopy, type A tympanogram and improved hearing to normal threshold. The efficacy of nasal steroid Mometason Furoate with Montelukast in the management of OME was compared with that of only Mometason Furoate nasal spray and normal

saline spray as placebo.

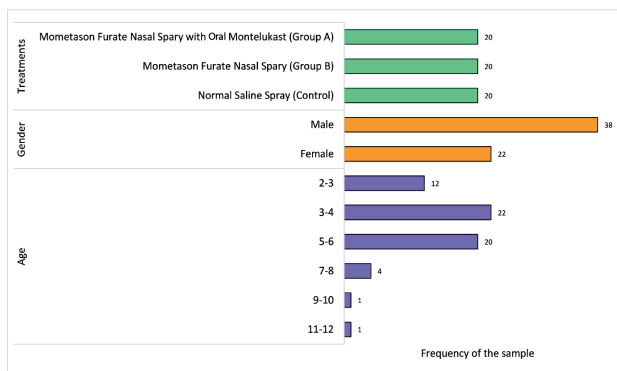
**Statistical Analysis:** Distribution of the characteristics of the sampled patients were presented using graphical representation (Horizontal Bar Plot). Then, efficacy of the treatments on Group A and B compared to controlled group was assessed using Pearson's Chi-Squared test (2) and visualization of the efficacy using vertical bar plot. Hearing improvement within each group was assessed using paired t-test (3) and finally effect of treatment was measured using ANOVA (4) and Duncan Multiple Range Test (5). Level of significance considered 5% for all tests. All statistical analyses have been conducted using Microsoft Excel and RStudio (R version 3.6.2).

**Ethical clarity:**

Ethical clearance of this research was received from the Ethical committee of Green Life Medical College, Dhaka.

**Result:**

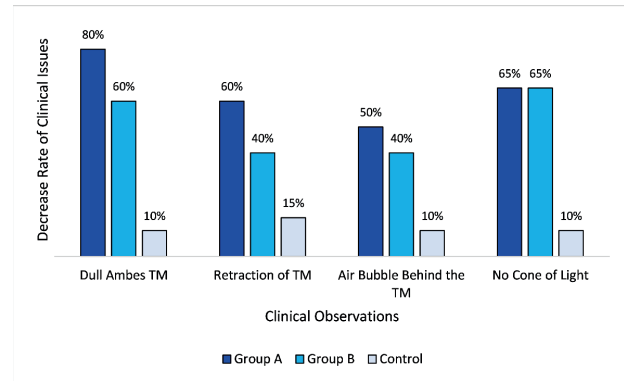
Distribution of the analytic sample (n=60) presented in Figure 1. Two treatments groups and one control group contain 20 patients each and the sample is dominated by male patients. On the other hand, least patients are from 9-12 age groups and highest number of patients allocated in age group 3-4.



**Figure 1:** Distribution of the analytic sample.

Table 1 depicts that both treatments found significantly effective on clinical observations by otoscopy considering pre and post treatments ( $p < 0.05$ ). Although both treatments were significantly effective, larger Chi-square values for Mometasone Furoate Nasal Spray with Oral Montelukast suggest that this treatment is more effective than only Mometasone Furate Nasal Spray. On the other hand, normal saline spray did not affect Dull Ambes TM, Retraction of TM, Air Bubble Behind the TM and No cone of Light at all ( $p > 0.05$ ).

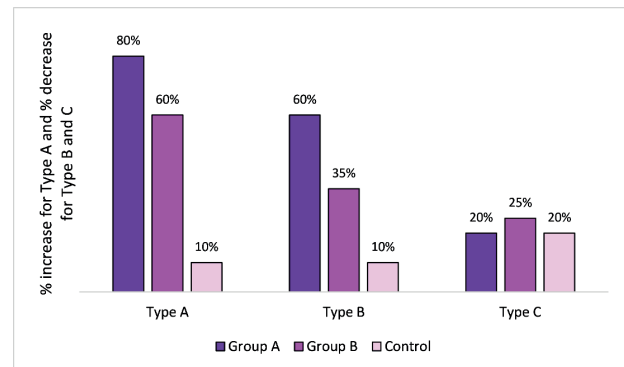
Figure 2 presents decrease rate of Dull TM compared to pre-treatment scenario is highest among Group A (MometasonFuroate Nasal Spray with Oral Montelukast) and lowest among control group (80% and 10% respectively). Similarly, decrease rate for other three clinical issues are highest among Group A (Retraction of TM= 60%, Air Bubble Behind the TM= 50% and No cone of light=65%)



**Figure 2:** Decrease rate of clinical issues as a result of treatments and control.

Table 2 presents distribution of tympanometry curve of pre treatment and post treatment with a clear indication of high effectiveness of treatment in Group A. Control group did not show any significant change ( $p > 0.05$ ). Post treatment found significantly different for both Group A and B in case of Type A and Type B audiometric conditions ( $p < 0.05$ ). Chi-square values for Group A are much higher than Group B, suggesting Group A got better treatment than Group B.

Figure 3 shows increase rate of normal ear and decrease rate of Type B and Type C. Expectedly normal ear increases by 80% in Group A which is



**Figure 3:** Increase rate of normal ear and normalization rate of Tympanometry curve as a result of treatments and control.

**Table 1: Efficacy of Mometason Furoate Nasal Spray with Oral Montelukast compared to other treatment and control groups on clinical observations by otoscopy (Results from Pearson's Chi-Squared Test).**

Clinical Observation by Otoscopy	Group A (n=20)			Group B (n=20)			Control (n=20)		
	Pre-Treatment	Post Treatment	Chi-square (p-value)	Pre-Treatment	Post Treatment	Chi-square (p-value)	Pre-Treatment	Post Treatment	Chi-square (p-value)
Dull TM	18 (90%)	2 (10%)	25.6 (<0.001)	16 (80%)	4 (20%)	14.4 (<0.001)	20 (100%)	18 (90%)	0.360 (0.548)
Retraction of TM	16 (80%)	4 (20%)	14.4 (<0.001)	14 (70%)	6 (30%)	6.4 (0.011)	18 (90%)	15 (75%)	1.56 (0.212)
Air Bubble Behind the TM	12 (60%)	2 (10%)	10.99 (<0.001)	14 (70%)	6 (30%)	6.4 (0.001)	12 (60%)	10 (50%)	0.40 (0.525)
No Cone of Light	16 (80%)	3 (15%)	16.94 (<0.001)	18 (90%)	5 (25%)	17.29 (<0.001)	16 (80%)	14 (70%)	0.53 (0.465)

\*p<0.05 considered significant.

**Table 2: Efficacy of Nasal Steroid Spray with tab Montelukast compared to other treatment and control groups on distribution of tympanometry curve (12 weeks treatment) (Results from Pearson's Chi-Squared Test).**

Distribution of tympanometry curve	Group A (n=20)			Group B (n=20)			Control (n=20)		
	Pre-Treatment	Post Treatment	Chi-square (p-value)	Pre-Treatment	Post Treatment	Chi-square (p-value)	Pre-Treatment	Post Treatment	Chi-square (p-value)
Type A (Normal Ear)	0 (0%)	16 (80%)	26.67 (<0.001)	0 (0%)	12 (60%)	17.14 (<0.001)	0 (0%)	2 (10%)	2.11 (0.147)
Type B (Flat curve; Fluid in Middle Ear)	14 (70%)	2 (10%)	15.0 (<0.001)	10 (50%)	3 (15%)	5.58 (0.018)	12 (60%)	14 (70%)	0.44 (0.507)
Type C (Negative Pressure in Middle Ear)	6 (30%)	2 (10%)	2.5 (0.114)	10 (50%)	5 (25%)	2.67 (0.102)	8 (40%)	4 (20%)	1.90 (0.168)

\*p<0.05 considered significant.

**Table 3: Comparison between pre and post-treatment average of Hearing thresholds improvements (results from paired t-test).**

	Hearing Threshold (dB) Mean ± SD		Test Statistic	P-value
	Pre-treatment	Post treatment		
Group A	34.9 ± 4.30	11.65 ± 2.23	25.59	<0.001
Group B	33.65 ± 8.12	14.95 ± 3.35	12.04	<0.001
Control	33.3 ± 6.78	29.9 ± 4.24	1.89	0.074

highest among all. Decrease rate for type B is highest among Group A (60%) followed by Group B (35%) and control group (10%). Treatments did not show any effect on Type C. Mild natural improvement occur in group C.

Table-3, depicts that there is significant improvements in hearing threshold between pre and post treatments

among Group A and Group B, but more significant effect of treatments in group A. Before treatment average hearing threshold for Group A patients was 34.9 dB and after treatment was 11.65dB. On the other hand, pre and post treatment hearing thresholds for Group B patients were 33.65dB and 14.95dB respectively. This table indicates hearing improvements within Groups after treatment.

To assess the magnitude of the hearing thresholds improvement we conducted ANOVA followed by Duncun's Multiple range test on hearing thresholds improvement (Pre treatment dB – Post treatment dB) (Table 4). Significant p-value in ANOVA explains the significant effect of treatments on patients. Duncun's multiple range test clearly showed that average hearing improvement is significantly highest among Group A (23.25dB) followed by Group B (18.70dB) and lowest hearing improvement found in control group.

**Table 4: Assessing magnitude of hearing thresholds improvement as a result of Nasal Steroid Spray with tab Montelukast (results from ANOVA and Duncan's Multiple Range Test)**

1. ANOVA

	Sum of Square	DF	Mean Square	F-value	P-value
Treatment	4325	2	2162.7	50.22	<0.001
Residuals	2455	57	43.1		

2. Duncun's Multiple Range Test

	Mean of Hearing improvement	Critical Value
Group A	23.25 ± 4.06 <sup>a</sup>	
Group B	18.70 ± 6.94 <sup>b</sup>	4.16 (A vs B)
Control	3.40 ± 8.03 <sup>c</sup>	4.37 (B vs C)

\*Means with the same letter are not significantly different

**Discussion:**

Otitis media with effusion is a very common but silent disease of ear in childhood. It is a non-inflammatory condition of middle ear with accumulation of fluid which causes hearing impairment, delayed language development and affects quality of life.<sup>1</sup>

OME is mostly diagnosed at the age of 1-4 years of age because in this paediatric age group eustachian tube remain shorter, wider and more horizontal in position so liquid food or upper respiratory secretions easily reach middle ear and act as cofactor in developing otitis media with effusion.<sup>2,3</sup>

Hearing impairment in otitis media with effusion is conductive in type and often mild to moderate in severity (26-40 DB). We performed pure tone audiogram and tympanometry to all patients of our study to asses' middle ear status and hearing loss.

Surgical procedures like insertion of tympanostomy tube, myringotomy with or without adenoidectomy are universally accepted modality in the treatment of persistent middle ear effusion. However, these procedure are always done under general anesthesia and thus may have complications and incurs cost.<sup>5,6</sup>

Medical treatment with systemic corticosteroid or topical intranasal corticosteroid especially glucocorticoid has anti-inflammatory, anti-allergic effect locally as well as systemic without significant side effect. They act by preventing the synthesis of inflammatory mediators, increase insurfactant in Eustachian tube, decrease adenoid size and

shrink peritubal lymphatic swelling which allow better eustachian tubal functions. In addition, they decrease the viscosity of middle ear fluids, allergy and upregulate transepithelial sodium transport in middle ear epithelium and promote removal of middle fluid. Mode of action of intra nasal steroid is very complex but significantly beneficial.<sup>7,8,9</sup>

Lots of study have been done previously with different type of steroid in the treatment of persistent otitis media with effusion with or without enlarged adenoid and show statistically significant outcome<sup>10,11,12,17,20</sup> mostly using the steroid mometasonefuroate.

In our study with mometasonefuroate nasal spray we added new drug Leucotrine receptor blocker Montelukast which binds with high affinity the Leukotrine receptors LTC<sub>4</sub>, LTD<sub>4</sub>, LTE<sub>4</sub> and reduce inflammations, mucus secretions and relax smooth muscle in upper respiratory tract, nasopharynx, eustacian tube, middle ear & lungs and give good result in the treatment of enlarged adenoid, and atopic diseases which are the contributing factors of developing otitis media with effusion.<sup>13,14,15,21</sup>

Our study is comparable to W Liu et al.2017.<sup>18</sup> and AboubakrElshafeyRas et al study 2020<sup>19</sup>. In AboubakrElshafeyRas et al study which included 100 children with adenoid hypertrophy with or without otitis media effusion and they were randomly divided into two equal groups. Group-1, received combined therapy using oral Montelukast and Mometasonfourat nasal spray. Group-2, received only Mometasonfuroate nasal spray for 12 weeks. Result was significantly reduced enlarged adenoid size in group -1 than Group -2 [p<0.001] and also reduced enlarged adenoid related sign & symptoms especially otitis media with effusion.

In our experimental, prospective, randomized, controlled study [(n=60) we used Mometasonfuroate nasal spray in combination with oral Montelukast in Group -A. only Mometasonfourate nasal spray in Group- B, and normal saline spray as placebo in Group -C. for 3 months. Both treatment in Group -A & Group- B, founds significantly effective but chi-square test values depicts that Mometasonfuroate nasal spray with oral Montelukast statistically significant improvement in the treatment of OME with or without adenoid hypertrophy and atopic diseases.

Limitation of study: Short – term follow up and small sample size are the limitation of our study

## Conclusion

Mometasonefuroate (glucocorticoid) nasal spray is a well-known effective treatment for otitis media with effusion but when it combines with leukotrinereceptors blocker (Montelucast) its efficacy of regulation Otitis Media with effusion become more significant. It is also helpful in controlling nasal allergy and in reduction of enlarged adenoid size which are contributing factors in developing and recurring Otitis Media with effusion. Further studies are needed regarding this treatment for longer duration in larger scale and in recurrent cases.

## Funding:

The authors didn't receive any grant for the research, authorship or publication.

## Conflict of interest:

The writers declare that there is no conflict of interest on this research.

## Contribution of Authors:

Research idea owner of this study: Khanam A

Study design: Khanam A

Data collection: Khanam A, Akhtar G, Rahman A A, Choudhury N N.

Writing and submitting manuscript: Khanam A, Akhtar G

Editing and approval of final draft: Khanam A, Akhtar G

## Acknowledgement:

I would like to thank all the participants.

## References:

1. Thomas CL, Simpson S, Butter CC, Van der Voort JH. Oral topical nasal steroids hearing loss associated with otitis media with effusion in children. *Cochrane Database Syst Rev* 2006;[3]:CD001935. <https://doi.org/10.1002/14651858.CD001935.pub2>
2. Cengels, Akyol MU. The role of topical nasal steroids in the treatment of children with otitis media with effusion and/or adenoid hypertrophy. *Int J Pediatr Otorhinolaryngol* 2006;70[4]:639-645. <https://doi.org/10.1016/j.ijporl.2005.08.013>
3. Robb PJ, Graham JM, Scadding GK, Bull PD. Otitis media with effusion. *Pediatric ENT*. Springer, Heidelberg. 2007. 413-420.
4. Casselbrant ML, Brostoff LM, Flaherty MR, Bluestone CD, et al. Otitis media with effusion in preschool children. *Laryngol* 1985;95[4]:428-36. <https://doi.org/10.1288/00005537-198504000-00011>
5. American Academy of Family Physicians, American Academy of Otolaryngology-Head and Neck Surgery, American Academy of pediatric subcommittee on otitis media with effusion. *Pediatrics* 2004; 113:1412-29. <https://doi.org/10.1542/peds.113.5.1412>
6. Ina F Wallace et al. Surgical treatment for otitis media with effusion: A systemic review. *Pediatrics* 2014 Feb;133 [2]: 296-311. <https://doi.org/10.1542/peds.2013-3228>
7. Mandel EM, Casselbrant MI, Rockette HE et al. Systemic steroid for chronic otitis media with effusion in children. *Pediatrics* 2002;110:1071-80. <https://doi.org/10.1542/peds.110.6.1071>
8. Davies RJ, Nelson HS. Once-daily mometasonefuroate nasal spray: Efficacy and safety of new intranasal glucocorticoid for allergic rhinitis. *Clin Ther* 1997;19:27-38. [https://doi.org/10.1016/S0149-2918\(97\)80070-7](https://doi.org/10.1016/S0149-2918(97)80070-7)
9. Mygind N, Neilson LP, Hoffmann HJ, Shukla A, Blumberg G, Dahl R, et al. Mode of action of intranasal corticosteroids. *J Allergy Clin Immunol*; 108 [1]:S16-25. <https://doi.org/10.1067/mai.2001.115561>
10. Behrooz Barati, Mohammad Reza Omrani, Ahmed Reza Okhovat et al. Effect of nasal beclomethasone spray in the treatment of otitis media with effusion. *J Res Med Sci*. 2011; 16 [4]: 509-515.
11. El-Anwar MW, Nofal AA-F, Khazbak AO, Sayed AEE et al. The efficacy of nasal steroids in treatment of otitis media with effusion: a comparative study. *International Arch Otolaryngol*. 2015 ;19[4]:298-301. <https://doi.org/10.1055/s-0035-1548535>
12. Mohamed MA, Alebiary HA, Hasan MA, Elserly HA. The role of topical nasal steroid in treatment of otitis media with effusion in children: Systemic review. *Egyptian J hospital, Med*. 2018;70[4]:599-69. <https://doi.org/10.12816/0043807>
13. Jerom T Combs. The effect of montelukast sodium on the duration of effusion of otitis media. *Clin Pediatr*.43[6]:529-33.2004 <https://doi.org/10.1177/000992280404300604>
14. Schoem SR, Willard A, Combs JT, Aprospectus randomized placebo-controlled doubled study of montelukast effect on persistent middle ear effusion, *Ear Nose Throat j*. 2010;89[9]:437-7.PMID.
15. Dimitrios Belatsouras, P Eliopoulos, Efsthios Andreas Rallis et al. Improvement of otitis media with effusion after treatment of asthma with leukotrin antagonist in children with co-existing disease. *PubMed* 2005; 7-10.
16. Ercan pinar, Semihoncd, Caglar Calli et al, efficacy of nasal corticosteroids alone or combined with antihistamins or montelukast in treatment of allergic rhinitis. *Auris Nesus Larynx* 2008;35(1):p61-66, March 01., <https://doi.org/10.1016/j.aml.2007.06.004>
17. Rahul B, Arunabha C. A double blind randomized placebo controlled trial of topical intranasal Mometasonefuroate nasal spray in children of adenoidal hypertrophy with otitis media with effusion. *Am J Otolaryngol*. 2014; 35 [6]: 766-770. <https://doi.org/10.1016/j.amjoto.2014.06.006>
18. W Liu, R J Chen, Clinical observation of mometasonefuroate nasal spray combined with montelukast sodium in the treatment of adenoid hypertrophy in children. *Pub Med* 2017 Mar 5;31[5]:366-368.[Article in Chinese]
19. Ratner PH, Meltzer EO, Teper A. Mometasonefuroate nasal spray is safe and effective for 1-year treatment of children with perennial allergic rhinitis. *Int J Pediatr Otolaryngol* 2009; 73:651-7. <https://doi.org/10.1016/j.ijporl.2008.12.025>
20. Anup Acharya, Bandana Pokharel, Shiva Bhushan et al. Efficacy and cost effectiveness analysis of steroid in treatment of otitis media with effusion [OME] in children: A randomized trial. *JGMC Nepal* 2020;13[2]:111-5. <https://doi.org/10.3126/jgmcn.v13i2.30198>
21. Nanda, M.S., & Devi, R. (2022). Interprofessional collaboration to manage allergic disorders in rural areas of Humachal Pradesh. *Bangladesh Journal of Medical Science*, 21(1),96-100. <https://doi.org/10.3329/bjms.v21i1.56333>