

Original article:

Bronchoscopy for Removal of Foreign Body in Lower Airway: A Retrospective Analysis

Shankar Ramasundram¹, Sharmini Kuppusamy², Sivakumar Kumarsamy³, Valuyeetham Kamara Ambu⁴, Irfan Mohamad⁵

Abstract:

Bronchoscopy is performed for diagnostic or therapeutic purpose. Therapeutic bronchoscopy is mainly done for removal of foreign body from lower airway. Both the condition and procedure itself are associated with high mortality and morbidity. The aim of the study was to audit data regarding demography, types and location of foreign body, onset of symptom, admission duration, clinical and investigation findings along with duration of ventilation. We also highlight on the complications pertaining to the condition in our series.

Keyword: Foreign body aspiration; morbidity; rigid bronchoscopy

Bangladesh Journal of Medical Science Vol. 18 No. 04 October '19. Page : 779-782
DOI: <https://doi.org/10.3329/bjms.v18i4.42904>

Introduction

Foreign body in aerodigestive tract is a common encounter in otorhinolaryngology practice. Comparing between airway and digestive tracts, the airway foreign body has lesser occurrence, attributed to the protective function of the larynx in preventing foreign body intrusion. For foreign body airway, children are affected more common than adult. Different kind of foreign bodies have been implicated and reported to dislodge into different parts of bronchus and bronchioles. They warrant removal most of the time under general anesthesia, either by flexible or rigid bronchoscopy. As the condition as well as the procedure involve shared airway with the anesthetist, the situation is often associated with high morbidity and mortality.¹ Early diagnosis and treatment has been proven to reduce complications.²

Objectives

An audit of bronchoscopy for foreign body removal and its complications in lower airway was carried out during the period of 2009 till 2016 at a general hospital in the Negeri Sembilan, Malaysia. We also recorded the demography of affected population, types and location of the foreign body, onset of symptoms, duration of ventilation and admission.

Methodology

Retrospective analysis of patients who underwent rigid bronchoscopy for foreign body in lower airway from 2009 till 2016 was performed at Hospital Tuanku Ja'afar Seremban. All patients who were admitted were divided into early and late diagnosis groups depending on whether they presented to the hospital within 24 hours or later. All rigid bronchoscopy was performed under general anesthesia.

1. Shankar Ramasundram, Department of Otorhinolaryngology-Head & Neck Surgery, School of Medical Sciences, Universiti Sains Malaysia Health Campus, 16150, Kota Bharu, Kelantan, Malaysia & Department of Otorhinolaryngology-Head & Neck Surgery, Hospital Tuanku Ja'afar, 74000, Seremban, Negeri Sembilan, Malaysia.
2. Sharmini Kuppusamy, Department of Otorhinolaryngology-Head & Neck Surgery, Hospital Tuanku Ja'afar, 74000, Seremban, Negeri Sembilan, Malaysia & Department of Otorhinolaryngology-Head & Neck Surgery, Faculty of Medicine, University of Malaya, Kuala Lumpur, Malaysia
3. Sivakumar Kumarsamy
4. Valuyeetham Kamara Ambu
Department of Otorhinolaryngology-Head & Neck Surgery, Hospital Tuanku Ja'afar, 74000, Seremban, Negeri Sembilan, Malaysia.
5. Irfan Mohamad, Department of Otorhinolaryngology-Head & Neck Surgery, School of Medical Sciences, Universiti Sains Malaysia Health Campus, 16150, Kota Bharu, Kelantan, Malaysia.

Correspondence to: Assoc. Prof Dr Irfan Mohamad. Department of Otorhinolaryngology-Head & Neck Surgery, School of Medical Sciences, Universiti Sains Malaysia Health Campus, 16150, Kota Bharu, Kelantan, Malaysia. Email: irfankb@usm.my

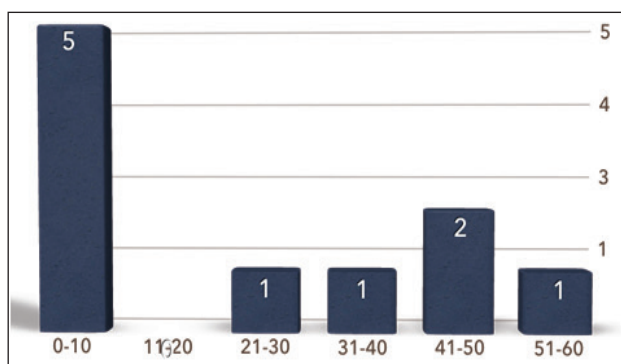


Figure 1: Distribution of patients according to the age in years at presentation to the hospital

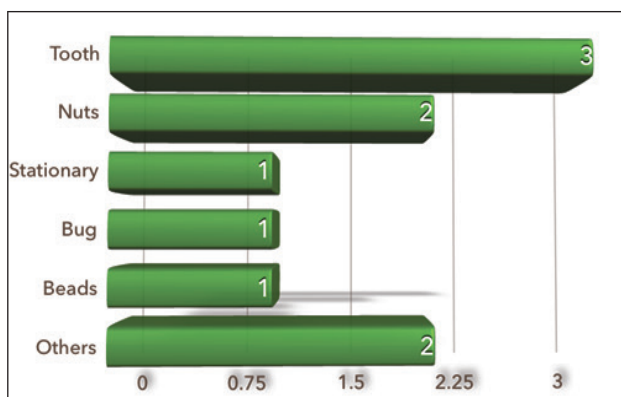


Figure 2: Types of foreign body removed

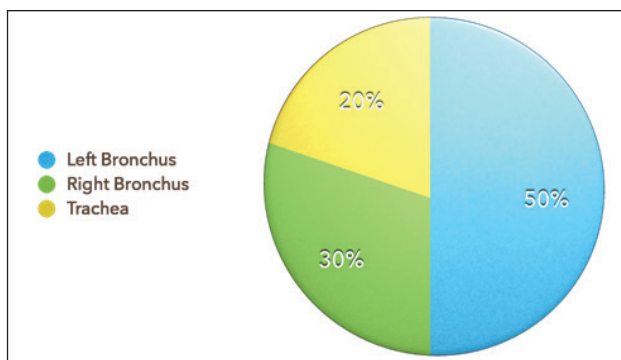


Figure 3: Location of foreign body identified

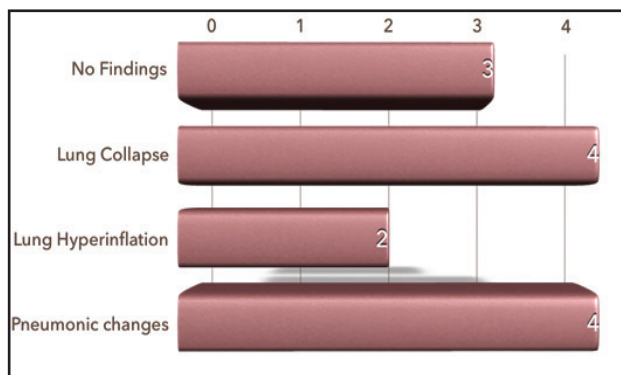


Figure 4: Chest radiograph findings demonstrated some suggestive features

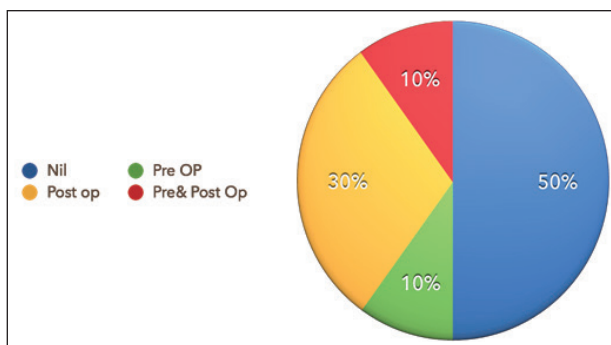


Figure 5: Requirement for assisted ventilation

Ethical clearance: This study was approved by ethics committee of School of Medical Sciences, Universiti Sains Malaysia Health Campus, 16150, Kota Bharu, Kelantan, Malaysia.

Results

A total of 10 patients underwent rigid bronchoscopy for foreign body removal during the study period. Early and late presentation equally distributed with 5 patients each. In our study, all foreign bodies removed successfully via rigid bronchoscopy except one, required additional procedure of tracheostomy. Duration of admission in affected patients ranged from 2 days to 35 days with the average days of admission of 11.4 days. 70% of the patients were male.

Table 1: Frequency of complications among patients with FB in lower airway in the early and late diagnosis groups

Complications	Early diagnosis (n=5)	Late diagnosis(n=5)
Lung Hyperinflation	1	1
Chest infection-pre*	1	3
Chest infection-post*	1	3
Lung Collapse	1	3
Desaturation	1	1
Pre Op Ventilation	1	1
Post Op Ventilation	1	3
Failure in removal via bronchoscopy	1	0
Emphysema	1	0

Discussion

Foreign body intrusion into the lower airway occurs commonly following penetrating neck injury or aspiration. Aspiration can occur whenever a patient loss his protective mechanism of the larynx, usually after being unconscious following motor vehicle accident (MVA), or impairment of sensory or motor innervation of the larynx following malignant lesion

or iatrogenic complications following surgery. It affects both sexes, however shows preponderance in male and children below 10 years of age.² Males are more commonly involved as penetrating laryngotracheal injuries affects male more commonly following MVA, or they are more likely to be involved in warfare^{3,4}. Nuts, seeds, tooth and headscarf pins are common foreign bodies found in lower airway.⁵⁻⁸ Right bronchus, owing to its anatomical predilection, is more common compared to the left^{6,9,10}. Rarely left bronchus is affected.¹¹

In children, some occurrence was witnessed by the parents or guardians, thus leading to almost accurate history and immediate diagnosis. History of choking during eating, followed by cough and examination showed reduced breath sound on the affected side are almost pathognomonic and diagnostic.^{6,9,10,12} Delayed presentations include unilateral decreased breath sounds, ronchi or crepitations.¹³ Persistent cough or non-resolving pneumonia can be one of the delayed signs.

Foreign body in the airway often associated with high morbidity and mortality. Studies from the Indian population have reported the complication and mortality rates of 10% and 2%, respectively.⁶ Complications more tendency to develop in proportionate to the duration of the foreign body in the tracheobronchial tree.^{6,8} The complication may

include tracheotomy to relieve the upper airway obstruction, or side effects following bronchoscopy or the need for thoracotomy to remove the deep-seated foreign body.¹³ It was reported that in an Asian study, 5.3% in whom bronchoscopy was performed need to undergo thoracotomy¹⁴⁻¹⁵. In our series, one patient required tracheostomy for foreign body removal. No fatality was recorded.

The strength of our study is that we have studied the radiological findings and complications. Multiple studies have reported data regarding foreign body types, but there is limited discussion on radiological findings and complications. The limitations of our study are that it is a retrospective study, small sample size and the complications may be under reported. Long-term follow-up after hospital discharge was not reviewed as well.

Conclusion

Foreign body in lower airway causes considerable morbidity and it should be kept in mind that the outcome can be fatal. It is a frequently missed and misdiagnosed condition. Additional procedure such as tracheostomy or thoracotomy might be required.

Conflict of interest: None declared

Author's contribution:

Data collection: SR, SK, SK

Interpretation of data: SR, VKA, IM

Critical revision and final approval: IM

References:

1. Foltran F, Ballali S, Passali FM, Kern E, Morra B, Passali GC, et al. Foreign bodies in the airways: A meta-analysis of published papers. *Int J Pediatr Otorhinolaryngol* 2012;76Suppl 1:S12-9.
 2. Fidkowski CW, Zheng H, Firth PG. The anesthetic considerations of tracheobronchial foreign bodies in children: A literature review of 12,979 cases. *Anesth Analg* 2010;111:1016-25.
 3. Bertolani MF, Marotti F, Bergamini BM, Pellegrino M, Balli R, Buonaura BLC. Extraction of a Rubber Bullet From a Bronchus After 1 Year. *Chest J* 1999;115(4):1210-13.
 4. Tomos I, Manali ED, Argentos S, Raptakis T, Papiris SA. "Luck is always to blame": Silent wounds of a penetrating gunshot trauma sustained 20 years ago. *Pneumonol Alergol Pol* 2015;392-3.
 5. Gulati SP, Kumar A, Sachdeva A, Arora S. Groundnut as the commonest foreign body of tracheobronchial tree in winter in Northern India. An analysis of fourteen cases. *Indian J Med Sci* 2003;57:244-8.
 6. Kaur K, Sonkhya N, Bapna AS. Foreign bodies in the tracheobronchial tree: A prospective study of fifty cases. *Indian J Otolaryngol Head Neck Surg* 2002;54:30-34.
 7. Divisi D, Di Tommaso S, Garramone M, Di Franciscantonio W, Crisci RM, Costa AM, et al. Foreign bodies aspirated in children: Role of bronchoscopy. *Thorac Cardiovasc Surg* 2007;55:249-52.
 8. Karakoç F, Karadag B, Akbenlioglu C, Ersu R, Yildizeli B, Yüksel M, et al. Foreign body aspiration: What is the outcome? *Pediatr Pulmonol* 2002;34:30-6.
 9. Bittencourt PF, Camargos PA, Scheinmann P, de Blic J. Foreign body aspiration: Clinical, radiological findings and factors associated with its late removal. *Int J Pediatr Otorhinolaryngol* 2006;70:879-84.
 10. Shivakumar AM, Naik AS, Prashanth KB, Shetty KD, Praveen DS. Tracheobronchial foreign bodies. *Indian J Pediatr* 2003;70:793-7.
 11. Vane DW, Pritchard J, Colville CW, West KW, Eigen H, Grosfeld JL. Bronchoscopy for aspirated foreign bodies in children. Experience in 131 cases. *Arch Surg* 1988;123:885-8.
 12. Tan HK, Brown K, McGill T, Kenna MA, Lund DP, Healy GB. Airway foreign bodies (FB): A 10-year review. *Int J Pediatr Otorhinolaryngol* 2000;56:91-9.
 13. Williams A, George C, Atul PS, Sam S, Sukla S. An audit of morbidity and mortality associated with foreign body aspiration in children from a tertiary level hospital in Northern India. *Afr Jour PeadtrSurg* 2014;11:287-292.
 14. Rasid NS, Mohamad I, Md Shukri N. A radiolucent foreign body ingestion as a cause of acute dysphagia. *Bangladesh J Med Sci.* 2018;17(03):515-517. <https://doi.org/10.3329/bjms.v17i3.37012>
 15. Zhang X, Li W, Chen Y. Postoperative adverse respiratory events in preschool patients with inhaled foreign bodies: An analysis of 505 cases. *Paediatr Anaesth* 2011;21:1003-8.
-