

Case Report

Interfollicular Hodgkin's Lymphoma - A Diagnostic Dilemma

Zeeba JS¹, Safia R², Pradeep SC³, Shruti S⁴, Sujala K⁵

Abstract

Interfollicular Hodgkin's lymphoma represents an unusual pattern of focal involvement of interfollicular zones by Hodgkin's lymphoma along with florid reactive follicular hyperplasia. It is often mistakenly diagnosed as a reactive change. We report a case of a 36 years old male with persistent lymphadenitis for three years, who was finally diagnosed as Interfollicular Hodgkin's lymphoma after being incorrectly diagnosed as reactive lymphadenitis. This case is reported in view of the unusual pattern of Hodgkin's lymphoma as well as its misdiagnosis as a benign lesion.

Key words: Interfollicular Hodgkin's lymphoma, Reed Sternberg cells, Follicular Hyperplasia

Introduction:

Interfollicular Hodgkin's lymphoma is a characteristic pattern of lymph node involvement by Hodgkin's lymphoma located between hyperplastic follicles. Morphologically there is a combination of follicular hyperplasia with expansion of interfollicular areas by infiltrates containing Reed Sternberg cells (RS) and its variants alongwith small lymphocytes, plasma cells, eosinophils and macrophages. The biological significance of the histologic pattern of interfollicular Hodgkin's lymphoma is not completely understood. However it is important to recognize this pattern for it may be mistaken for benign reactive conditions with which it shares some histological similarities.¹

Case History:

A male aged 36years, presented with a painless swelling in the left upper cervical region for the past three years. Clinical examination revealed a firm, freely mobile lymphnode measuring 3cm x 2cm. Other similar swellings were found in the posterior triangle of the neck as well as in the inguinal region. None of the swellings showed an increase in size .

The radiological examination comprising of X-ray chest and Computerized tomography (CT) abdomen were within normal limits. However Contrast enhanced CT chest revealed small mediastinal lymph nodes. Fine needle aspiration cytology of the lymphnode was reported as reactive lymphadenopathy. The patient did not respond to treatment and due to persistent lymphadenopathy, an excision biopsy was done. A histopathological diagnosis of Interfollicular Hodgkin's lymphoma was made. Pathological examination grossly showed a well circumscribed homogenous grey white surface of lymph node. Microscopic evaluation revealed numerous reactive follicles with expansion of the interfollicular areas by cellular infiltrate comprising of numerous lymphocytes, plasma cells, eosinophils and histiocytes. Reed Sternberg (RS) cells and its variant are seen interspersed amongst these cells [FigureI]. Vascularity was also prominent in these areas. Immunohistochemistry revealed positivity for CD30 in these RS cells [Figure II] and CD3 and CD20 positivity pattern was also seen as in [Figure III].

1. Jairajpuri S Zeeba. Hamdard Institute of Medical Sciences & Research
2. Rana Safia, Hamdard Institute of Medical Sciences & Research. Jamia Hamdard, New Delhi, 11062, India
3. Pradeep S Chauhan. Institute of Pathology (Indian Council of Medical Research)
4. Sharma Shruti. Institute of Pathology (Indian Council of Medical Research)
5. Kapur Sujala. Institute of Pathology (Indian Council of Medical Research), Safdarjung Hospital Campus, New Delhi, 110029, India.

Corresponds to: Sujala Kapur, M.D. Deputy Director, Institute of Pathology (ICMR), Safdarjung Hospital Campus, New Delhi, 110029. India. **Email: sujalakapur@gmail.com**

Interfollicular Hodgkin's Lymphoma - A Diagnostic Dilemma

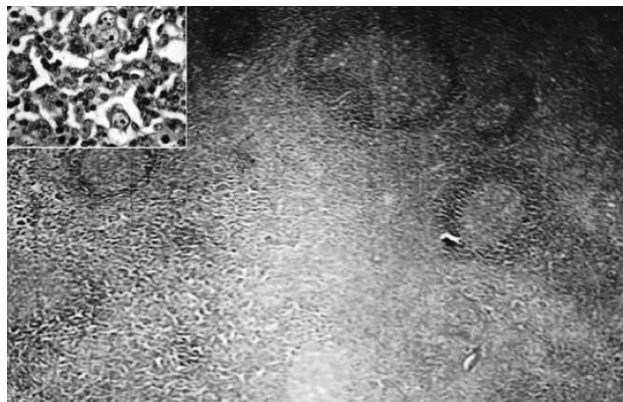


Figure I: Photomicrograph of lymph node biopsy showing reactive follicles with expanded interfollicular area. Inset shows RS cells. [H&E, X50]

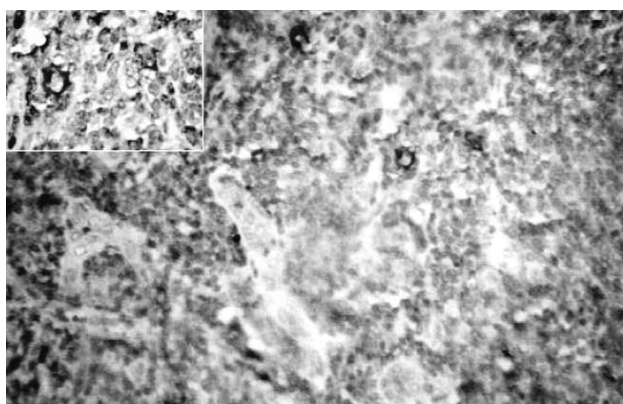


Figure II; Photomicrograph showing Reed Sternberg cells staining positive for CD30 [IHC, X100]. Inset shows RS cell.

Discussion:

Interfollicular Hodgkin's lymphoma represents a peculiar pattern of focal involvement of the lymph node by Reed Sternberg cells and its variants rather than a subtype of Hodgkin's lymphoma.² Dogget et al was the first to specifically report this pattern in literature.³ It has been well documented that the earliest areas of lymph node involvement by Hodgkin's lymphoma are the interfollicular regions, immediately adjacent to the follicles.^{2, 4} Moreover Reed Sternberg cells elaborate a variety of cytokines and growth factors especially interleukin-6 which could be responsible for follicular hyperplasia.⁵ According to Basu et al emphasis has to be laid on the fact that the interfollicular pattern may be mistaken for reactive and benign conditions as well as other forms of lymphoma.⁶

An orderly progression of Hodgkin's lymphoma to contiguous lymph nodes and lymph node groups has been postulated.⁷ Moreover the observation that in a given lymph node group some lymph nodes do and

others do not contain evidence of Hodgkin's lymphoma is in keeping with this concept.⁸ At times such focal involvement is associated with pronounced reactive hyperplasia and such lesions can be readily overlooked.² The discovery of focal involvement is of great importance in the diagnosis and staging of Hodgkin's lymphoma. Without the prior knowledge of this fact a focus of Hodgkin's lymphoma may escape detection in a lymph node removed for diagnosis, hence treatment may be appreciably delayed.²

A variant of lymphadenitis mimicking interfollicular Hodgkin's lymphoma, characterized morphologically by changes in the interfollicular region within a



Figure III: Photomicrograph showing normal T cell and B cell staining positive with CD3 & CD20 respectively. [IHC, X100]

well preserved lymph node architecture has been reported by Felbaum et al.⁹ These changes included perifollicular loose clusters of epithelioid cells intermingled with eosinophilic granulocytes and immunoblasts occasionally resembling Hodgkin's cells. Since this is also a feature of the early interfollicular infiltration of Hodgkin's lymphoma it comprises its chief differential diagnosis.

Castleman's disease initially recognized as an unusual pattern of reactive hyperplasia in lymph nodes may have many morphological similarities to Interfollicular Hodgkin's lymphoma. Distinction between the two is possible with a careful search for diagnostic RS cells in the interfollicular areas along with relevant immunohistochemical studies. Plasma cell variant of Castleman's disease has been of particular concern and a review of cases has demonstrated scattered RS cells in the interfollicular area highlighted by CD15 and CD30 leading to a revised diagnosis of Interfollicular Hodgkin's lymphoma.¹⁰ In the recent past, increasing awareness of similari-

ties between pleomorphic T-cell lymphomas and Hodgkin's lymphoma have emerged. Cytological features almost identical to RS cells and a polymorphous cell population were noted. However in most cases of differential diagnostic difficulty, consideration of histomorphological and ancillary studies findings allows assignment of either Hodgkins or Non Hodgkin's lymphoma.¹¹

The relevance of Fine needle aspiration cytology in diagnosing Interfollicular Hodgkin's lymphoma is debatable, it has often failed to detect the lesion probably due to a sampling error as large areas of

lymph nodes showed follicular hyperplasia, hence resulting in a delay in diagnosis and management.⁶ The numbers of cases of Interfollicular Hodgkin's lymphoma reported are few in literature and no relevant prognostic significance has been attached to this pattern.^[3] Most authors consider it a variant of mixed cellularity Hodgkin's disease. Although, recognition of Interfollicular Hodgkin's lymphoma is difficult, increasing awareness and a careful examination of the expanded interfollicular areas for RS cells often clinches the diagnosis. Ancillary support of Immunohistochemical staining for CD15 and CD30 marker is beneficial.

References:

1. Wilson CS, Chang KL, Wiess LM. Malignant lymphomas that mimic benign lymphoid lesions: A review of four lymphomas. *Semin Diag Pathol* 1995;**12**(1):77-86.
2. Strum SB, Rapport H. Significance of focal involvement of lymph nodes for the diagnosis and staging of Hodgkin's disease. *Cancer* 1970;**25**:1314-19.
3. Dogget R, Colby TV, Dorfman RF. Interfollicular Hodgkin's disease. *Am J Surg Pathol* 1983;**7**:145-49.
4. Lukes RJ. Criteria for involvement of lymph nodes, bone marrow, spleen and liver in Hodgkin's disease. *Cancer Res* 1971;**31**:1755-67.
5. Poppema S, Potters M, Emens R, Visser L, van Berg A. Immune reactions in classical Hodgkin's lymphoma. *Semin Haematol* 1999;**36**:253-59.
6. Basu D, Roy S. Interfollicular Hodgkin's disease: an uncommon pattern that may cause diagnostic difficulty. *Indian J Pathol Microbiol* 2006;**49**(2):221-25.
7. Rosenberg SA, Kaplan HS. Evidence for an orderly progression in the spread of Hodgkins disease. *Cancer Res* 1966;**26**:1225-30.
8. Slaughter DS, Economou SG, Southwick HW. Surgical management of Hodgkin's disease. *Ann. Surg* 1958;**148**:705-10.
9. Fellbaum CH, Hansmann ML, Lennert K. Lymphadenitis mimicking Hodgkin's disease. *Histopathology* 1988;**12**:253- 62.
10. Zarate-Osorno A, Medeiros LJ, Danon AD, Netman RS Hodgkin's disease with coexistent Castleman-like Histologic Feature. A report of three cases. *Arch Pathol LabMed* 1994;**118**:270-4.
11. Banks PM. The distinction of Hodgkin's disease from T-cell lymphoma. *Semin Diagn Pathol* 1992;**9**:273-83.