

## CLINICAL IMAGE

### CLINICAL IMAGE-2

AMINUR RAHMAN

**Keywords:** Magnetic resonance imaging, Arachnoid cysts

Date of submission: 15.12.2025

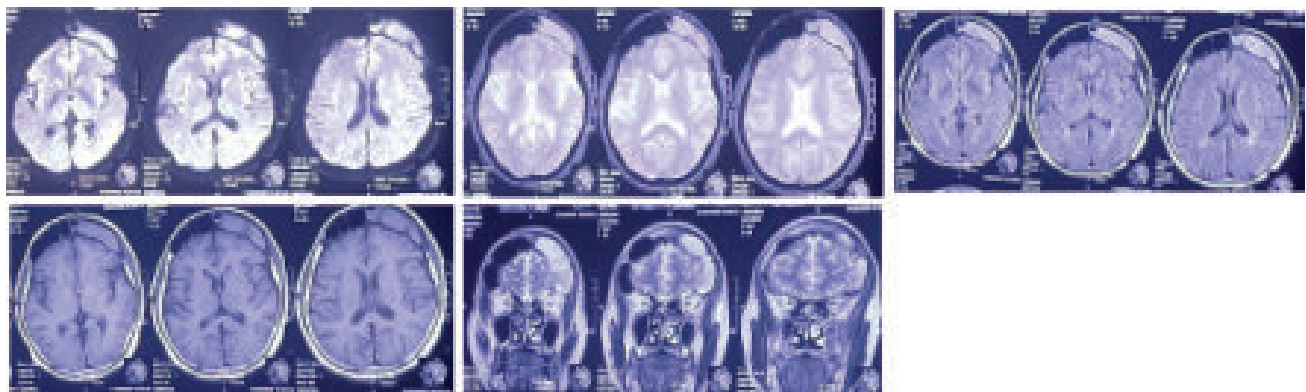
Date of acceptance: 22.12.2025

DOI: <https://doi.org/10.3329/bjm.v37i1.86904>

**Citation:** Rahman M. Clinical Image-2. Bangladesh J Medicine 2026; 37(1): 81.

A 34-year-old right-handed male was taken to the emergency department with a widespread tonic-clonic epileptic seizure and post-seizure loss of

consciousness. Magnetic resonance imaging of the patient had been performed.



**Figure1:** MRI of brain (Courtesy: Dr. Gurudas Mondol)

#### Answers the following questions.

1. What are the findings of MRI of brain?
2. Mention five differentials of the MRI.
3. What is most likely diagnosis?
4. What are the other imaging protocol to reach the diagnosis?.
5. Mention the treatment of the disease.

**Address of Correspondence:** Prof. Aminur Rahman, Professor, Dept of Neurology, Sir Salimullah Medical College, Mitford, Dhaka, Bangladesh. Email: [draminur@yahoo.com](mailto:draminur@yahoo.com), <https://orcid.org/0000-0001-9261-7734>.

**Copyright:** @ 2026 Associations of Physicians of Bangladesh