

## CLINICAL IMAGE

### CLINICAL IMAGE-1

REFAYA TASNIM<sup>1</sup>, QUAZI TARIKUL ISLAM<sup>2</sup>

Date of submission: 22.08.2025

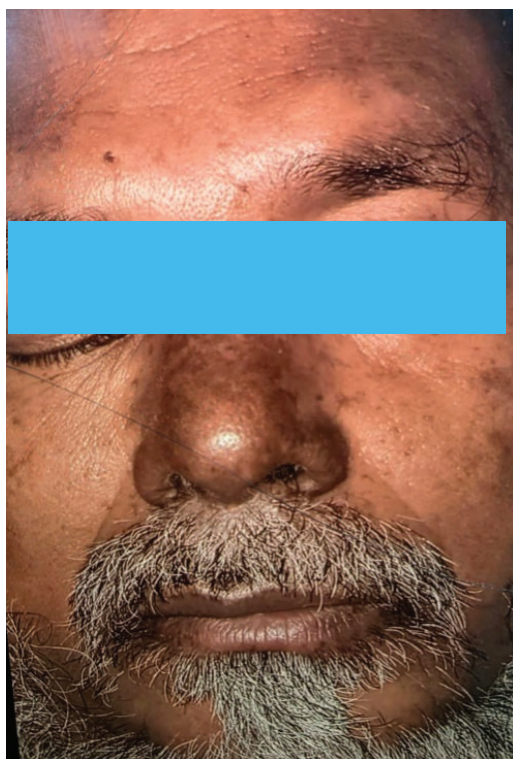Date of acceptance: 25.08.2025

DOI: <https://doi.org/10.3329/bjm.v36i3.84070>.

**Citation:** Tasnim R, Islam QT. Clinical Image-1. Bangladesh J Medicine 2025; 36(3): 164.

A 61-year-old hypertensive, non-diabetic male presented with a history of fever for 4days, rash and arthralgia of small joints of hands, wrists and both ankles for the last 13 days.

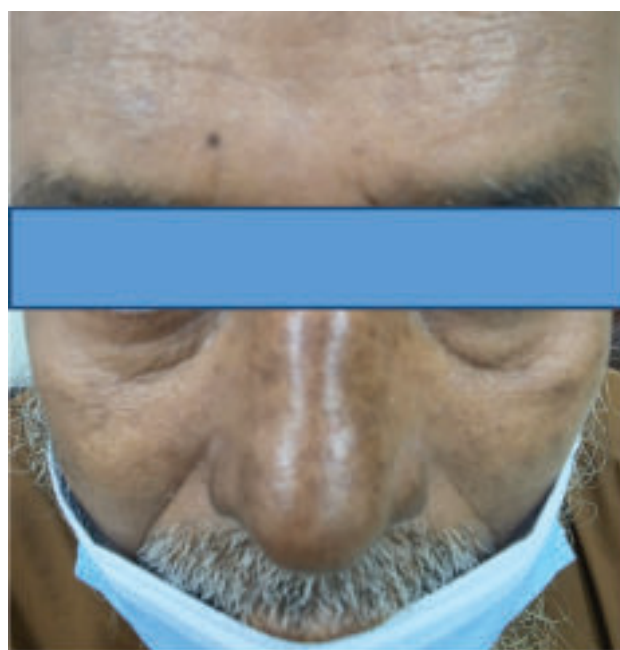
On examination, he was afebrile, tender and swollen PIP, MCP, wrists and both ankles. He also had a hyperpigmented rash over his nose (Figure-01), which he noticed to develop during this course of illness.



**Fig.-1:**

His full blood count showed, leucopenia.

Follow-up visit after 3 weeks, showed improvement of the hyperpigmentation over his nose (Figure-02).



**Fig.-2:**

**Question 01:** Describe the lesion of Figure-01 and Figure-02.

**Question 02:** Name the lesion.

**Question 03:** What is the clinical diagnosis?

**Question 04:** What is the mechanism of this condition?

**Question 05:** Enumerate the treatment options for this condition?

1. Research Assistant of CHIKV Study group 2025, Dhaka, Bangladesh.

2. Professor of Medicine, Popular Medical College, Dhaka, Bangladesh.

**Address of Correspondence:** Prof. Quazi Tarikul Islam, Professor of Medicine, Popular Medical College, Dhaka Bangladesh, Email: [prof.tarik@gmail.com](mailto:prof.tarik@gmail.com)